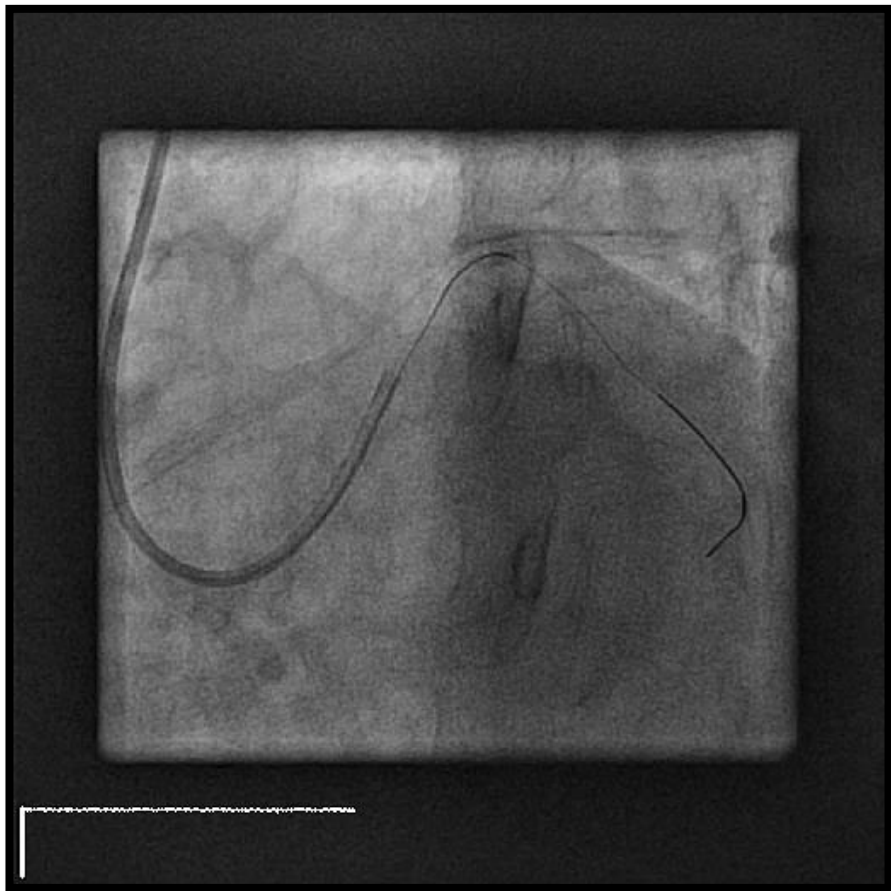
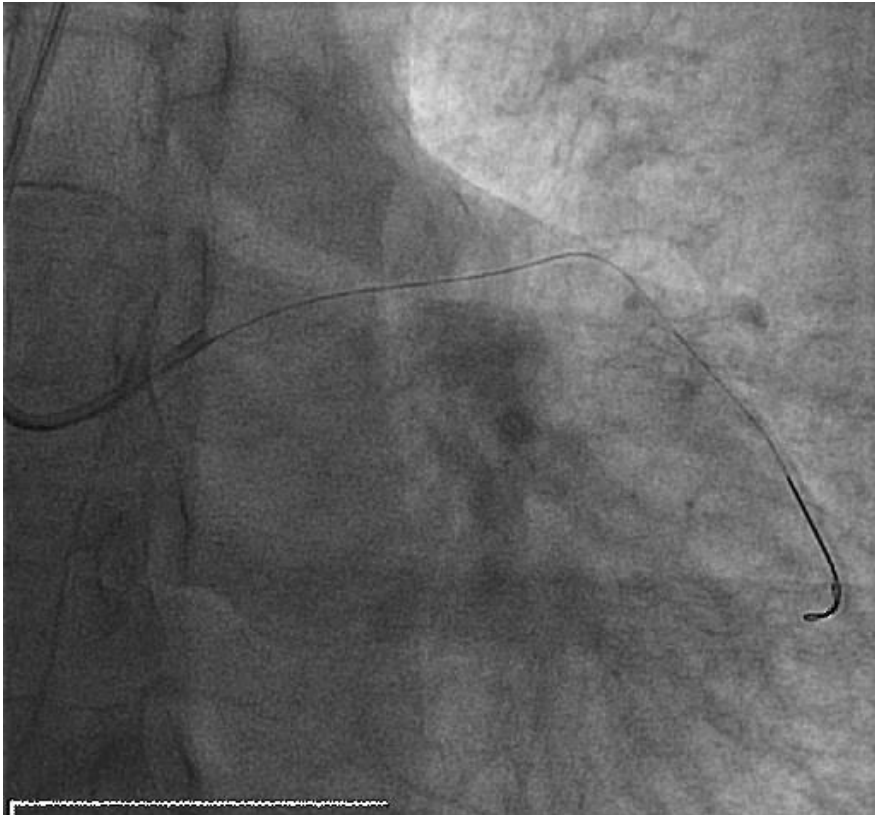
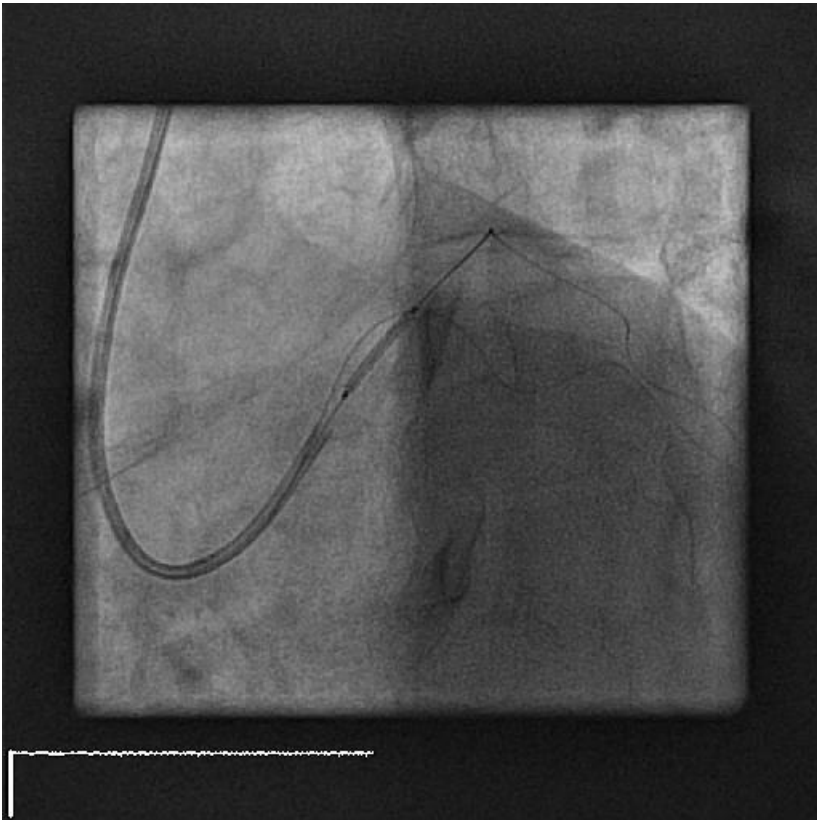
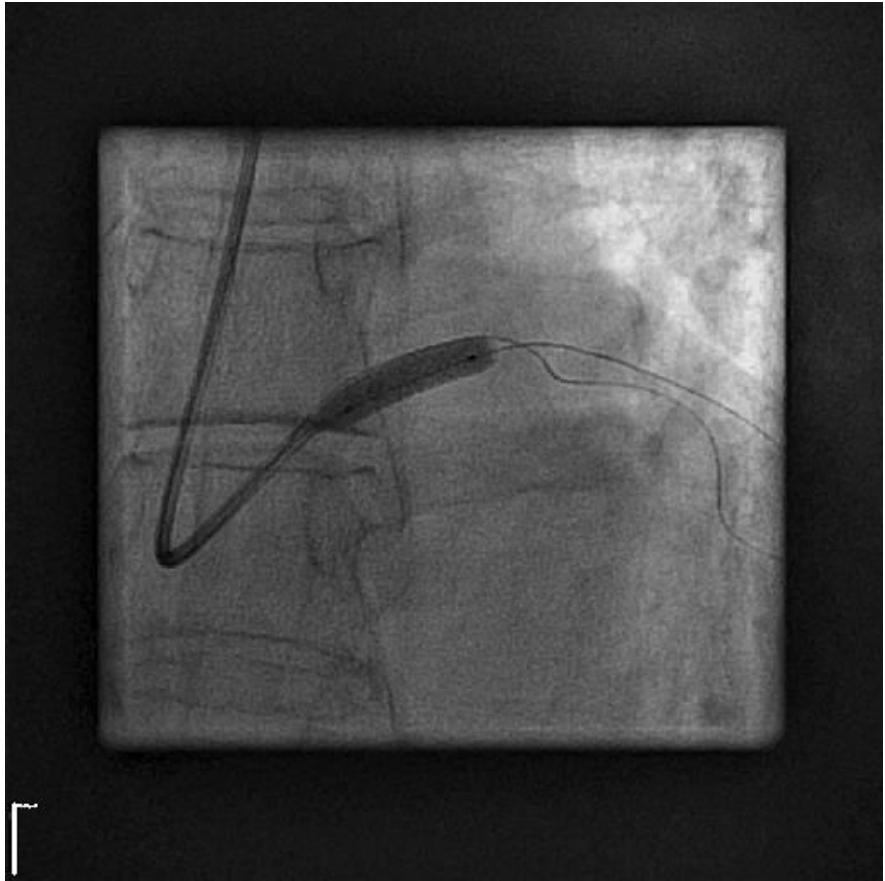

Case treatment

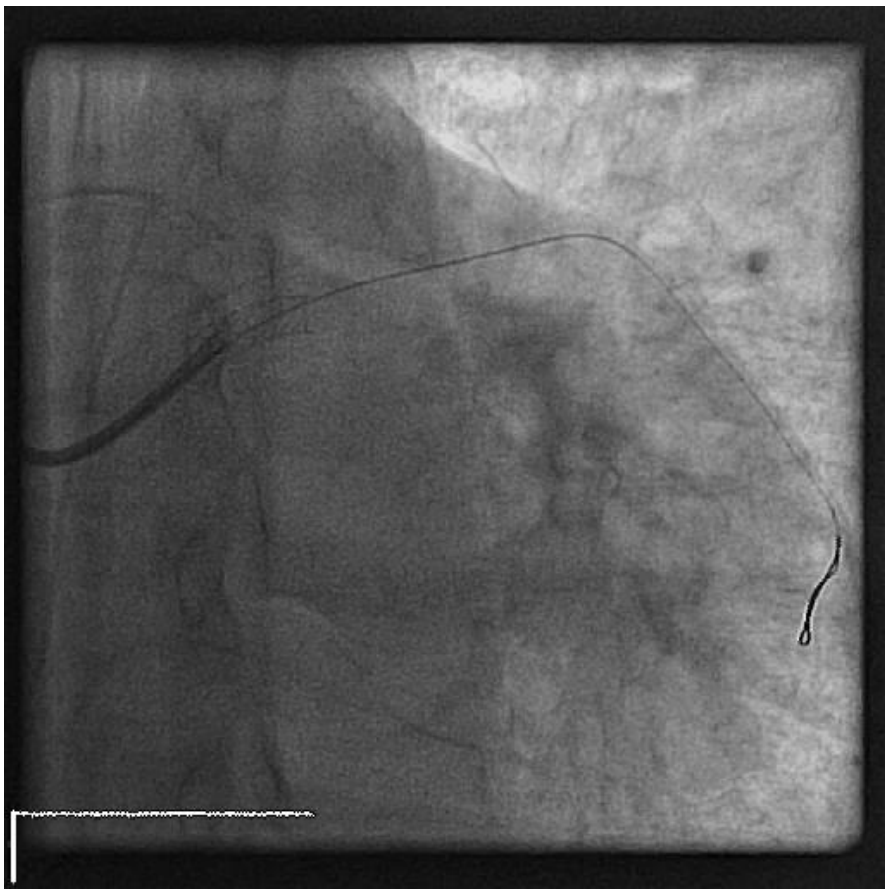


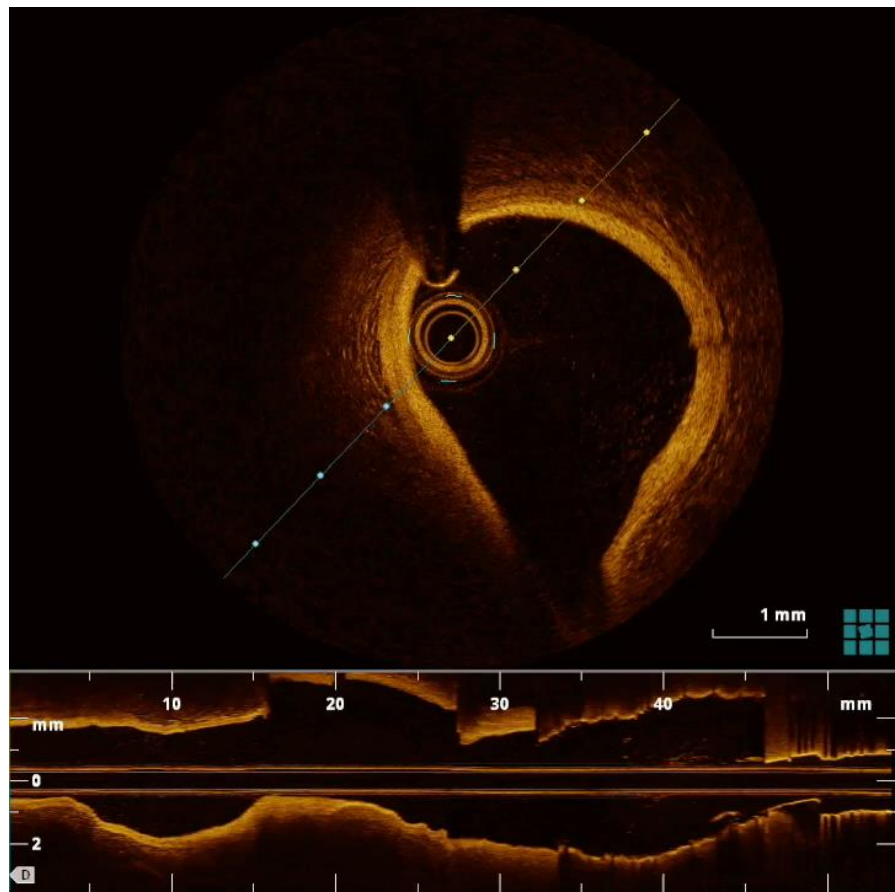


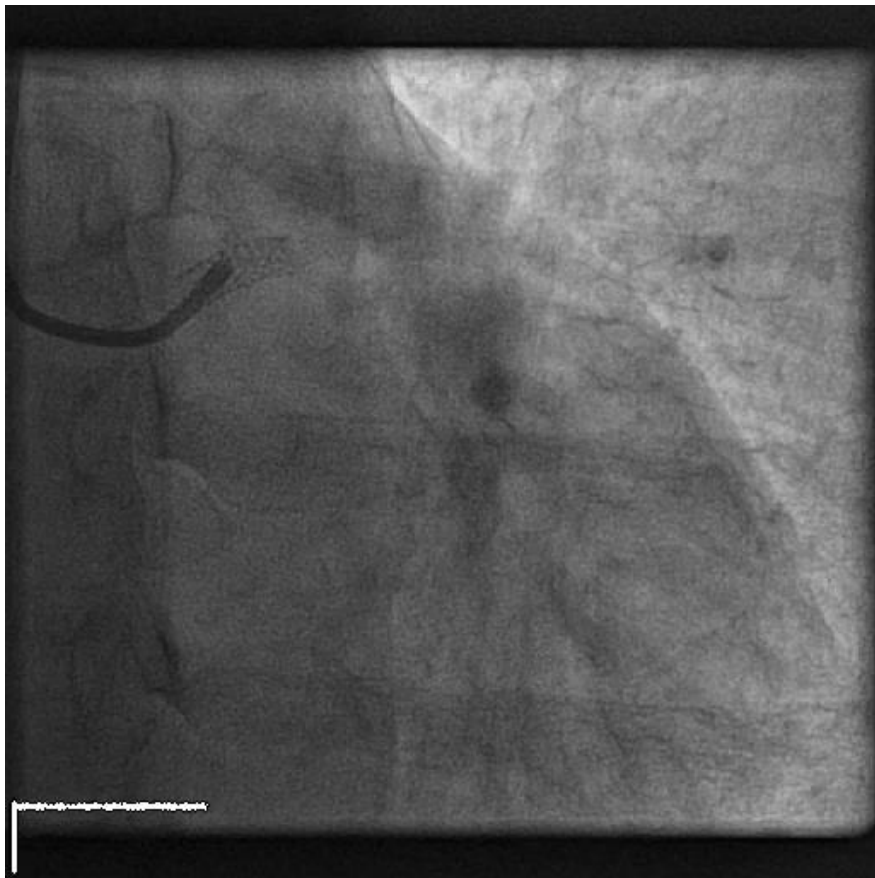




Papyrus 4,5x15mm







FU angio - 1 year

Questions?

Discussion

- No manifest CAD
- Initial presentation SCAD / spasm
- Pseudoaneurysm is catheter-induced
- Patient was informed and aware of the risk of ISR (and subsequent CABG)

Complications

- Distale embolisatie
- Infectie
- Necrose
- Ruptuur