

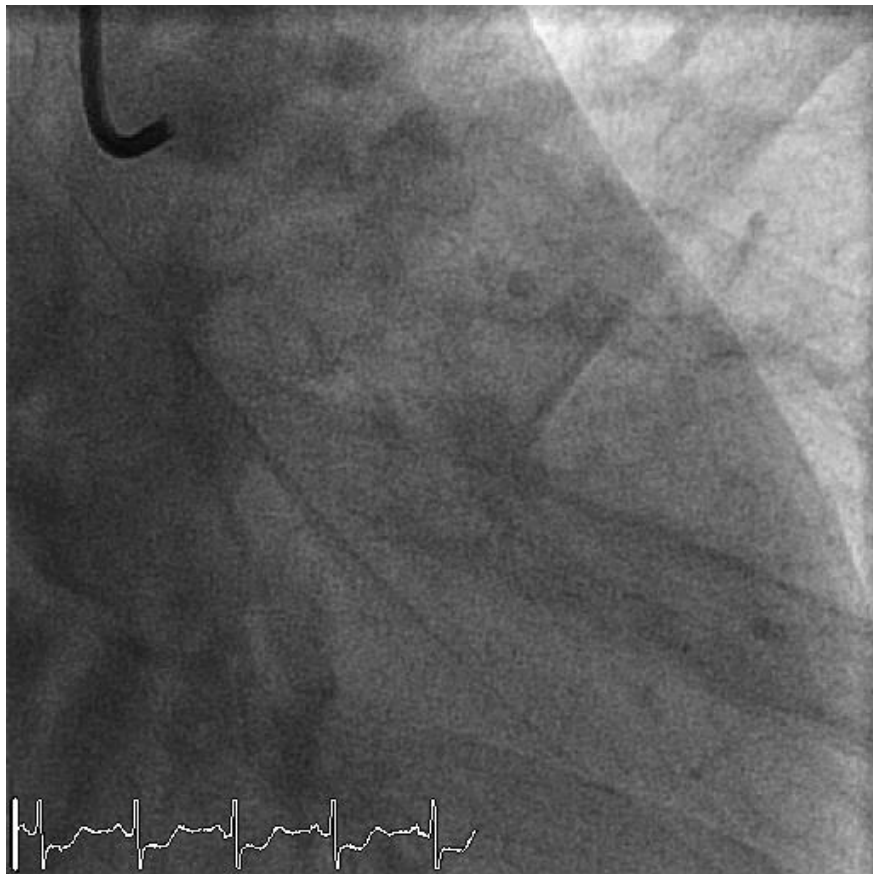
A pseudo-aneurysm of the left main

D. F. van Wijk, MD. PhD.
OLVG, Amsterdam
The Netherlands

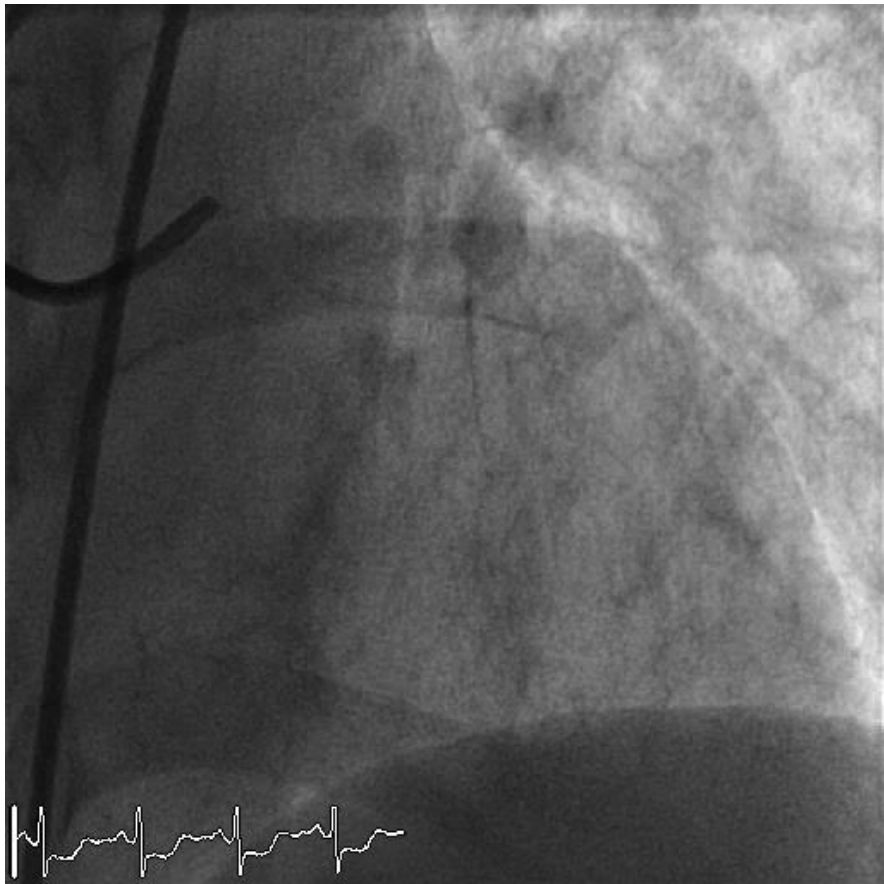
Speaker's name : Diederik F. van Wijk

I do not have any potential conflict of interest to declare

A 51 y/o women with AS AMI

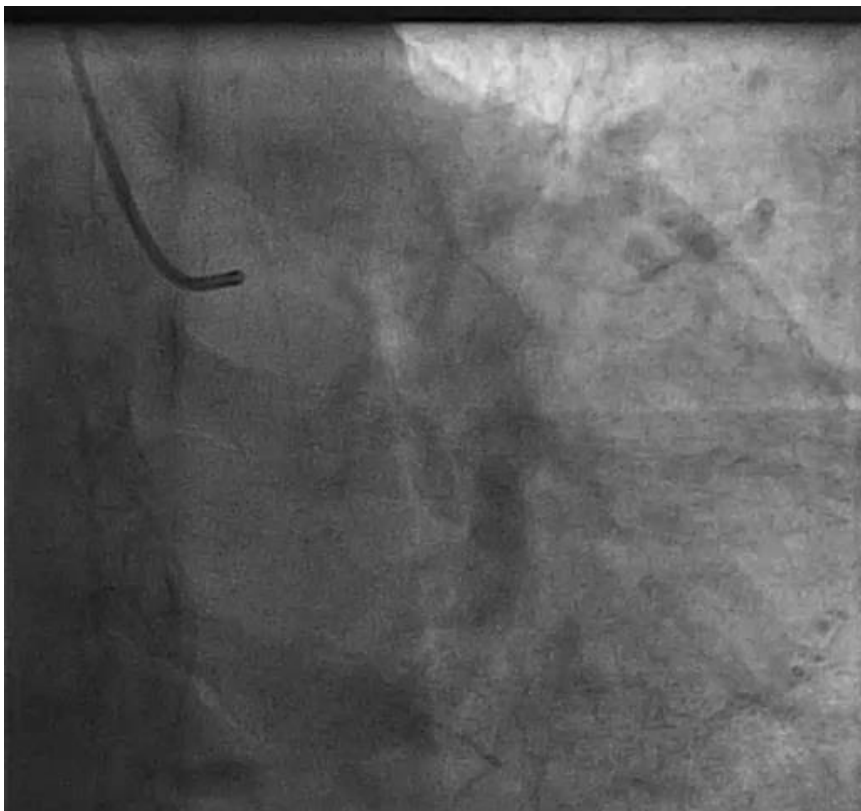


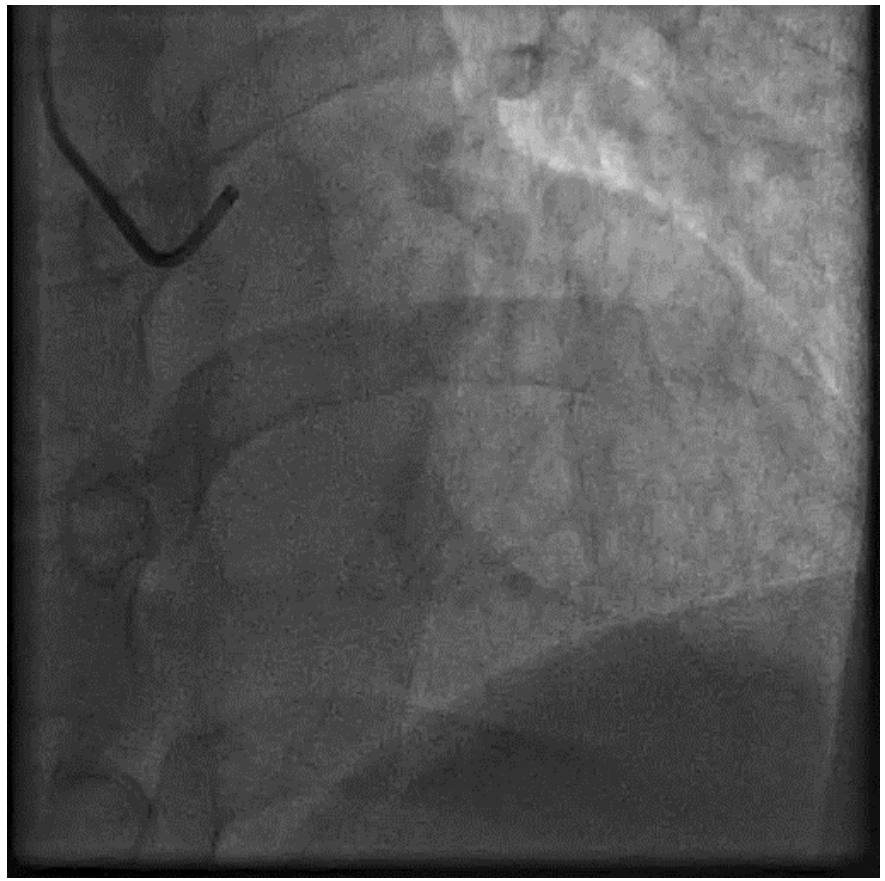
A 51 y/o women with AS AMI

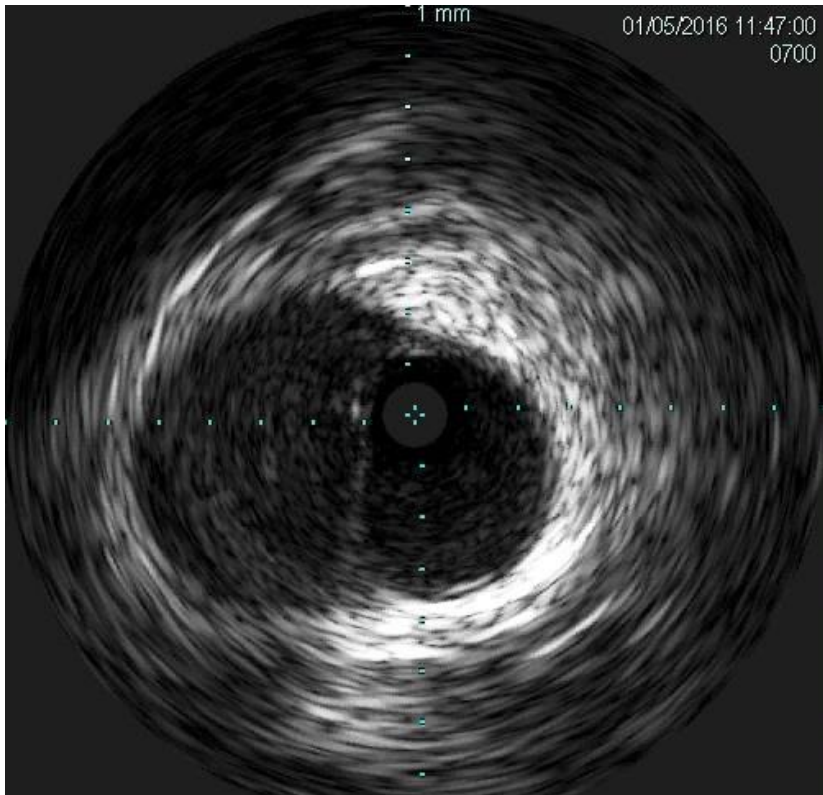


A 51 y/o women with AS AMI

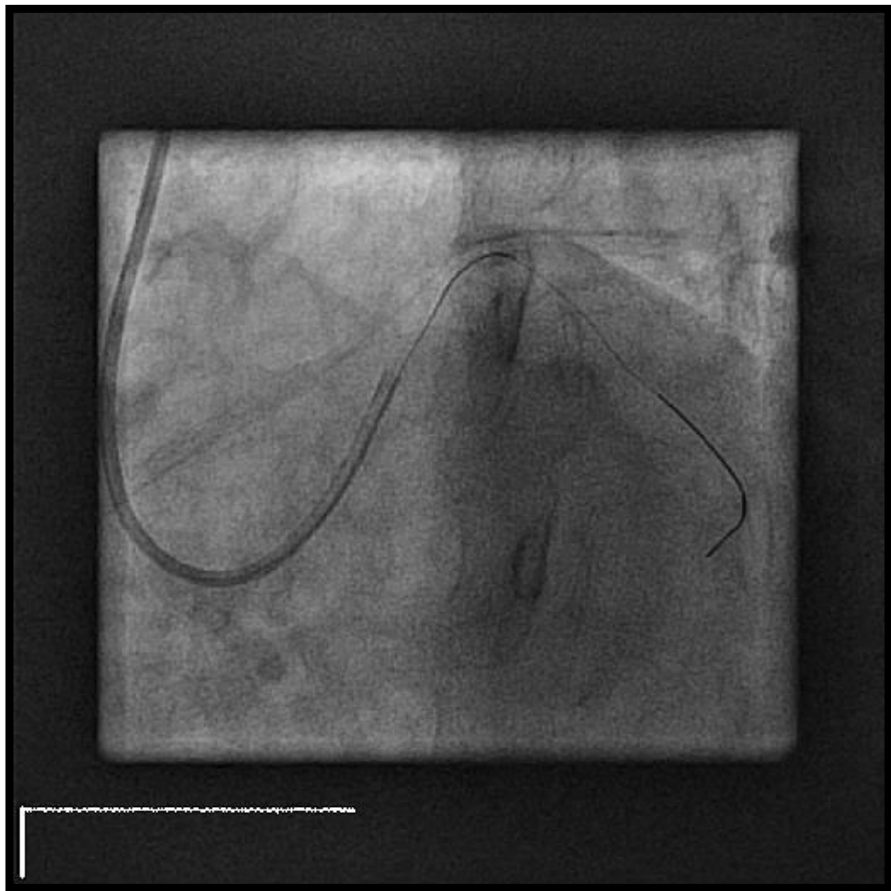
- PCI of septal branche unsuccessful
- (Subtotal) occlusion distal RCx
- F/U complaining of shortness of breath
- Positive exercise test
- Referred for PCI RCx

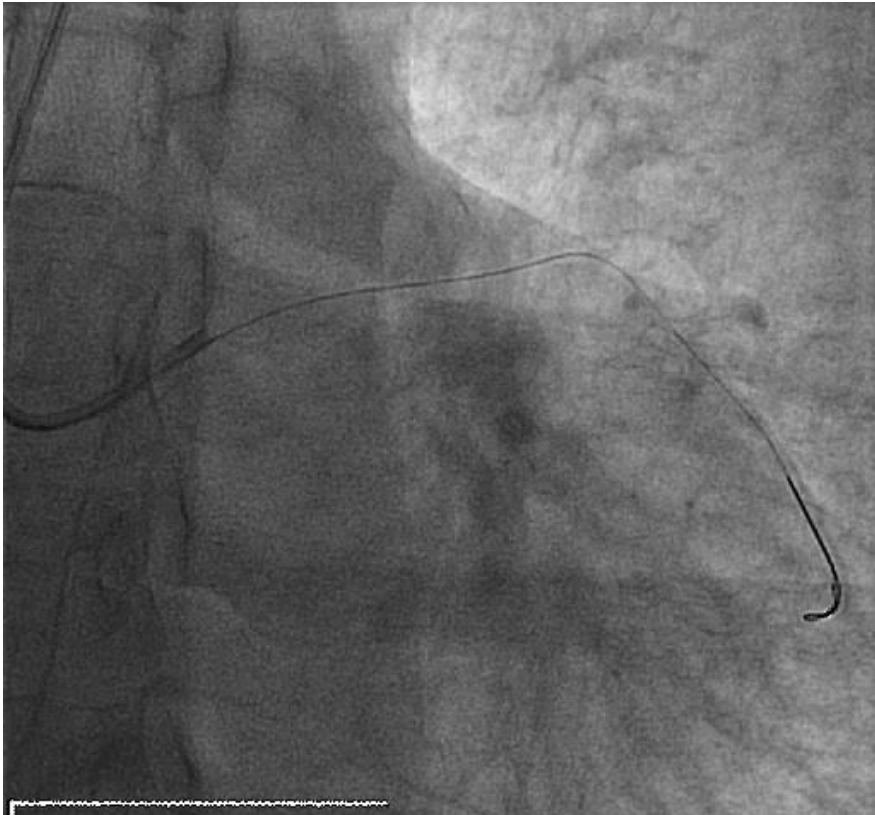


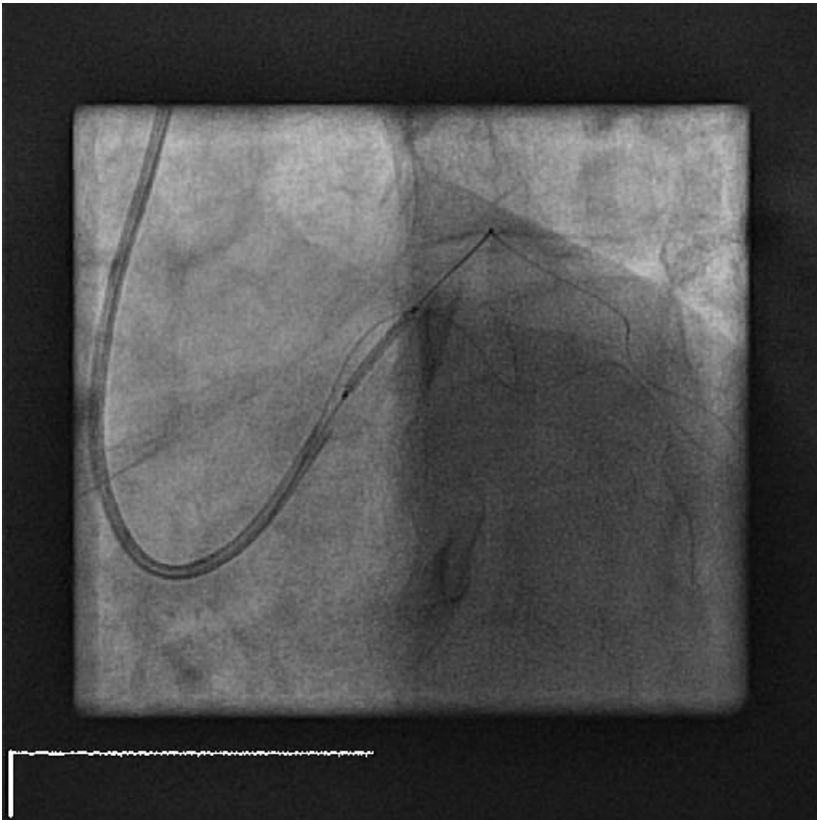


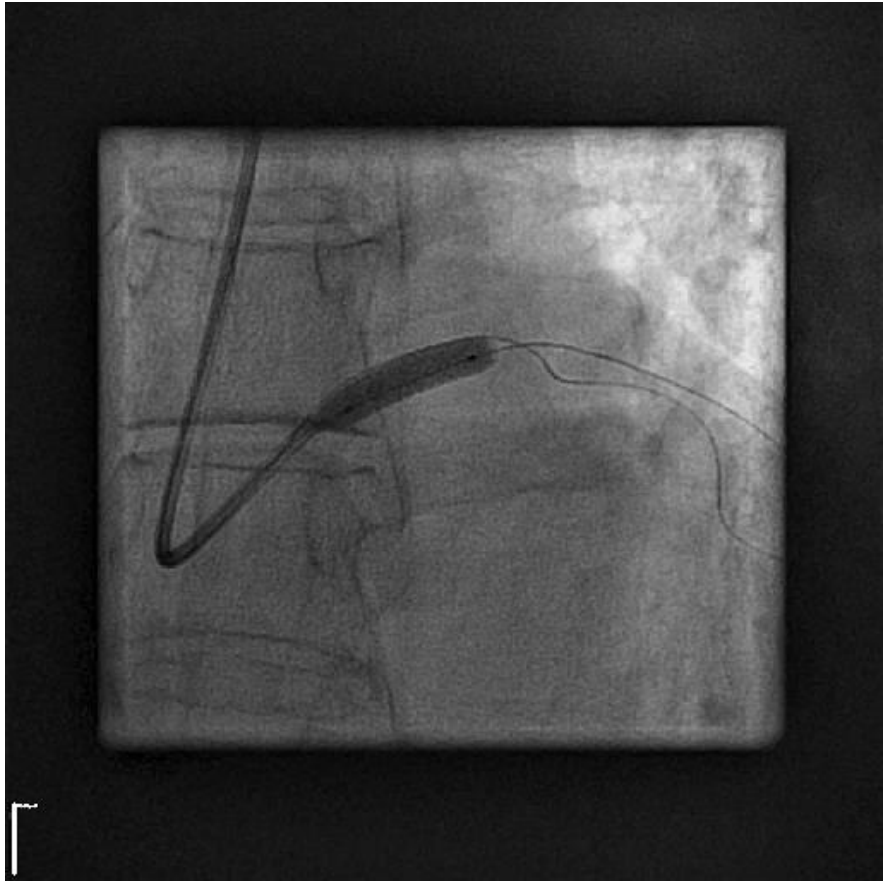

Case treatment

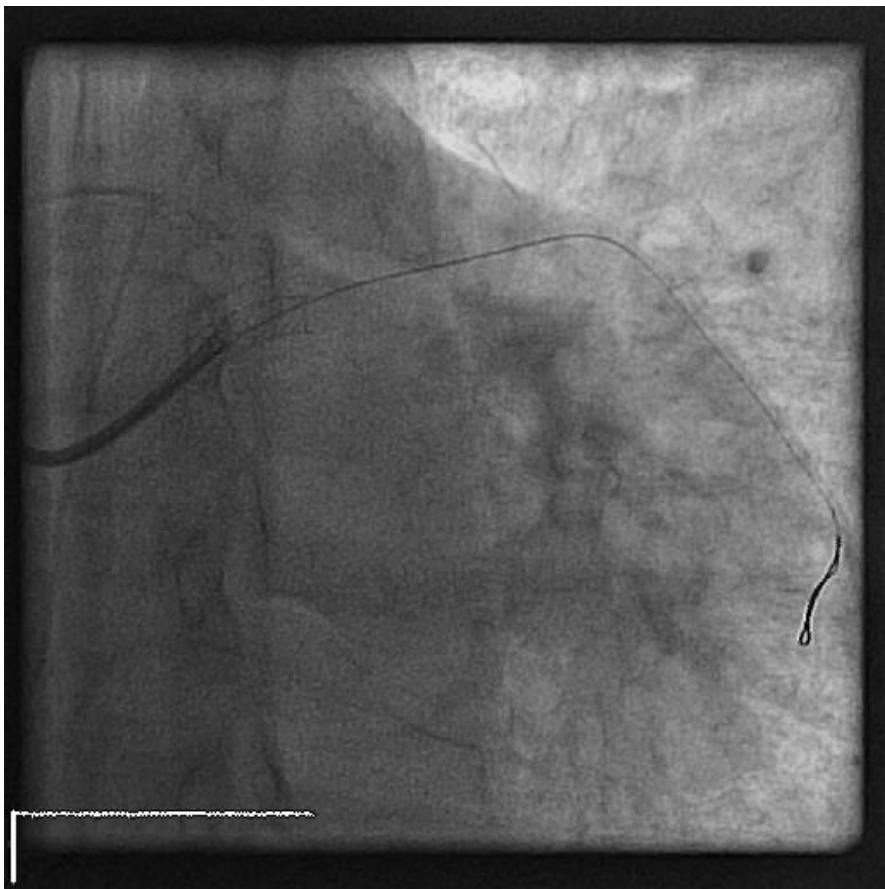


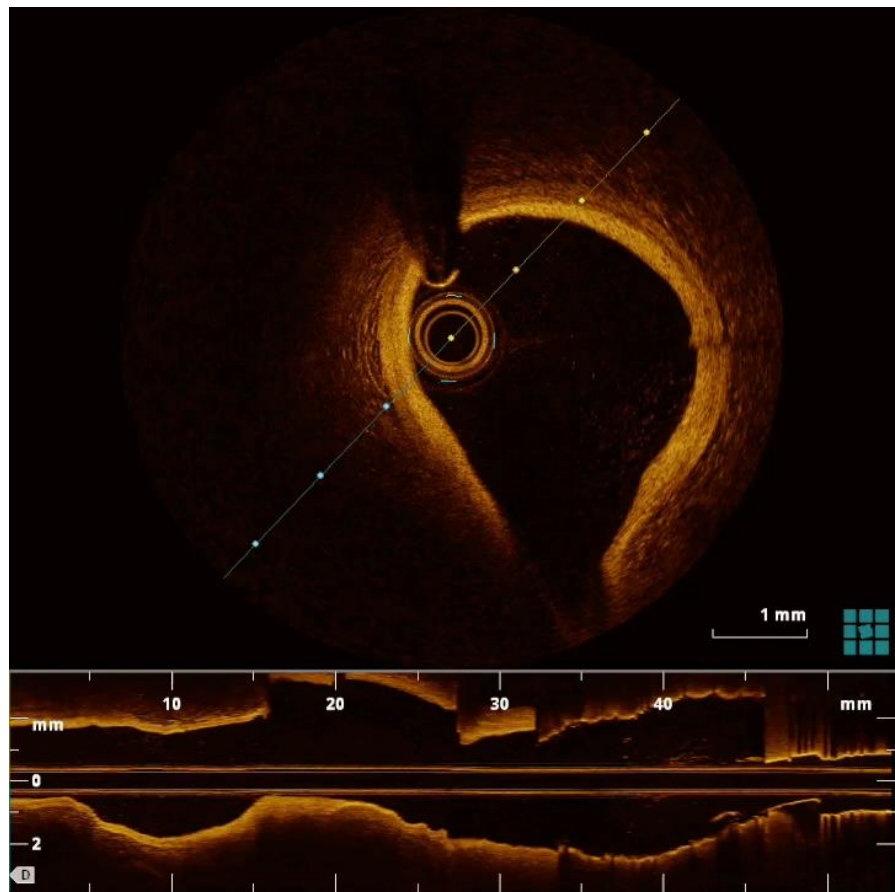


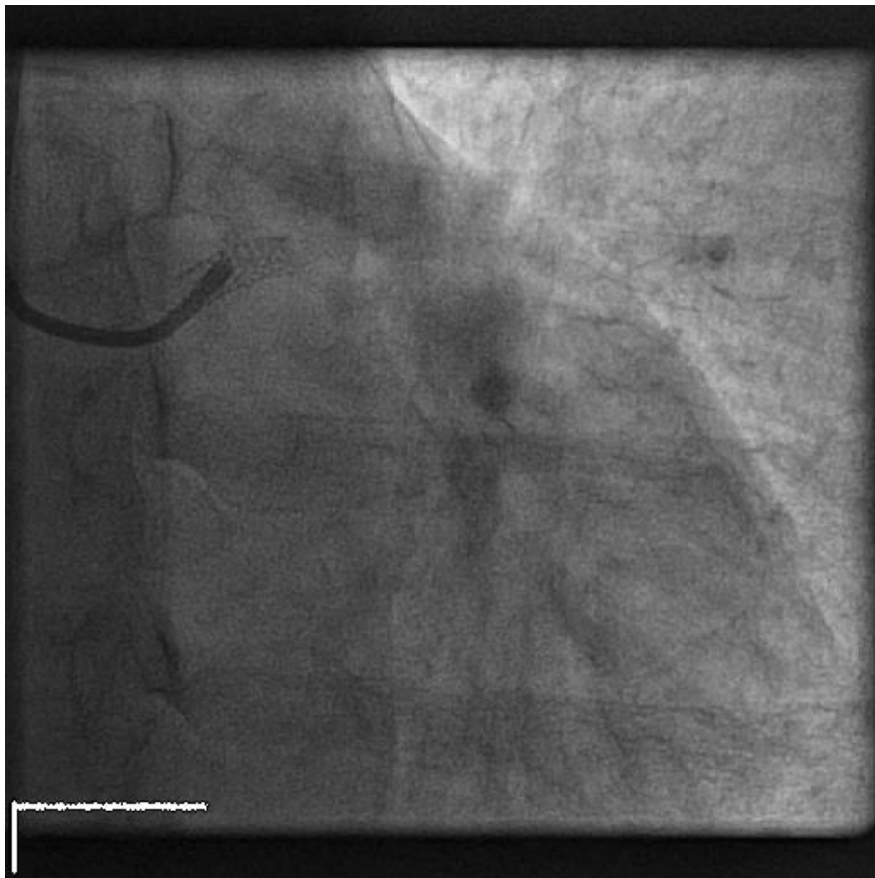




Papyrus 4,5x15mm







FU angio - 1 year

Questions?

Discussion

- No manifest CAD
- Initial presentation SCAD / spasm
- Pseudoaneurysm is catheter-induced
- Patient was informed and aware of the risk of ISR (and subsequent CABG)

Complications

- Distale embolisatie
- Infectie
- Necrose
- Ruptuur

Treatment possibilities

- Surgical bypass grafting
- Surgical bypass grafting with surgical closure of the ostium of the left main.
- DES stenting
- Covered stent