



# *COMO TRATAMOS EL TRONCO CORONARIO IZQUIERDO HOY*

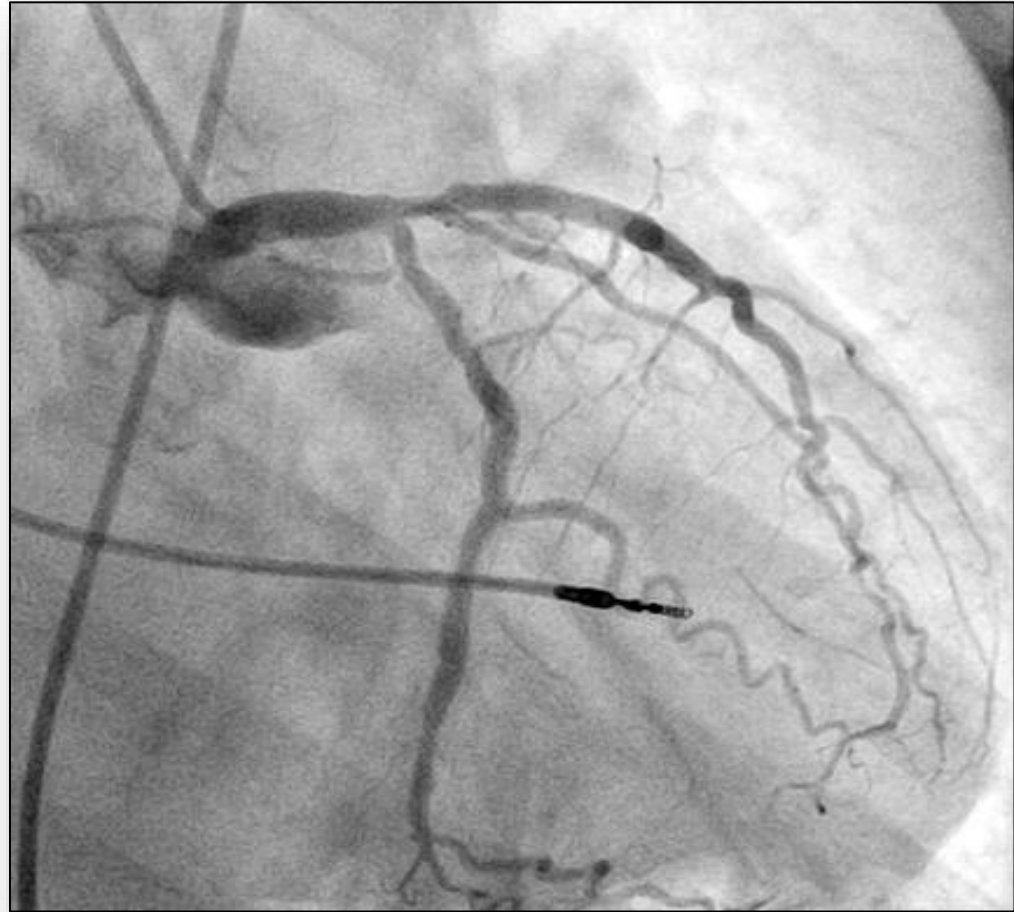
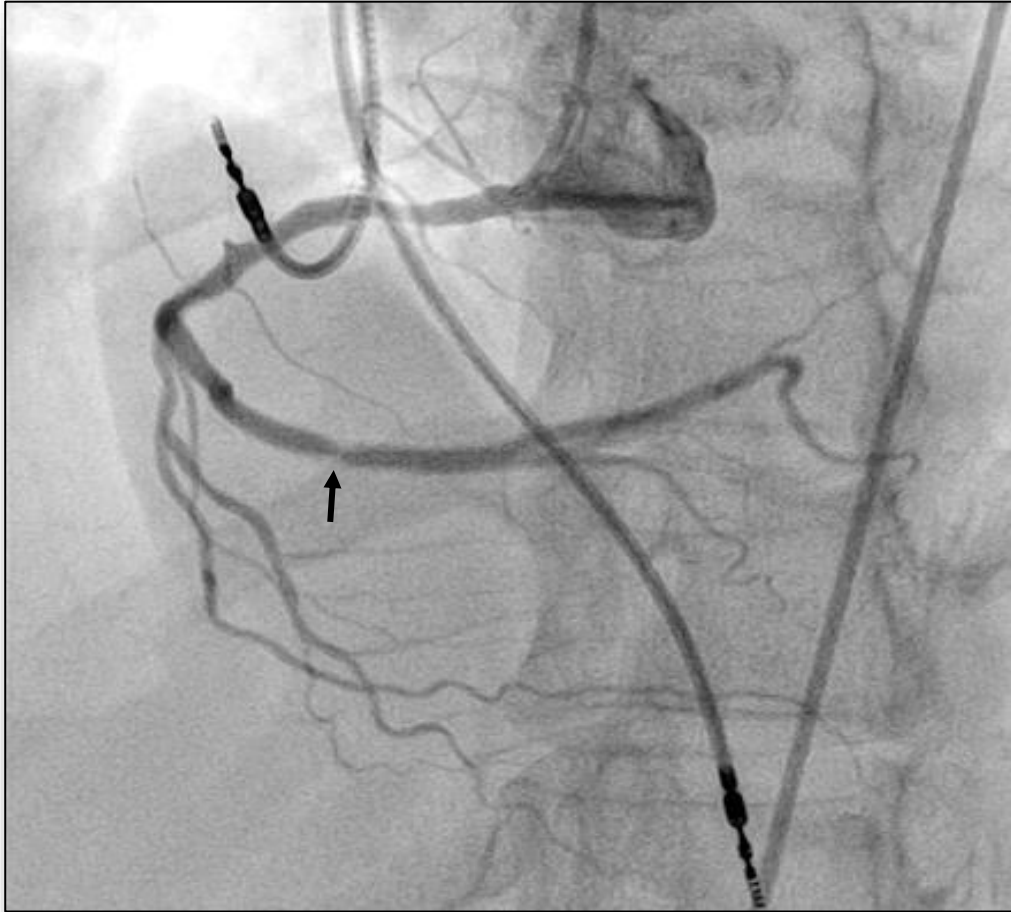
*DR. JORGE H. LEGUIZAMÓN*

*Artery Group*  
Unidad Interdisciplinaria de Terapéutica Endovascular



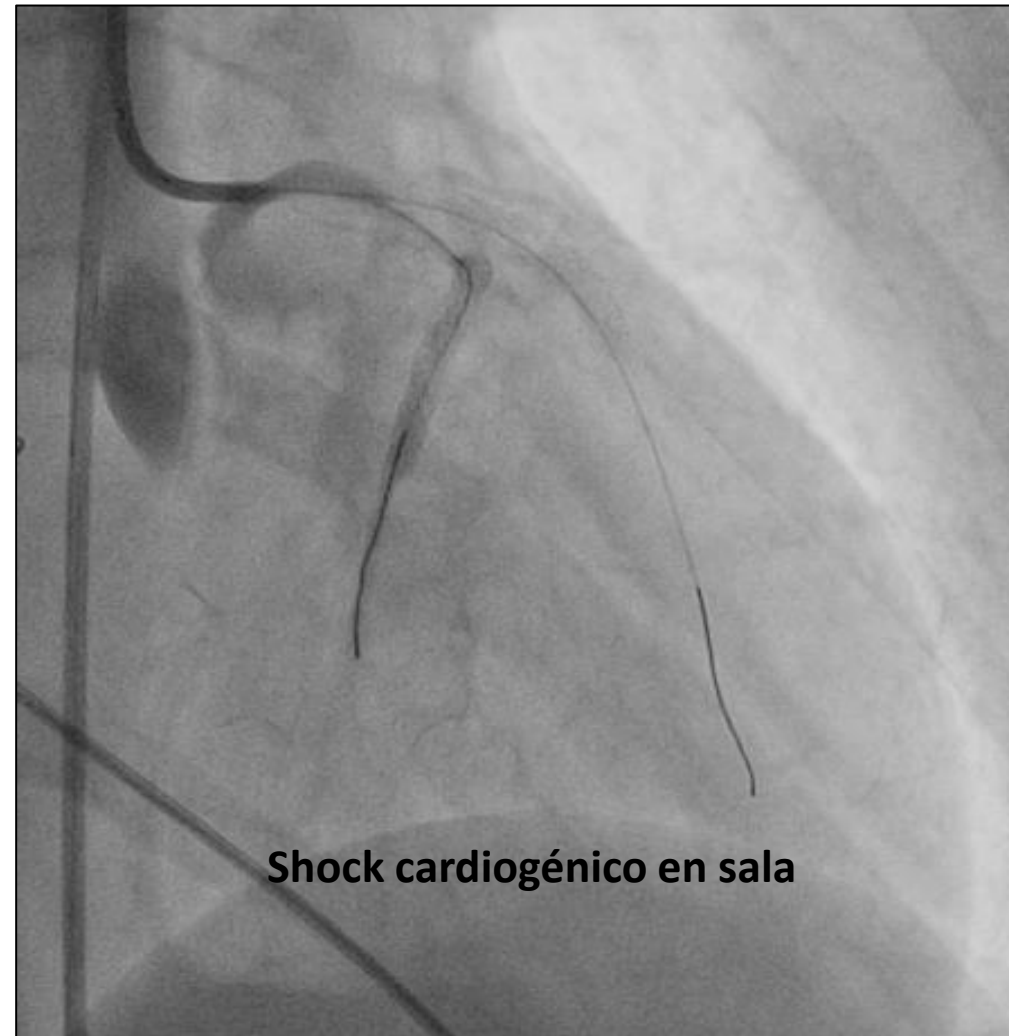
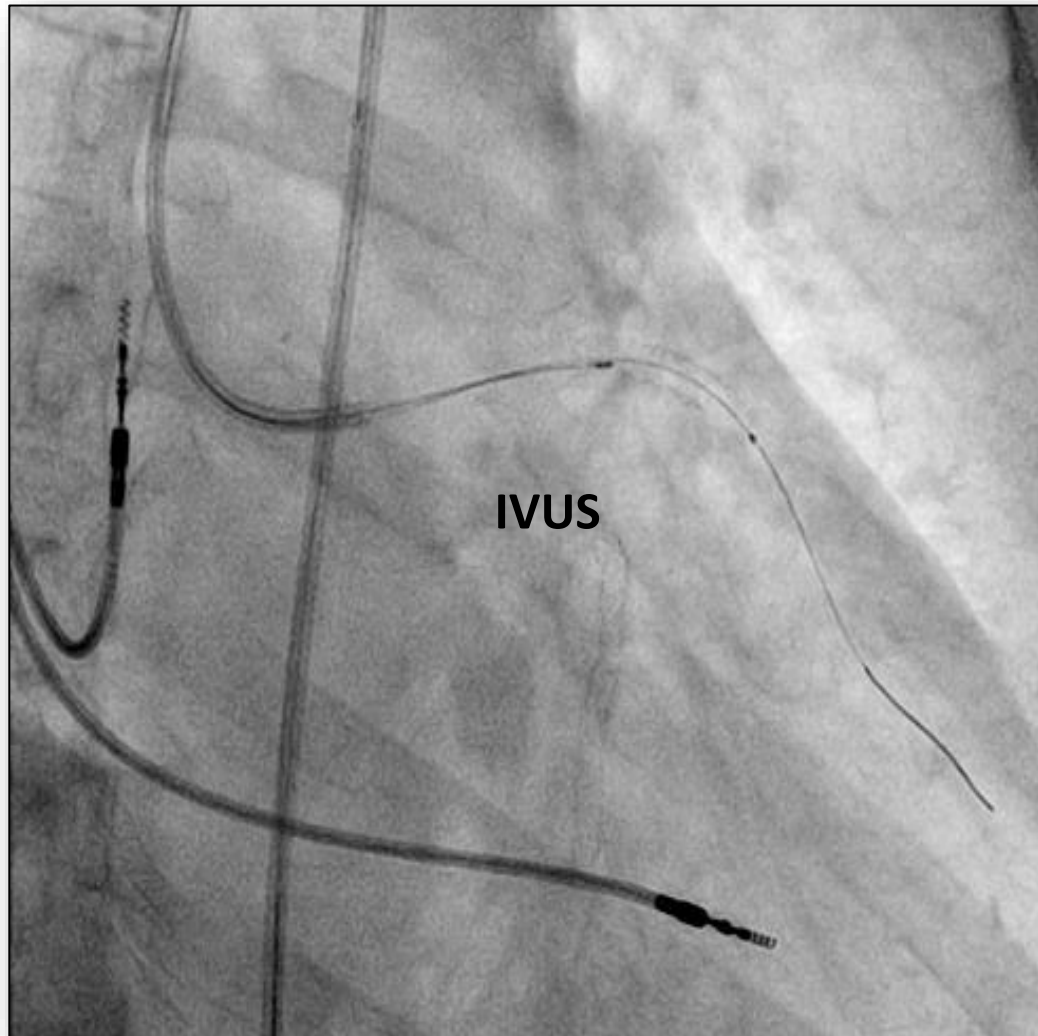
# SHOCK CARDIOGÉNICO EN SALA Técnica Indicada Ocasionalmente

Mujer 49 años con Angina Inestable



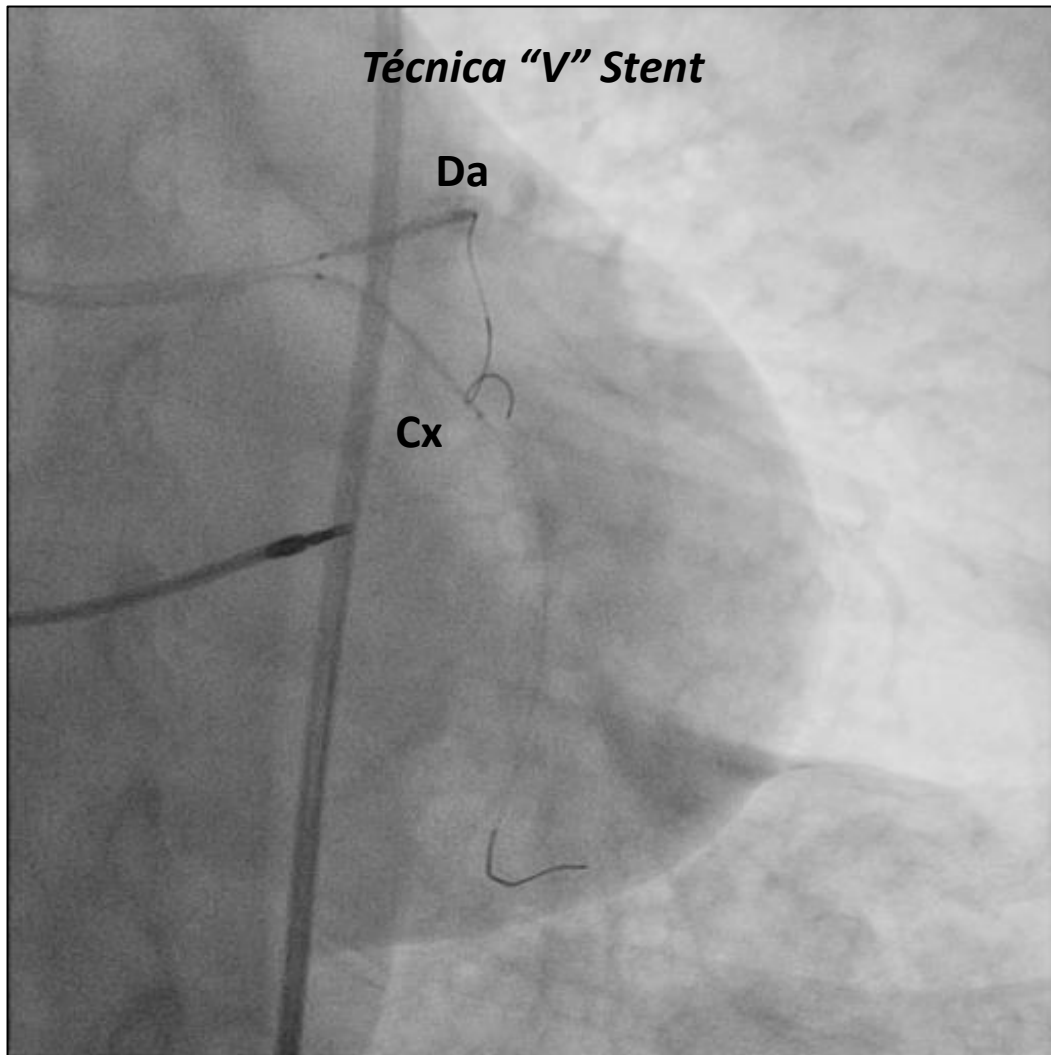


## ANGIOPLASTIA DEL TRONCO CORONARIO IZQUIERDO

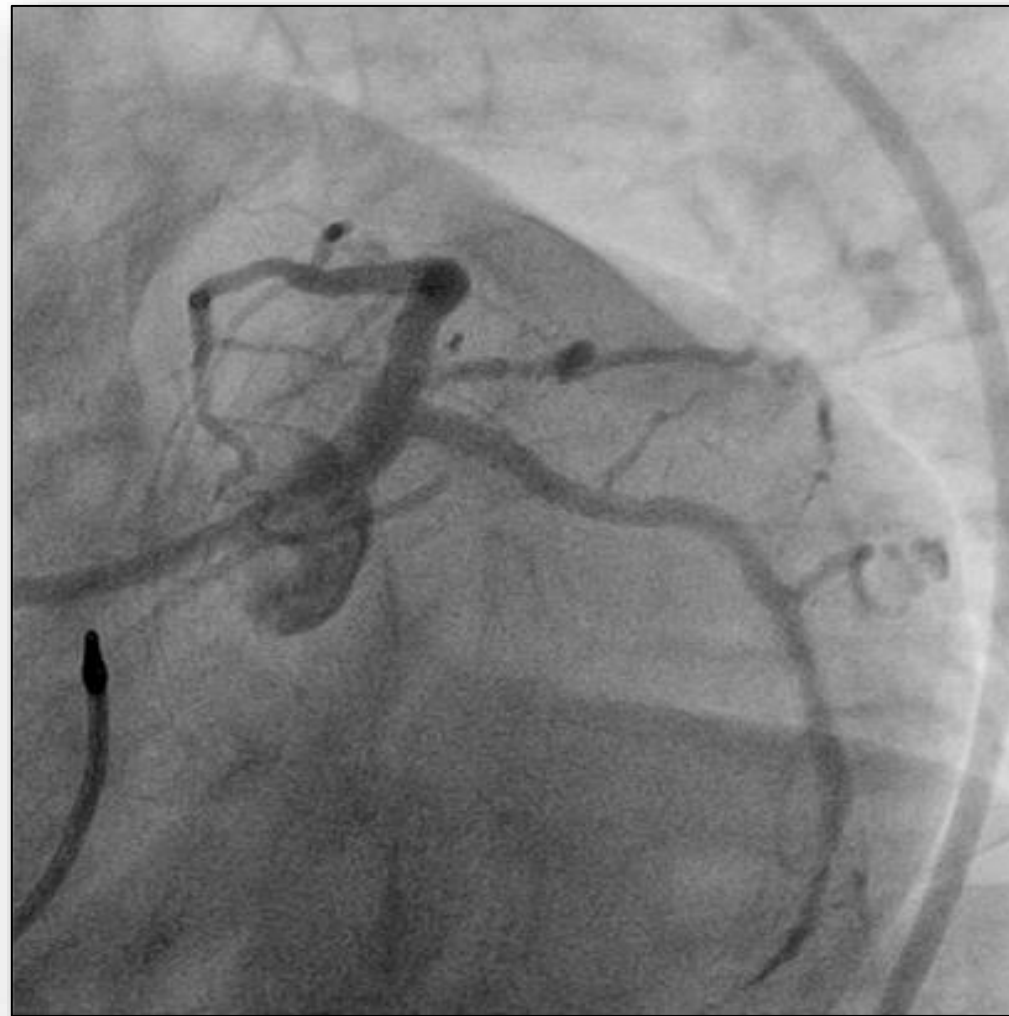

# ANGIOPLASTIA DEL TRONCO CORONARIO IZQUIERDO

*Técnica "V" Stent*

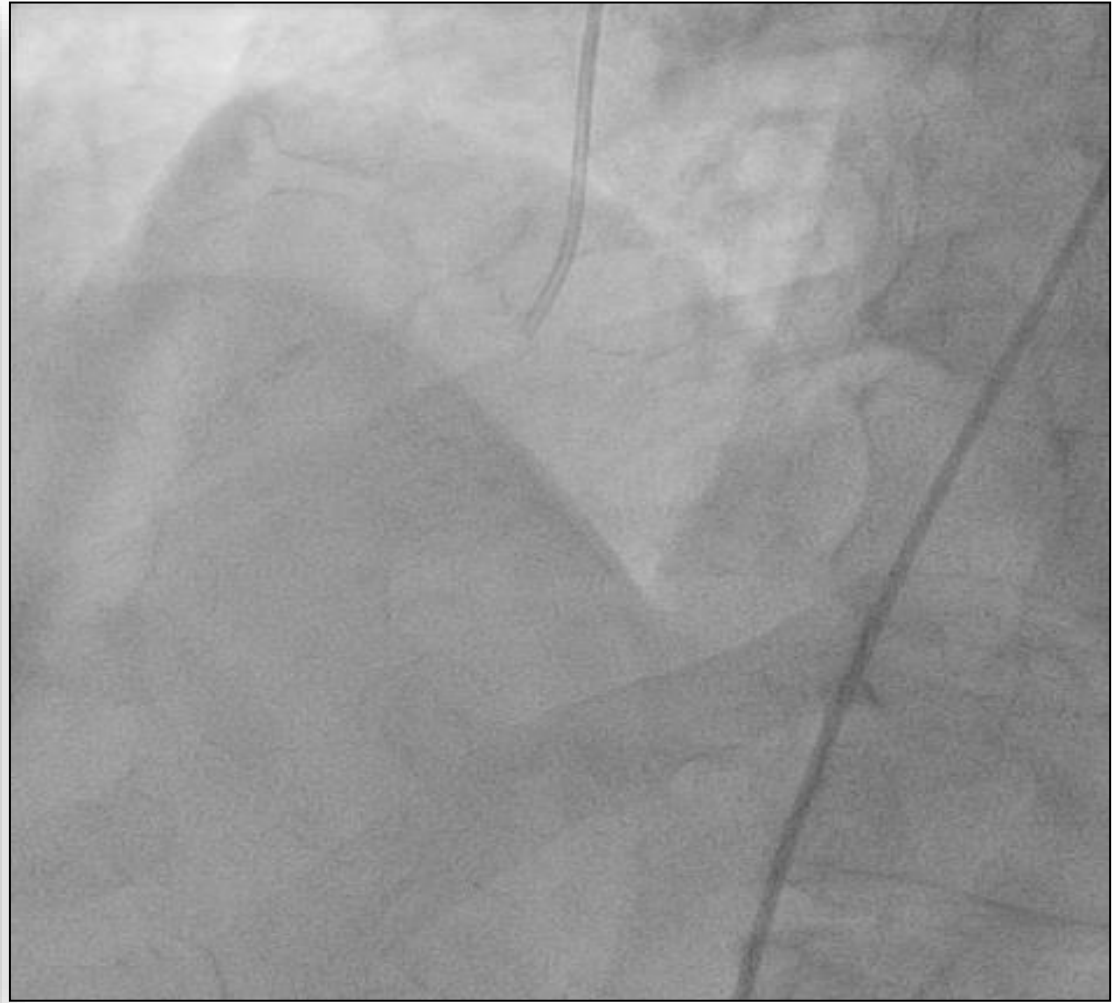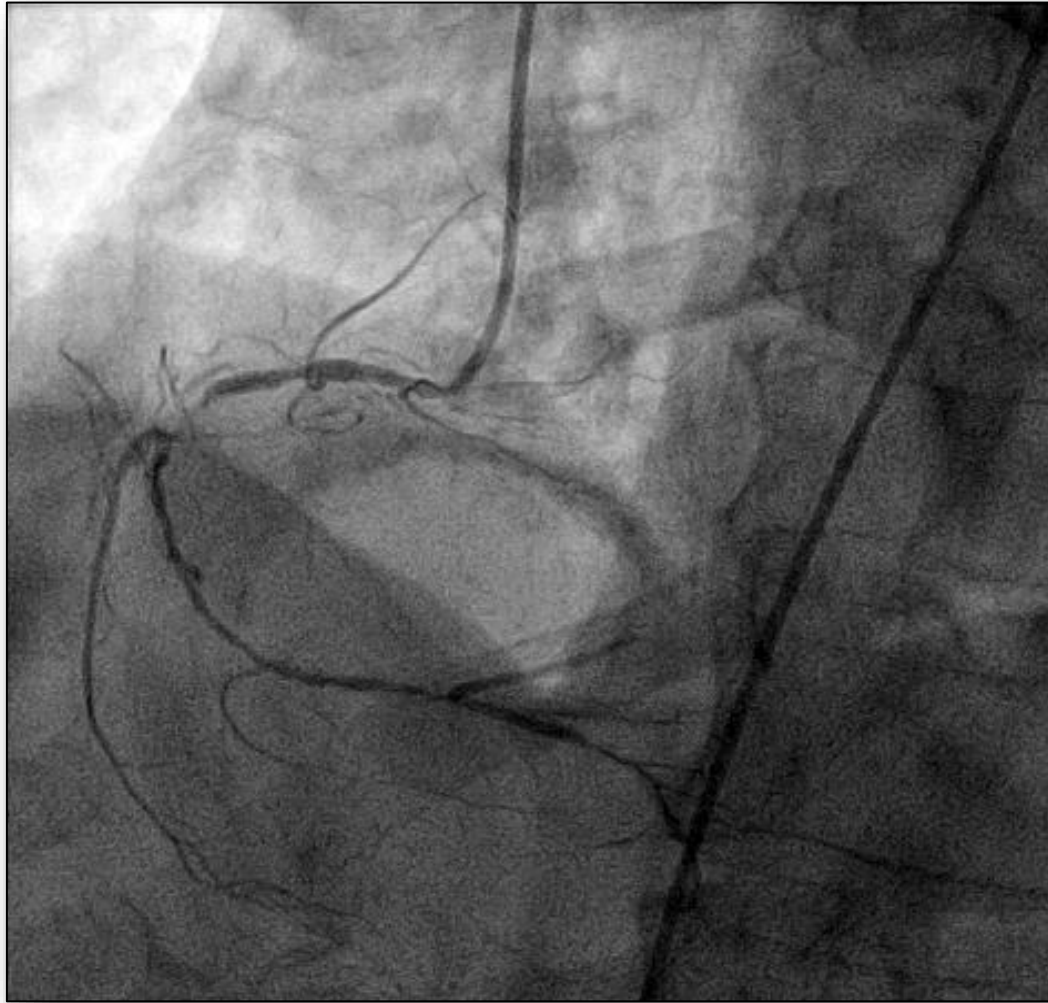


**CONTROL FINAL**

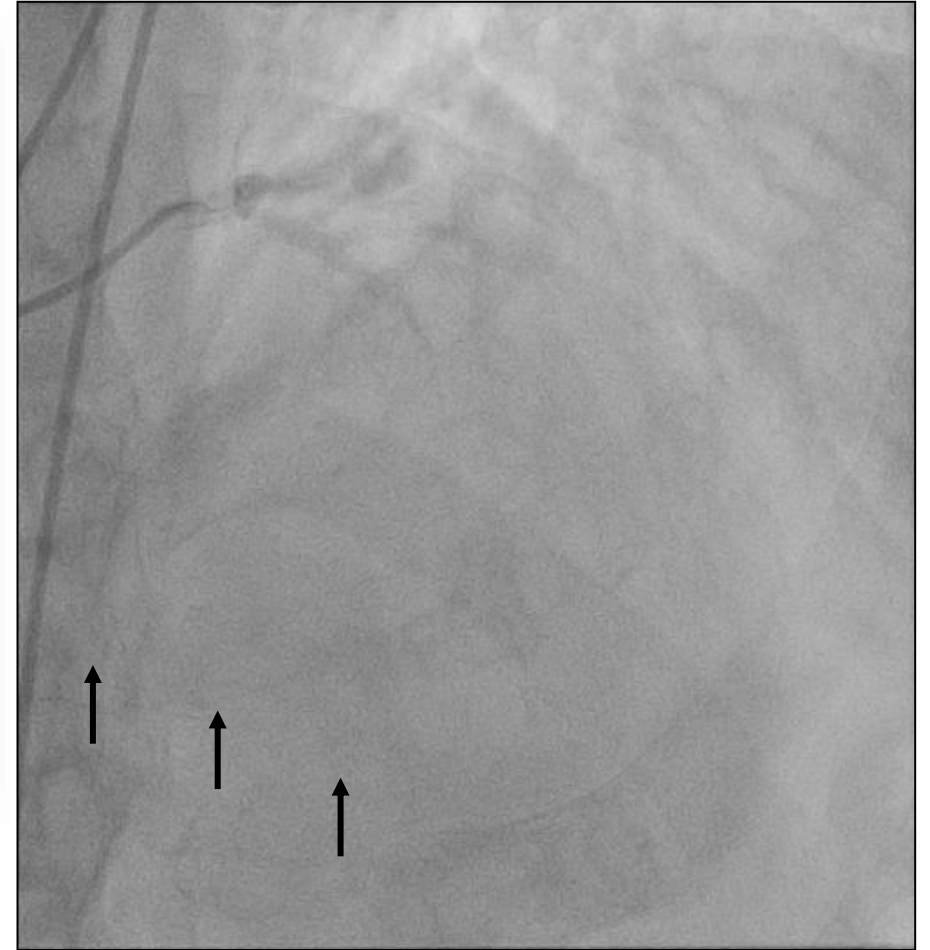
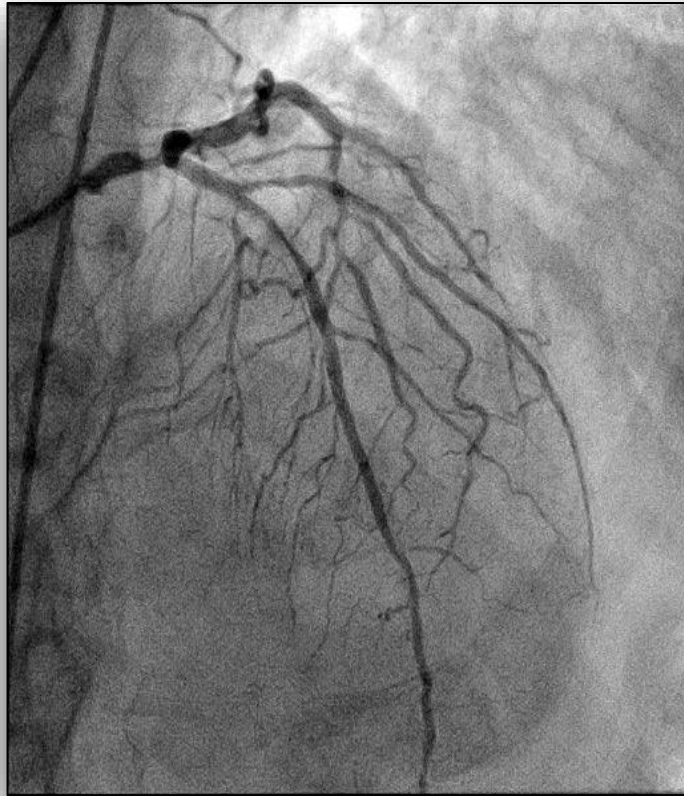
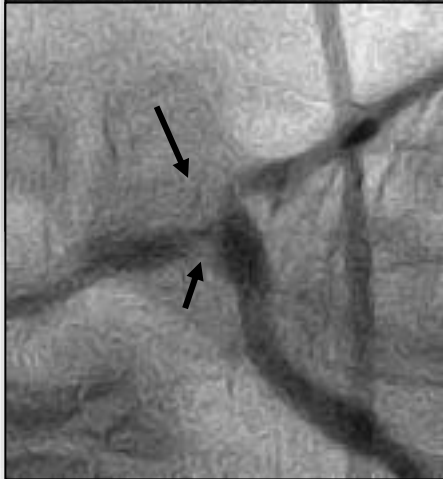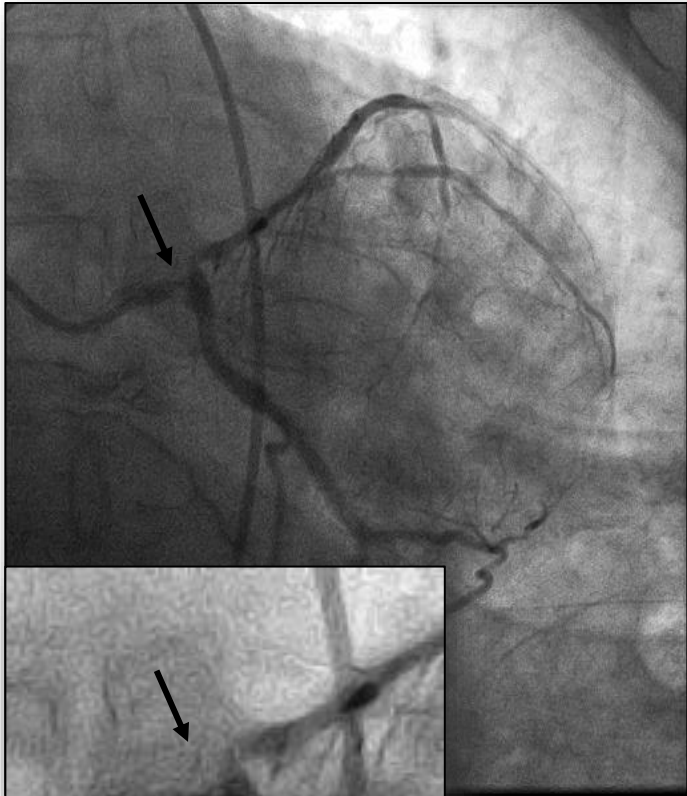




**CORONARIOGRAFÍA**  
**Masculino 84 años con Angina Inestable de alto riesgo en CF IV**

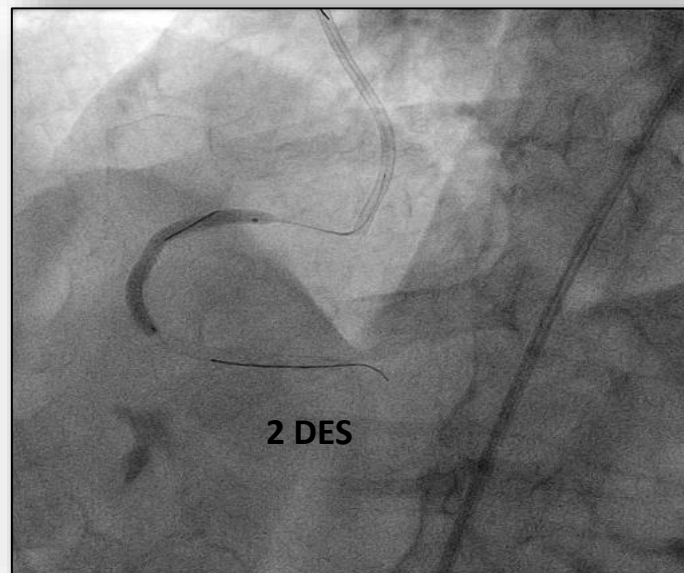
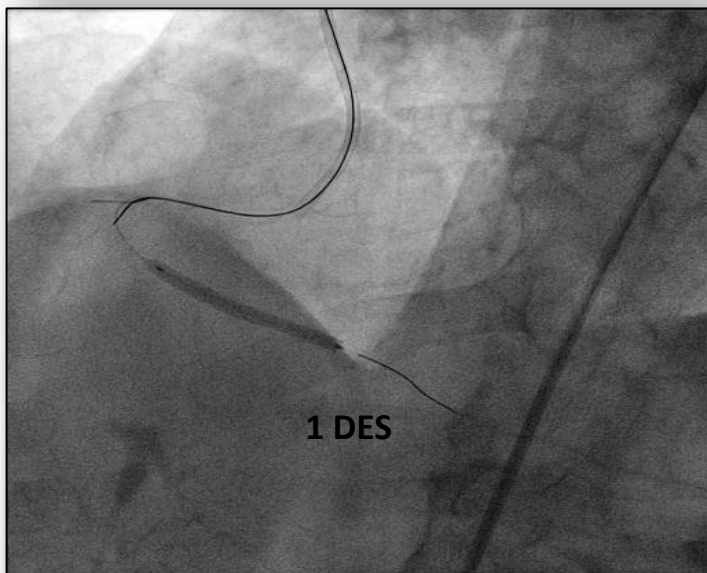
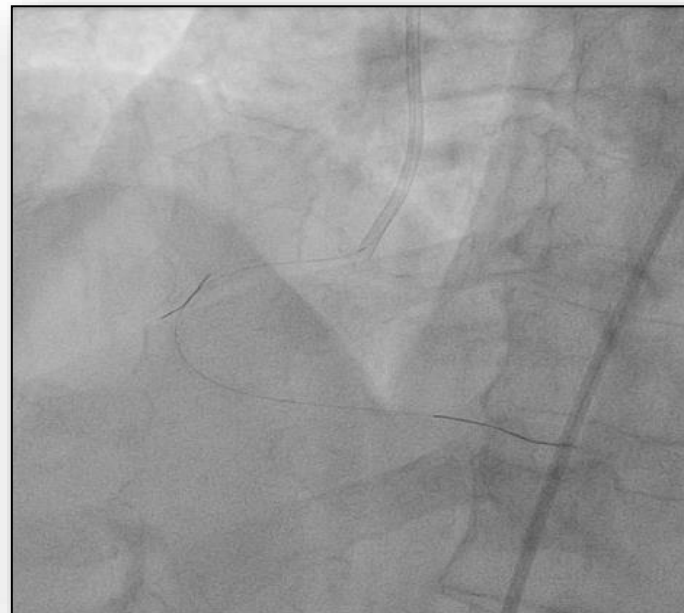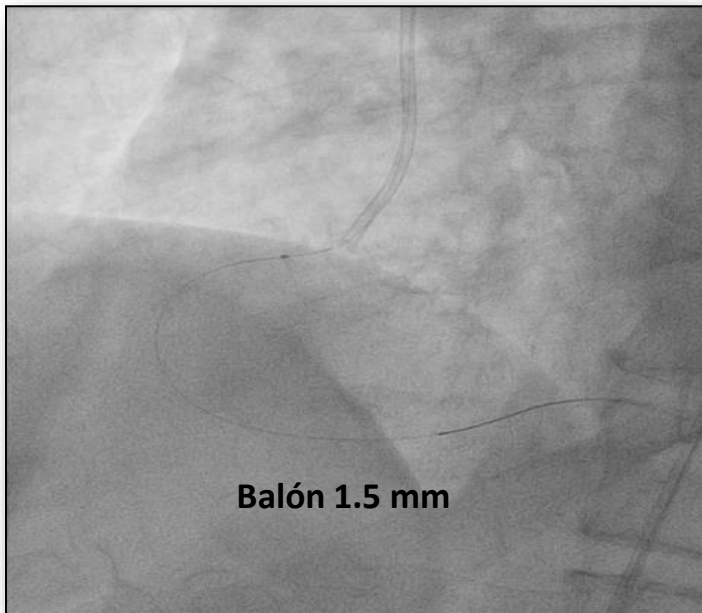


# ANGIOPLASTIA DEL TRONCO CORONARIO IZQUIERDO



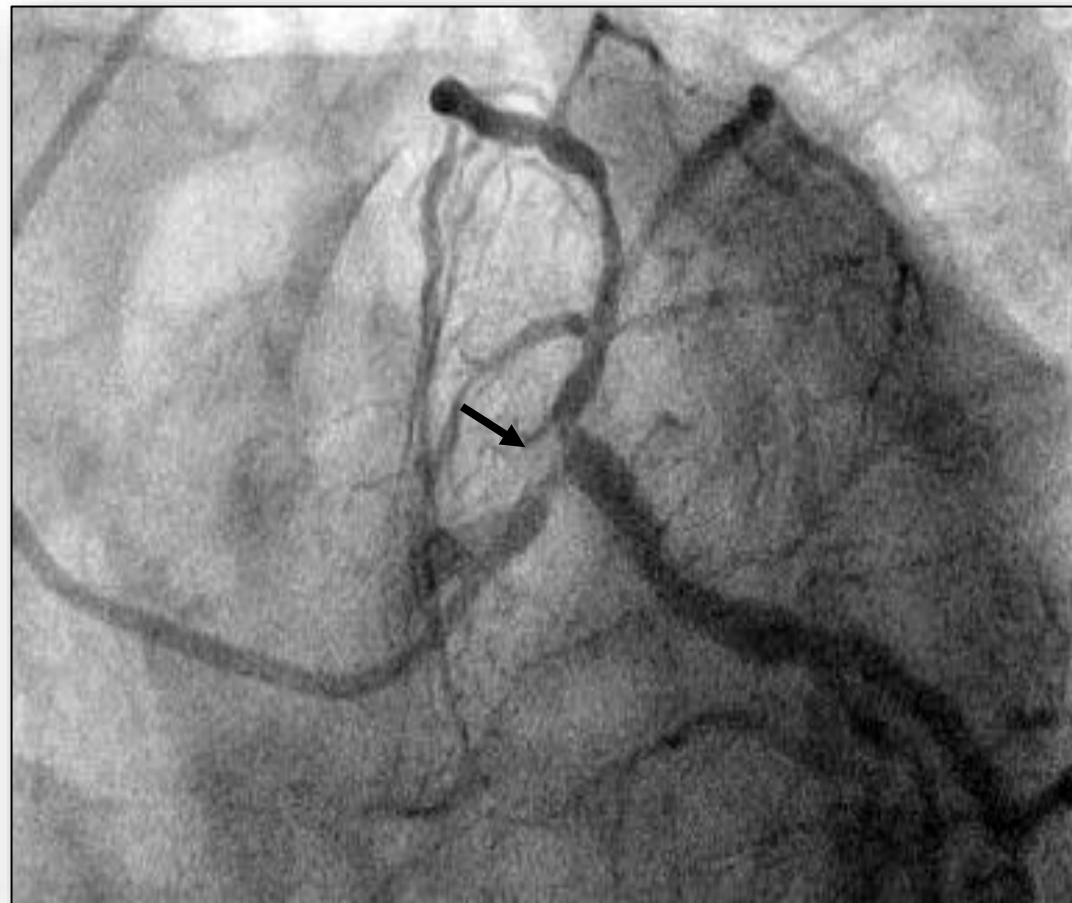
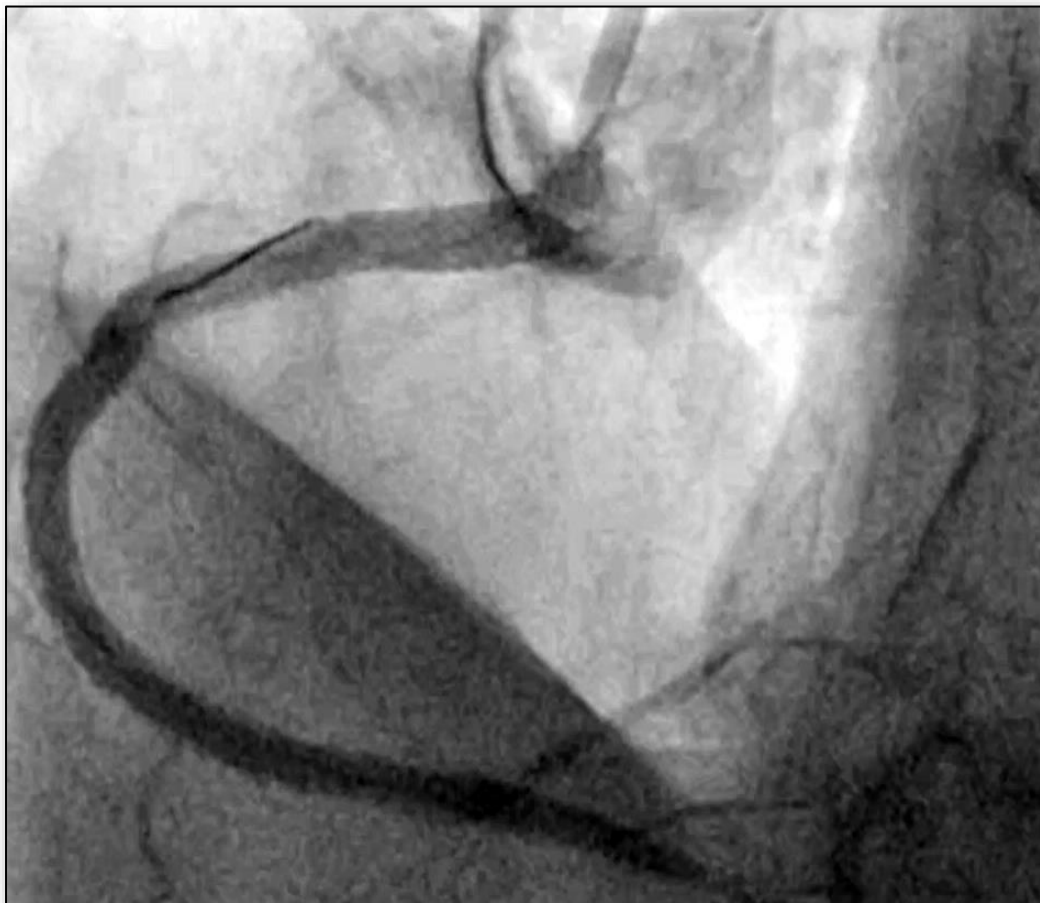


*Primer tiempo: Angioplastia de la arteria Coronaria Derecha*



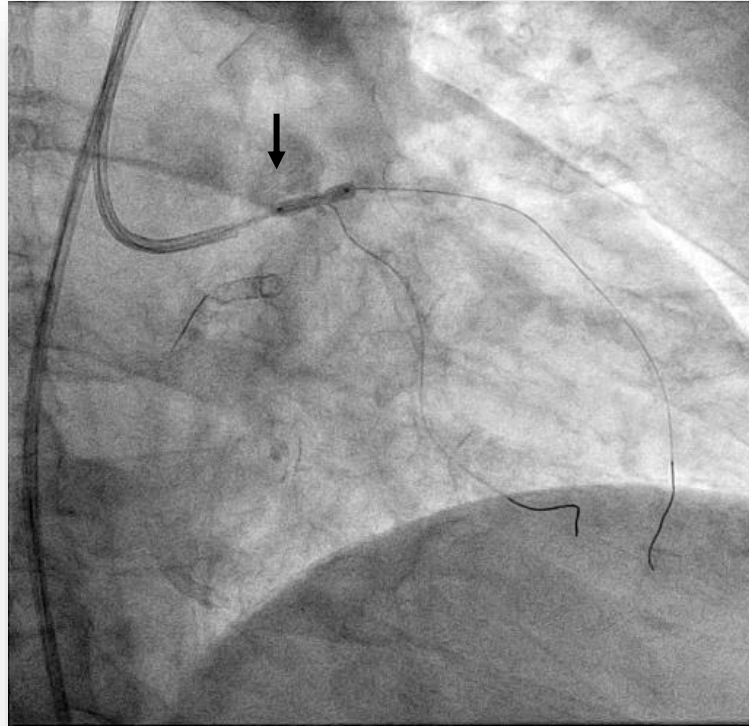
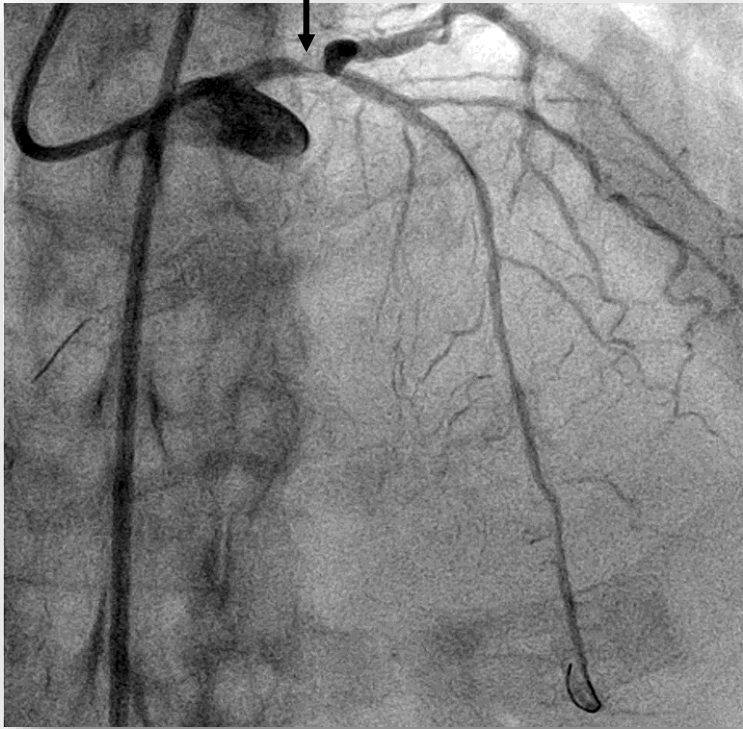
## ANGIOPLASTIA DEL TRONCO CORONARIO IZQUIERDO

*Segundo tiempo: angioplastia del TCI/Da (Stent Provisional)*

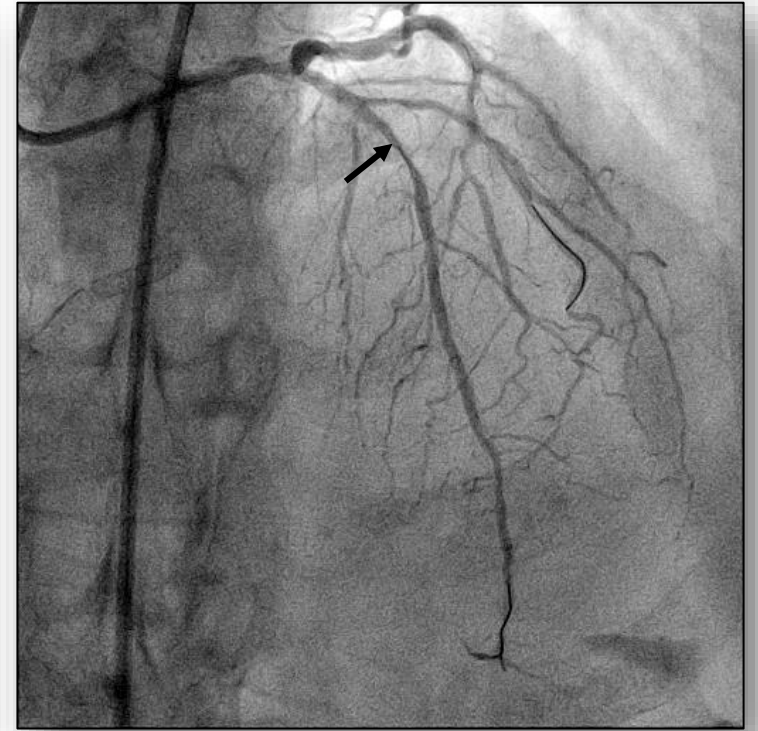




# ANGIOPLASTIA DEL TRONCO CORONARIO IZQUIERDO

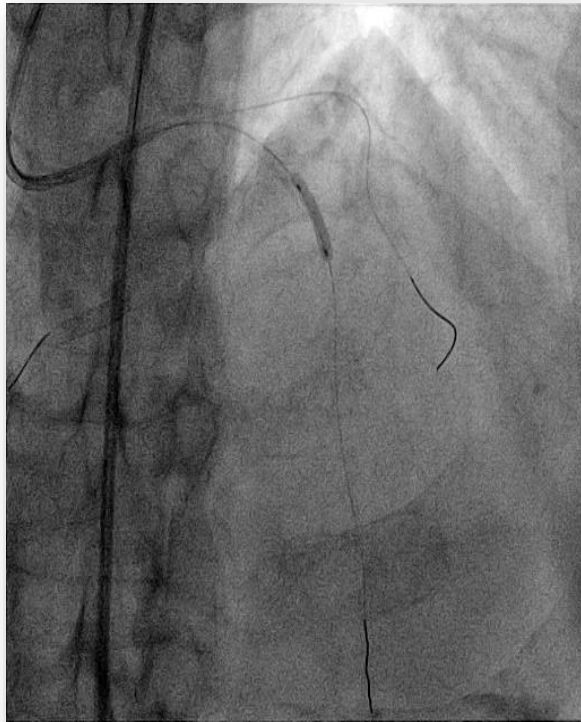


SCORING BALLOON 3.5 mm

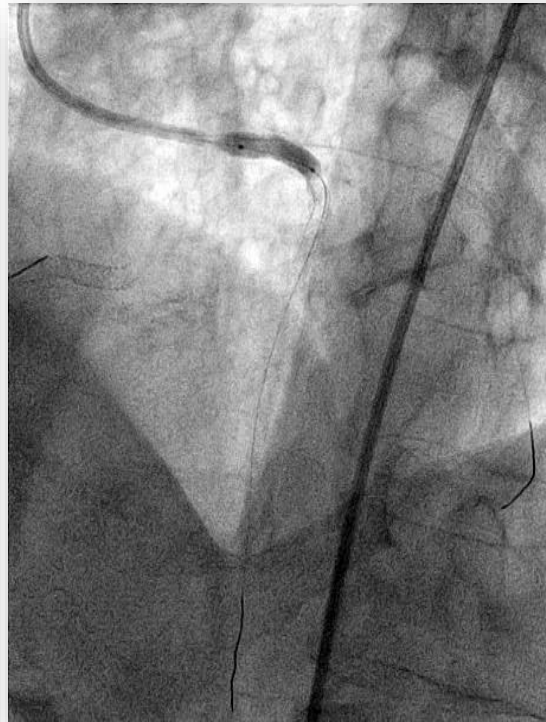


## ANGIOPLASTIA DEL TRONCO CORONARIO IZQUIERDO

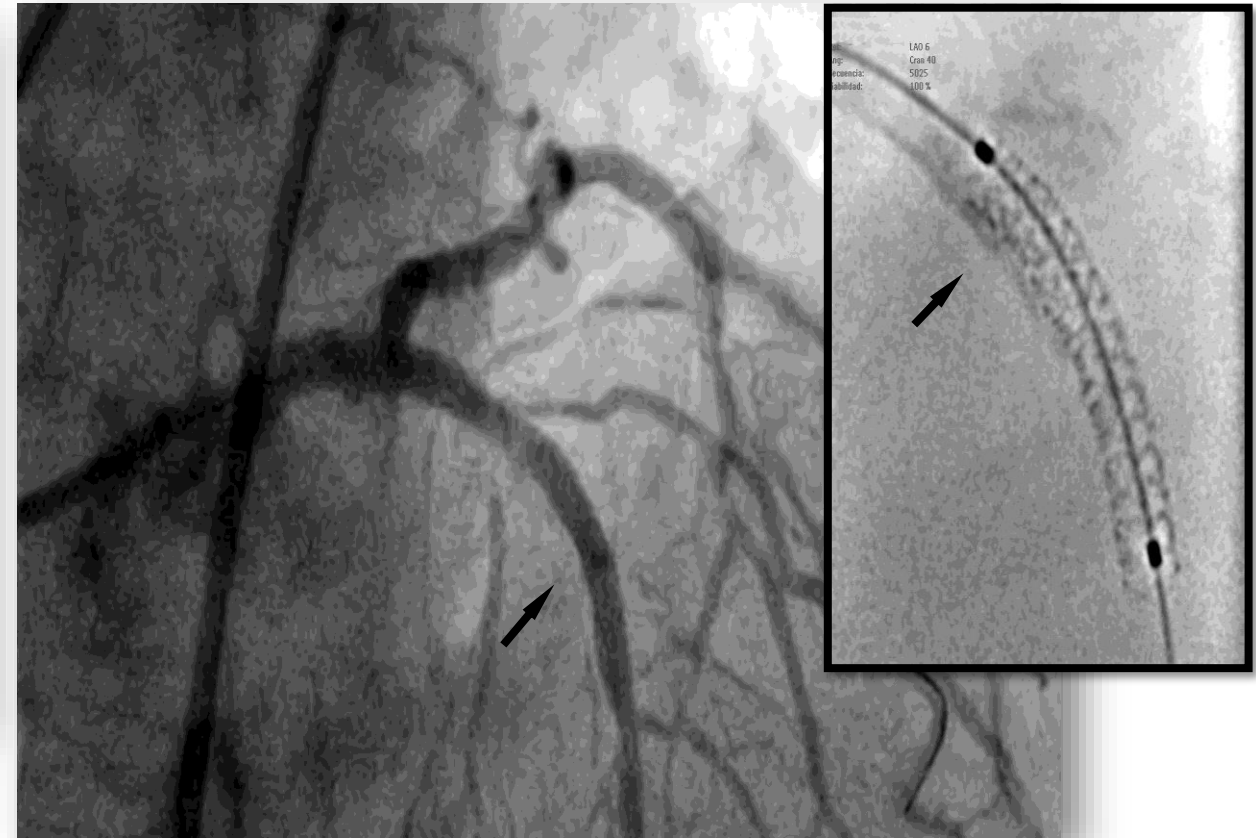
*Segundo tiempo: angioplastia del TCI/Da (Stent Provisional)*



DA -DES (Everolimus)  
3.0 x 16 mm

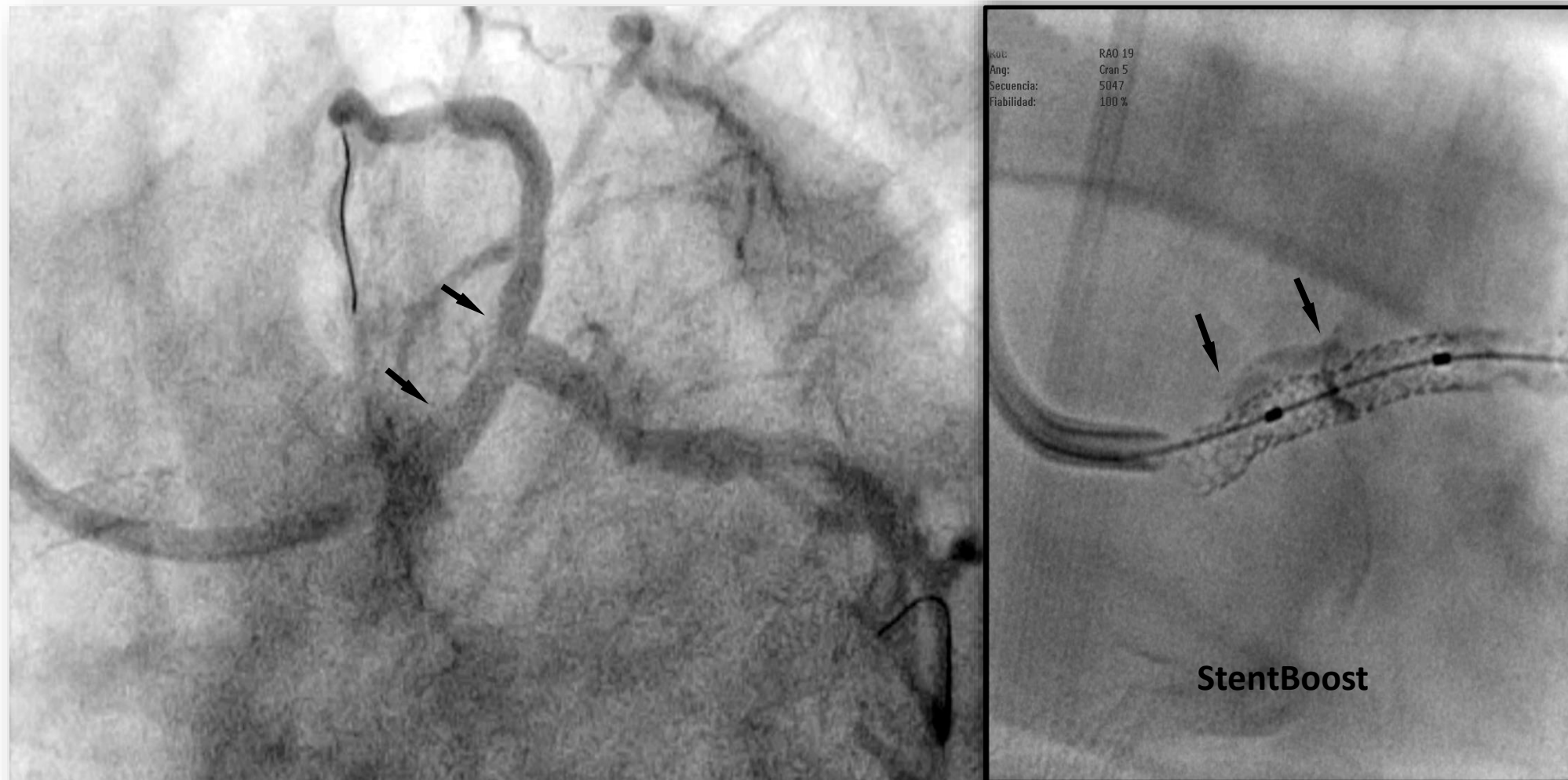


POT -DES (Everolimus)  
3.5 x 18 mm



Control

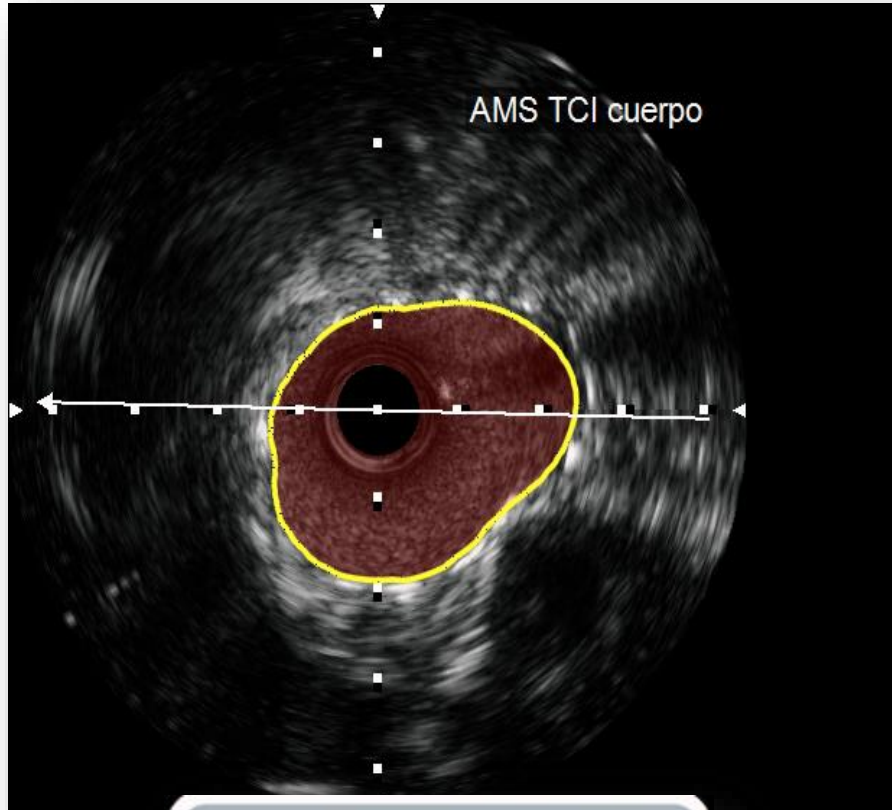
# ANGIOPLASTIA DEL TRONCO CORONARIO IZQUIERDO



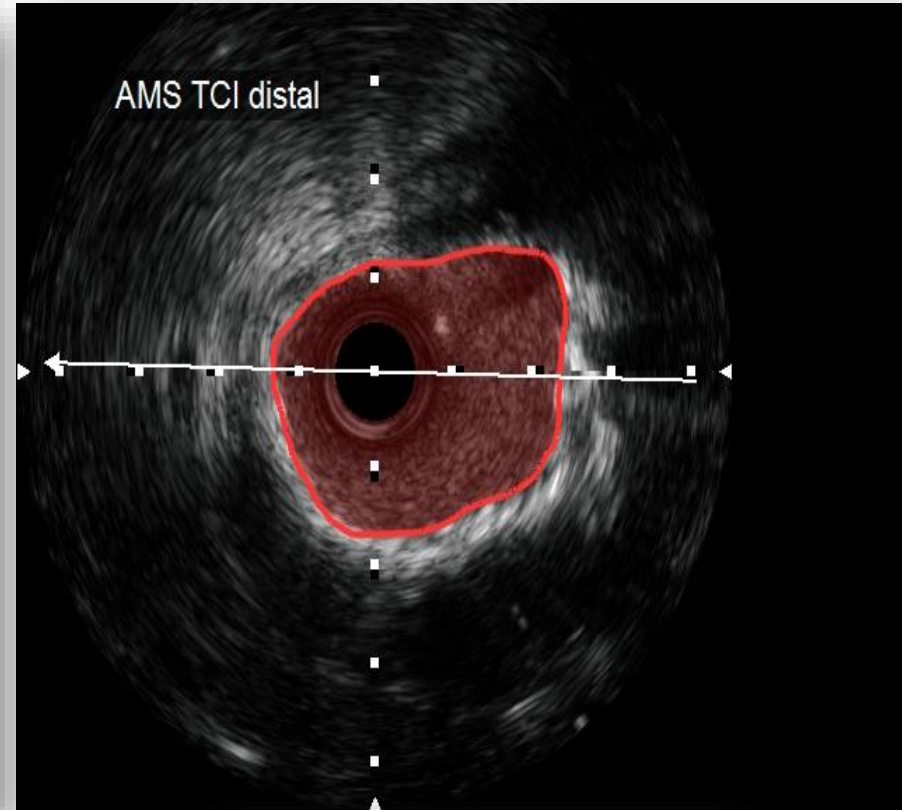


# ANGIOPLASTIA DEL TRONCO CORONARIO IZQUIERDO

Control con IVUS



Measurements  
A2 TA 8.66 mm<sup>2</sup>

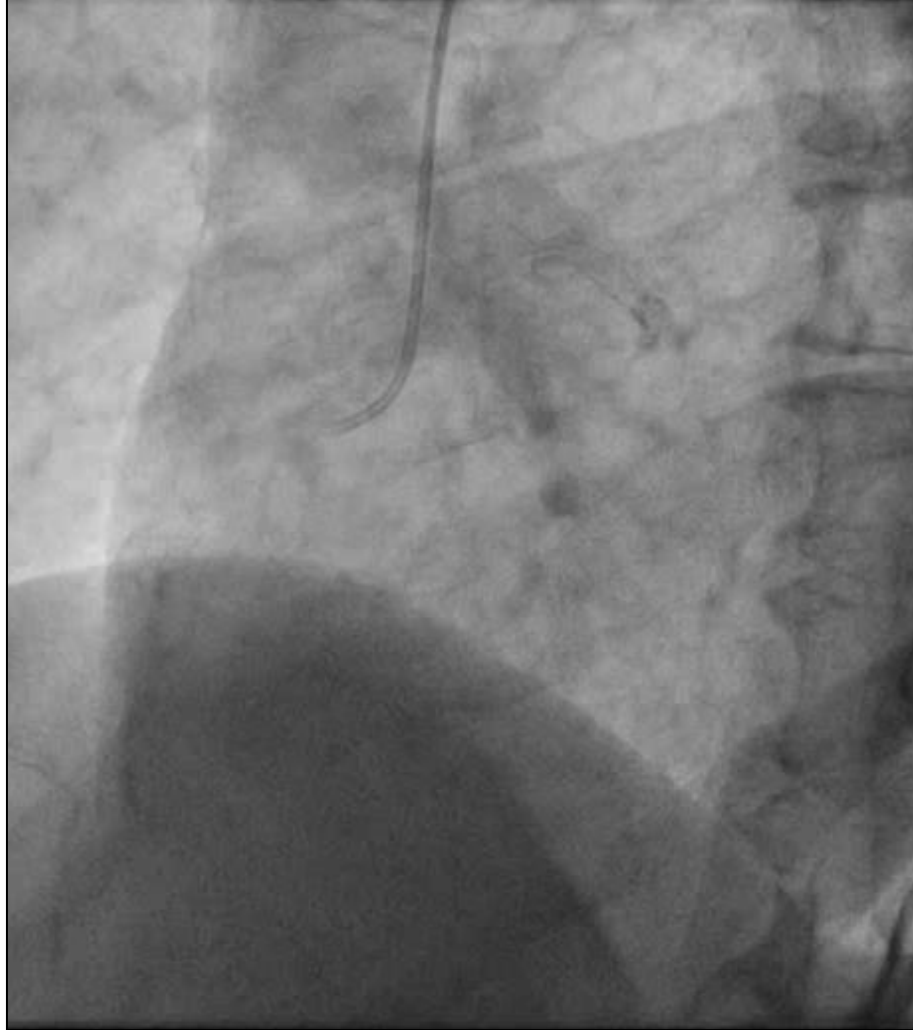
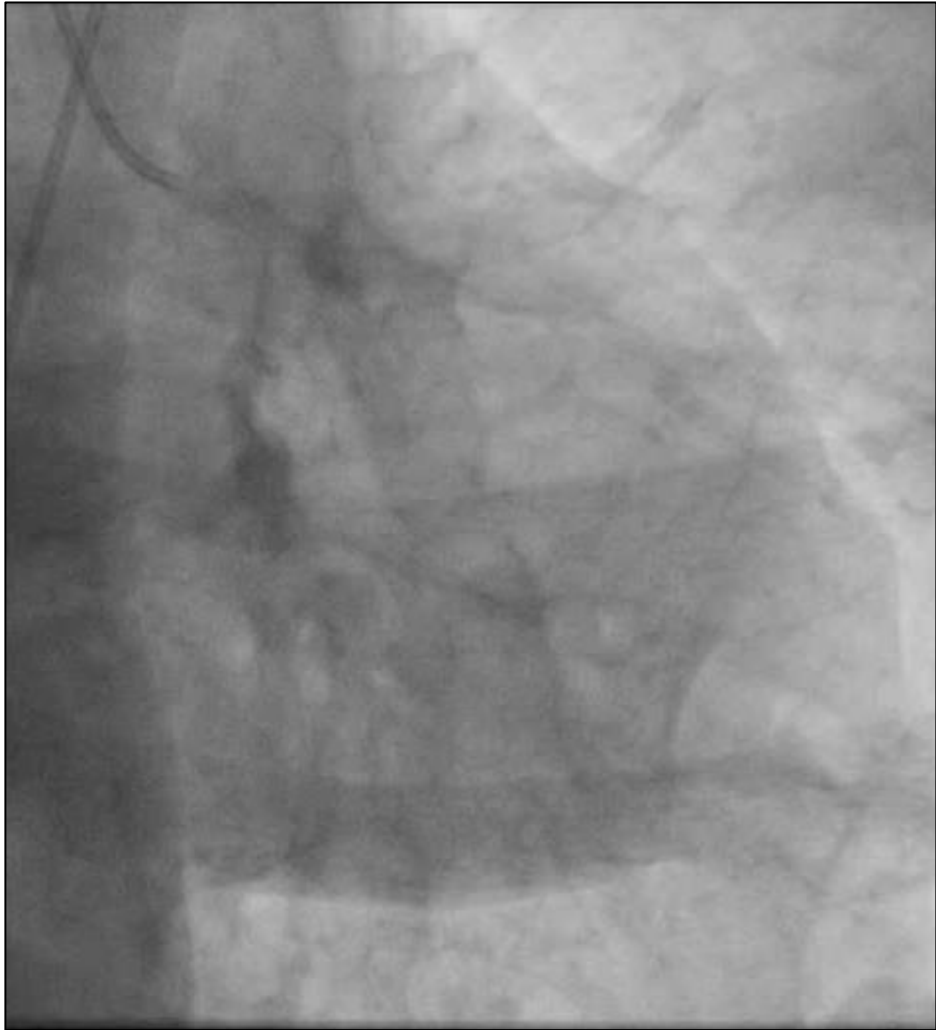

Measurements  
A1 8.47 mm<sup>2</sup>

***5 años después el paciente se mantiene asintomático (con 89 años de edad).***

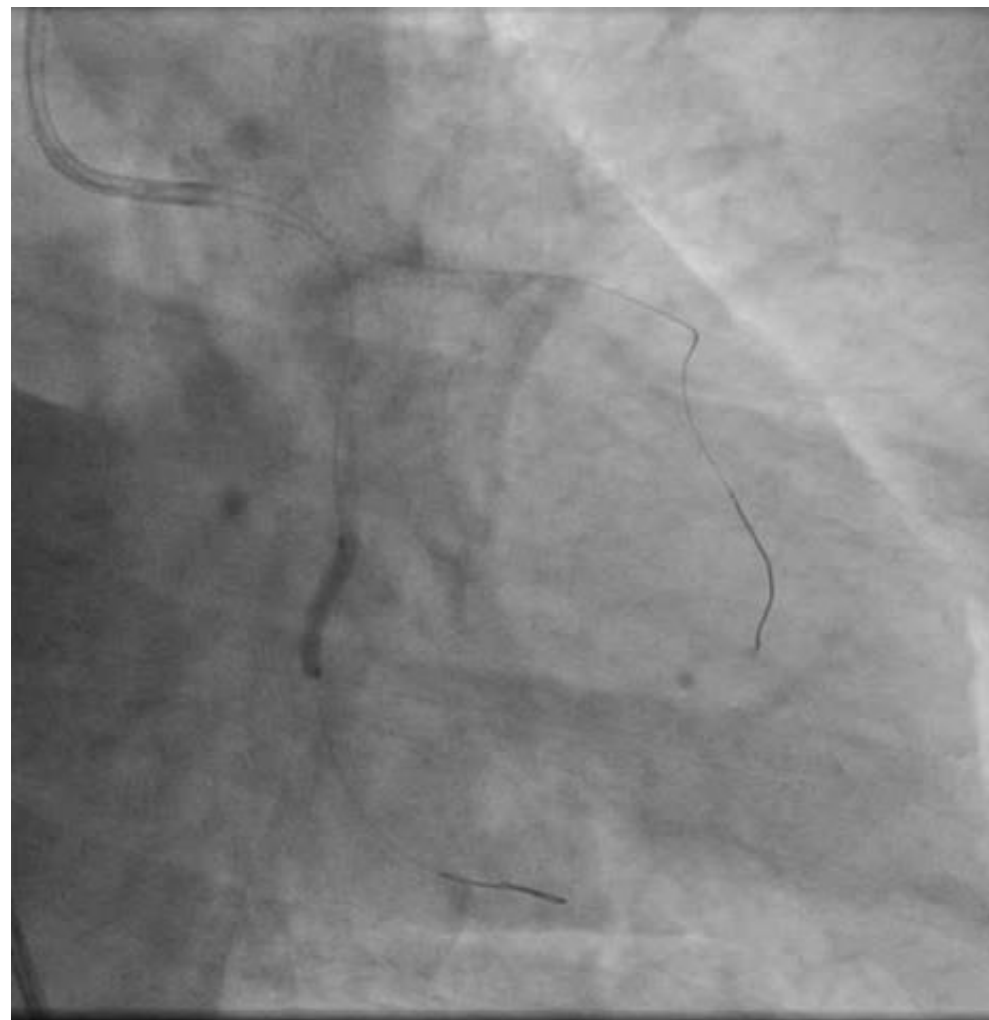
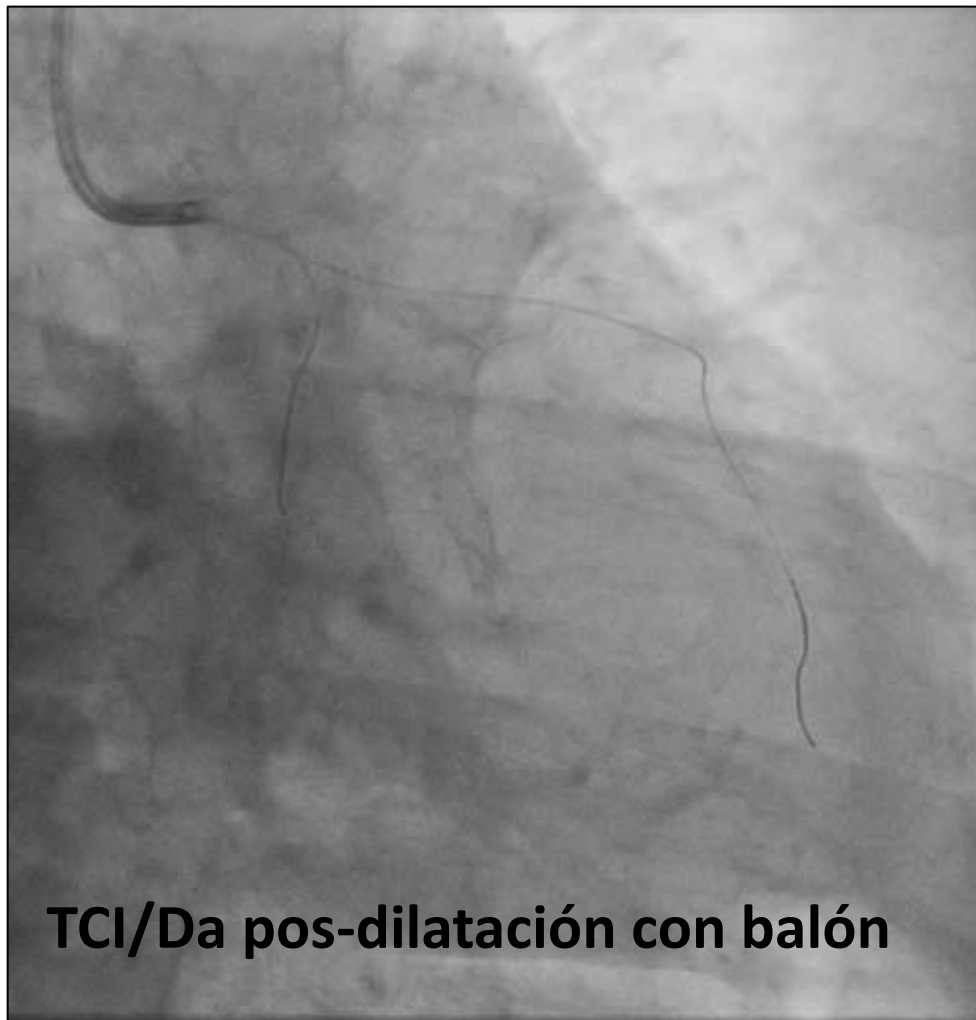

**CORONARIOGRAFÍA**  
**Masculino 82 años con IAM Killip B**  
**Instent-restenosis TCI-Da/Cx**



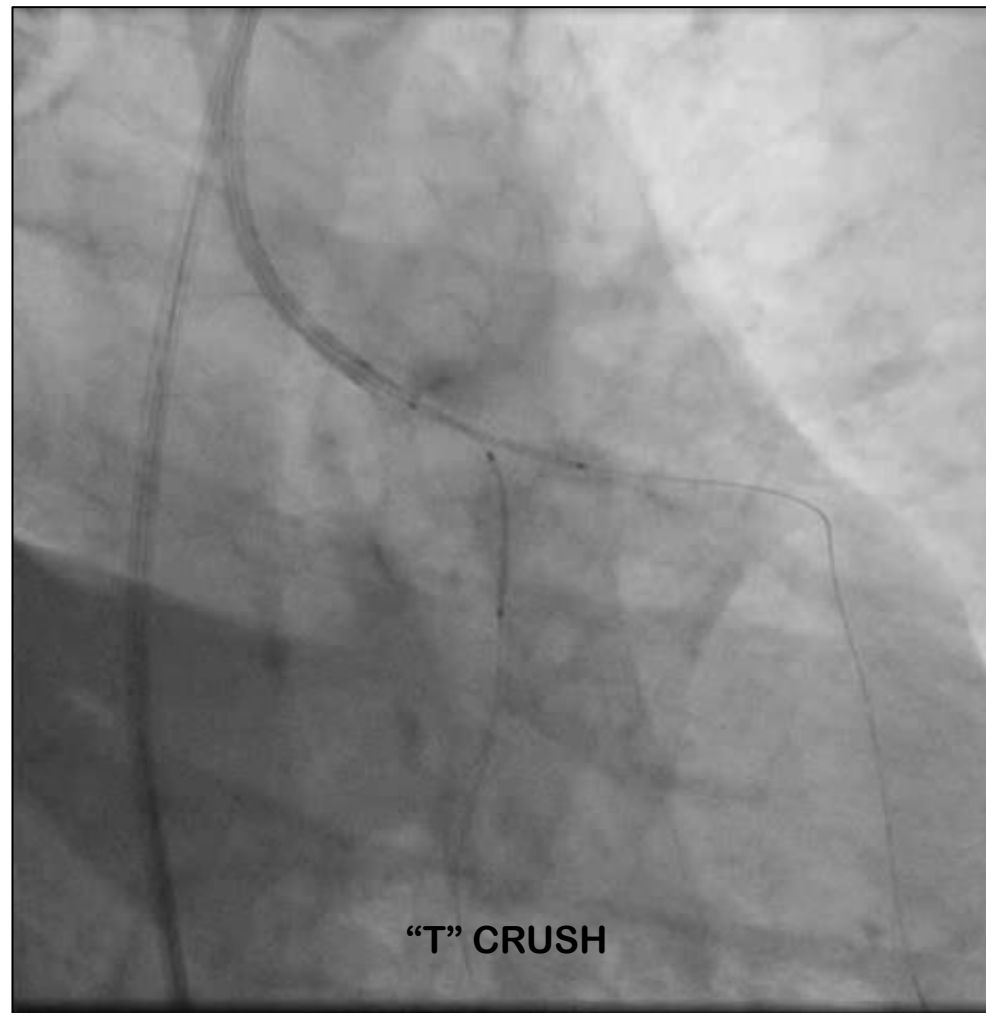
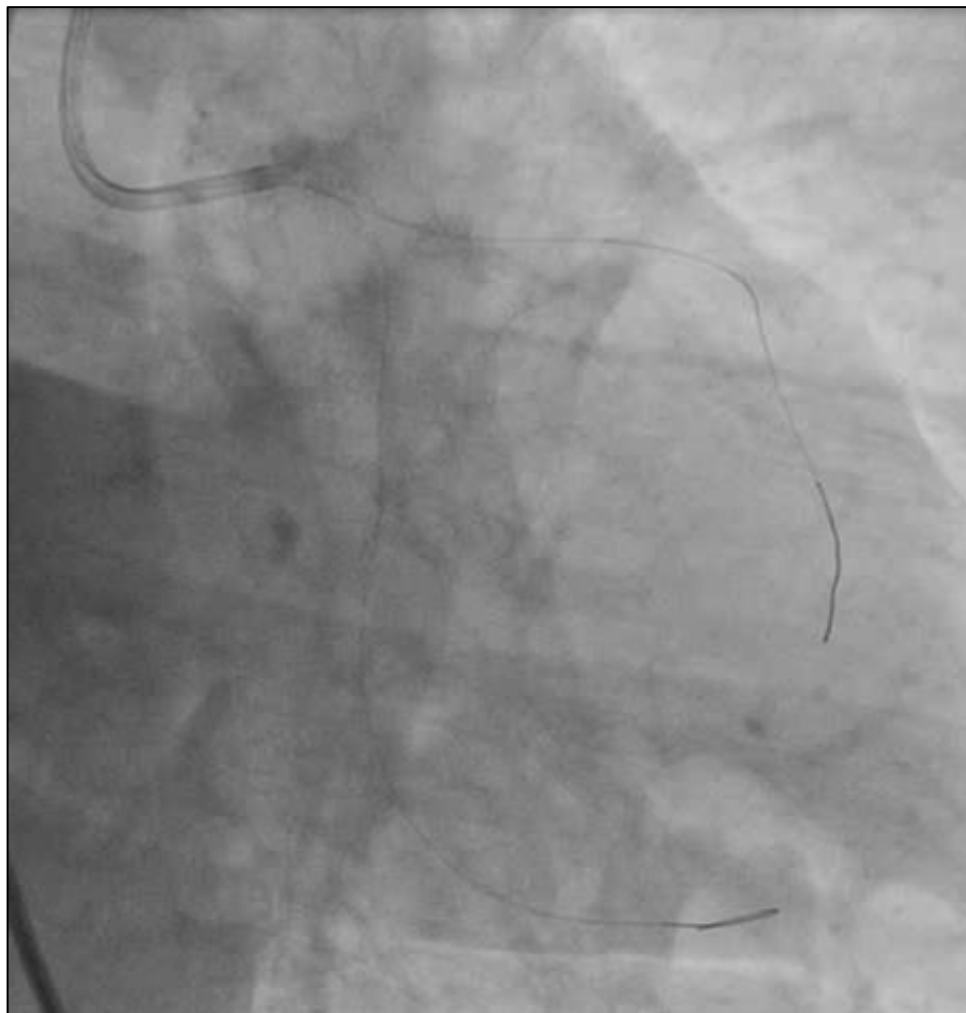

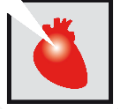## ANGIOPLASTIA DEL TRONCO CORONARIO IZQUIERDO



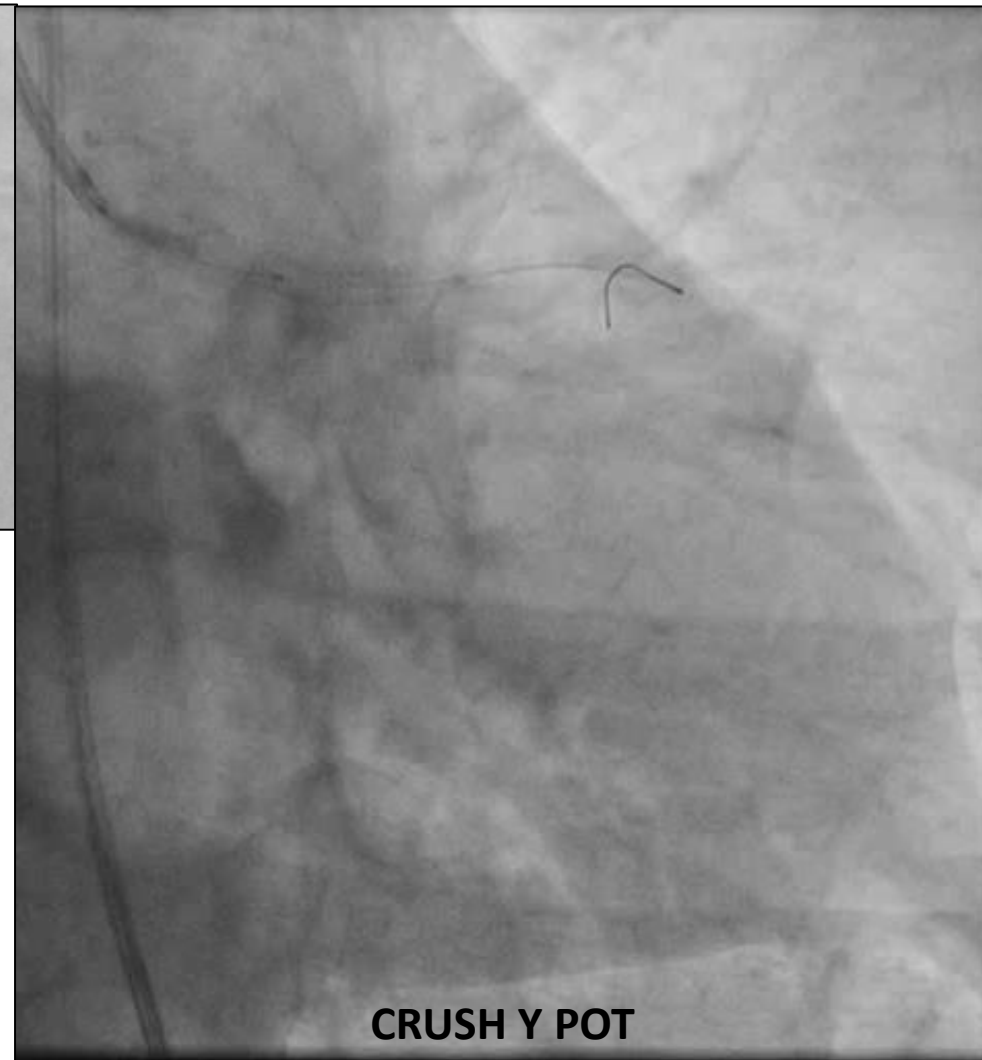
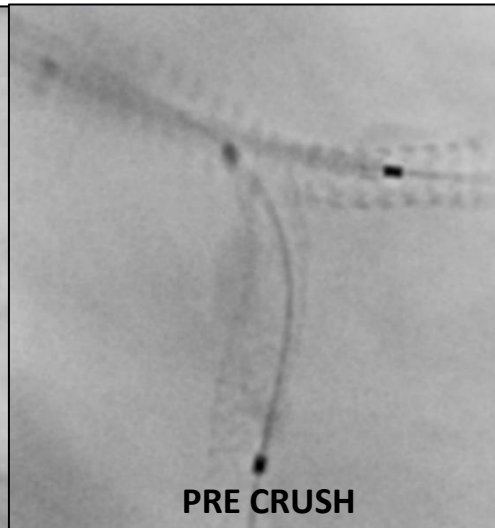
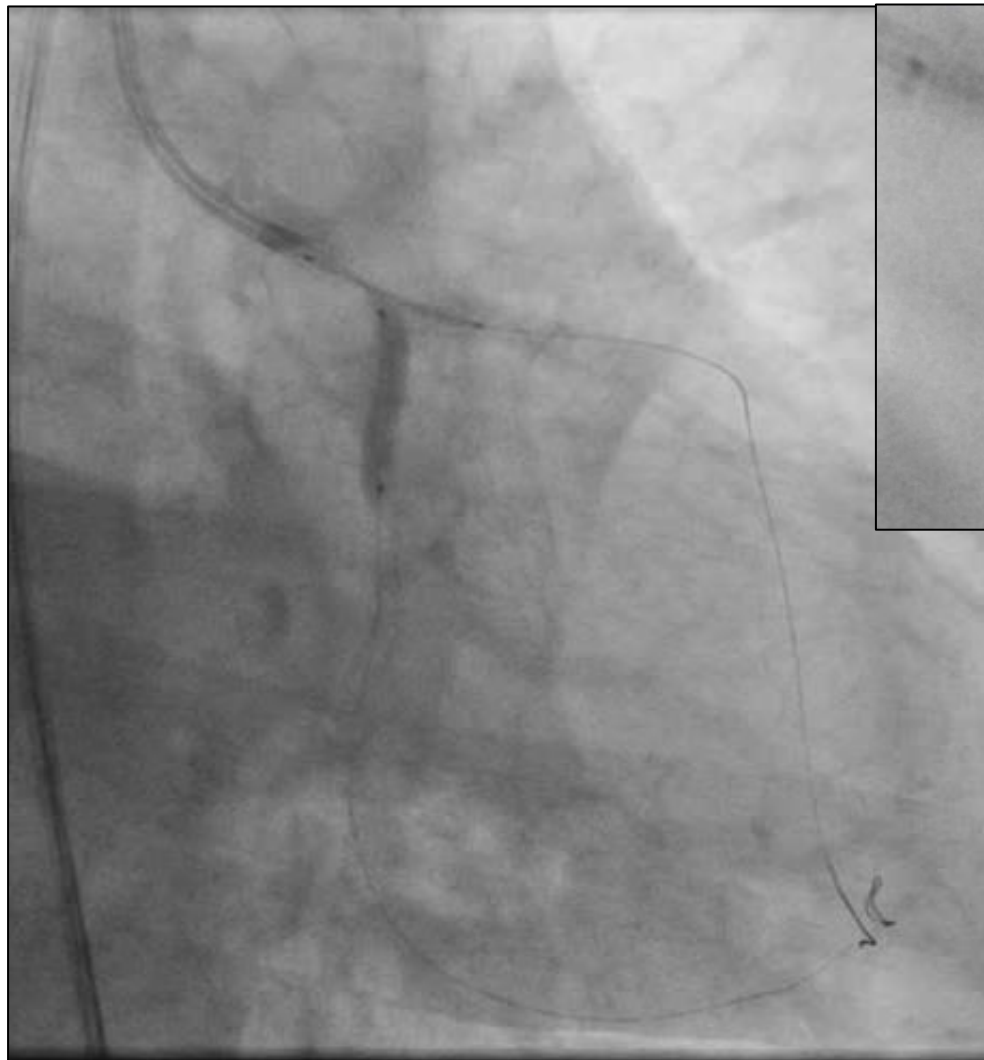

## ANGIOPLASTIA DEL TRONCO CORONARIO IZQUIERDO





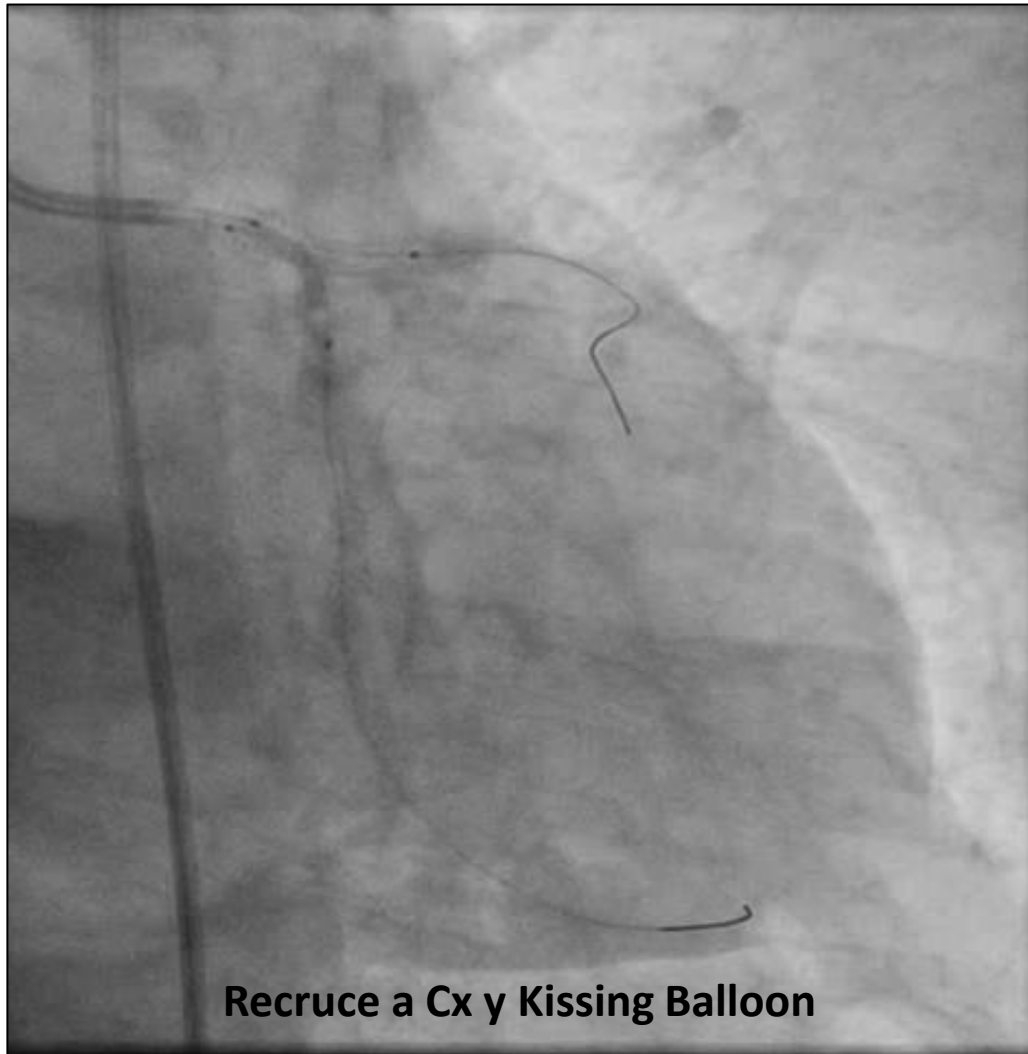
# ANGIOPLASTIA DEL TRONCO CORONARIO IZQUIERDO



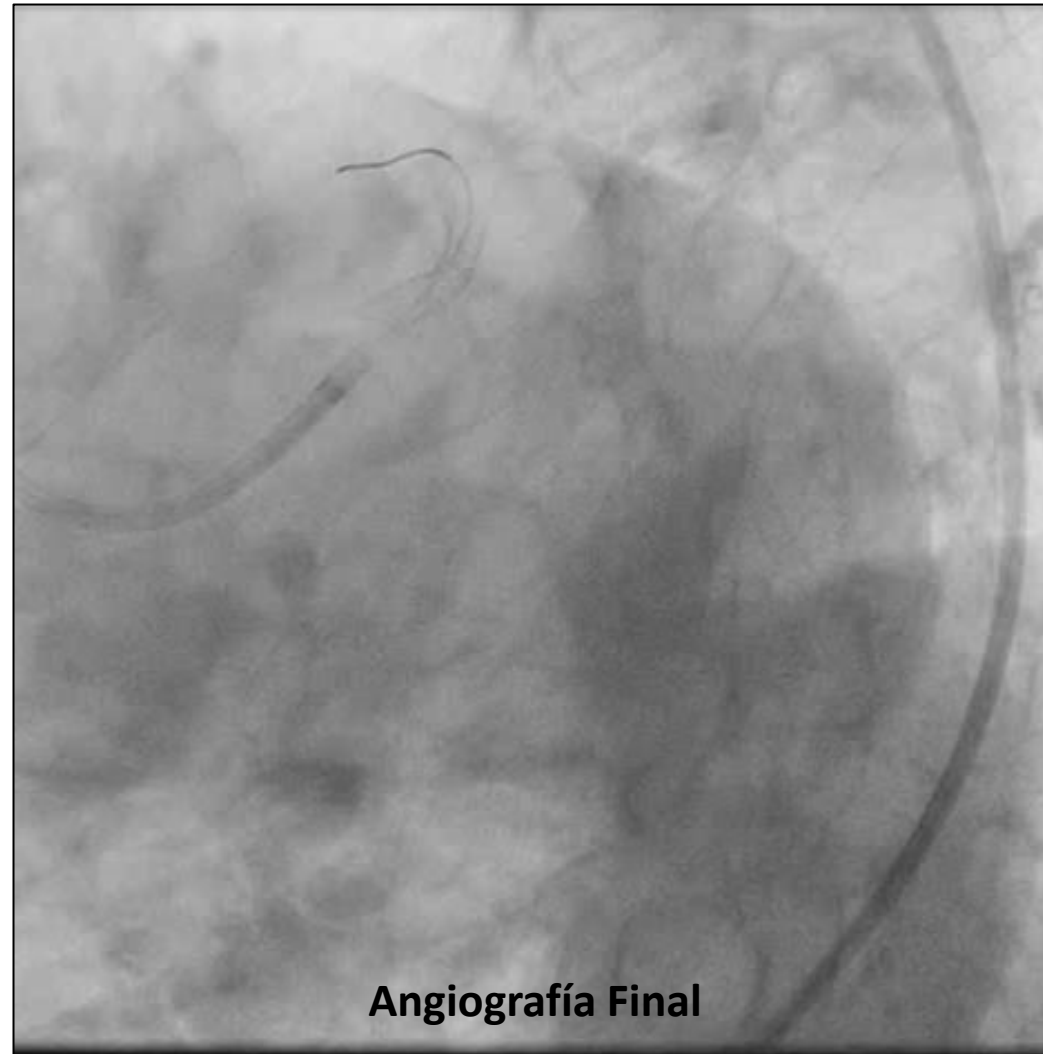




# ANGIOPLASTIA DEL TRONCO CORONARIO IZQUIERDO

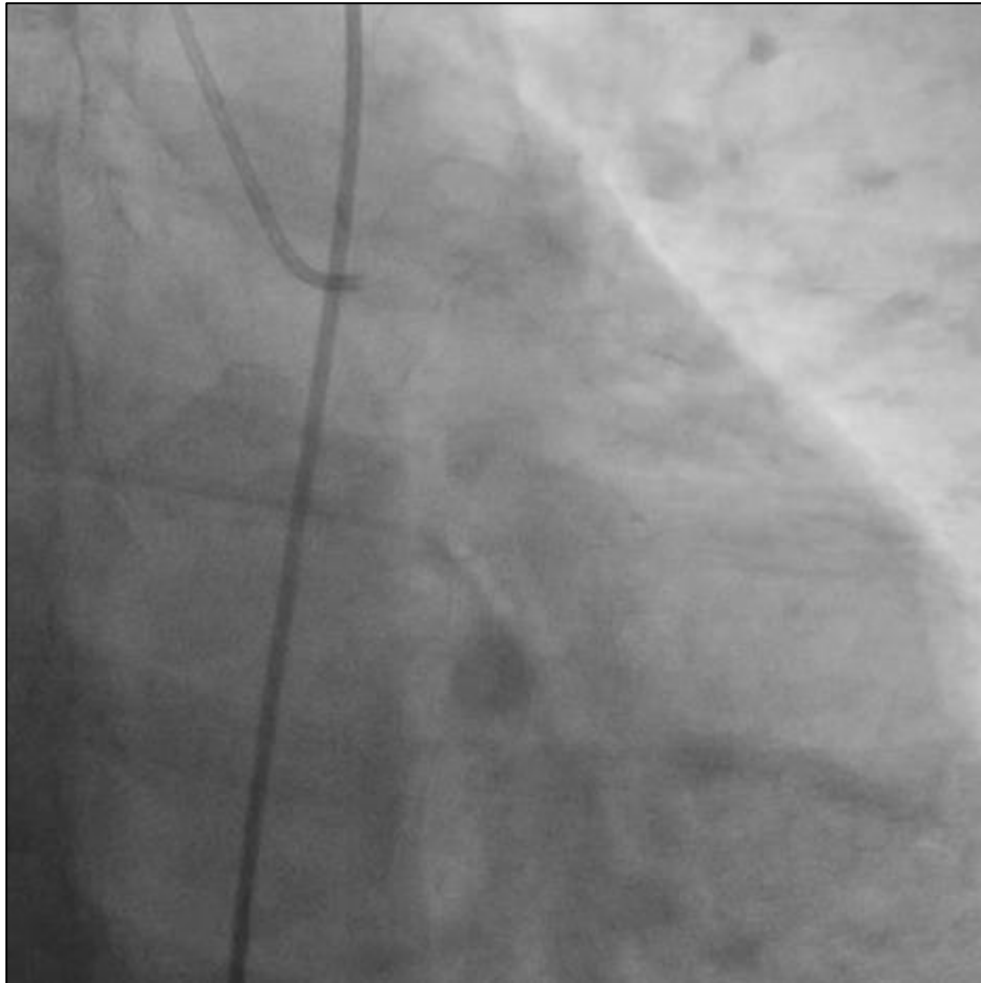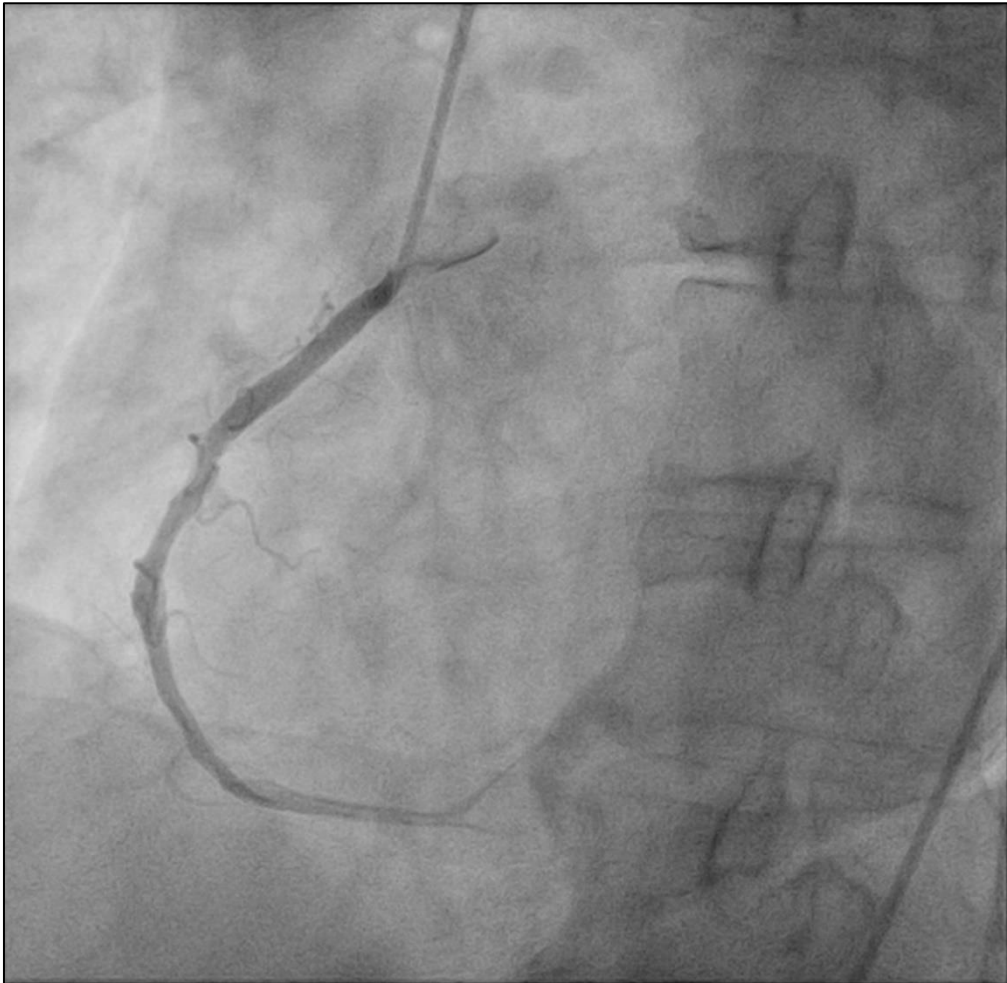


Recruce a Cx y Kissing Balloon

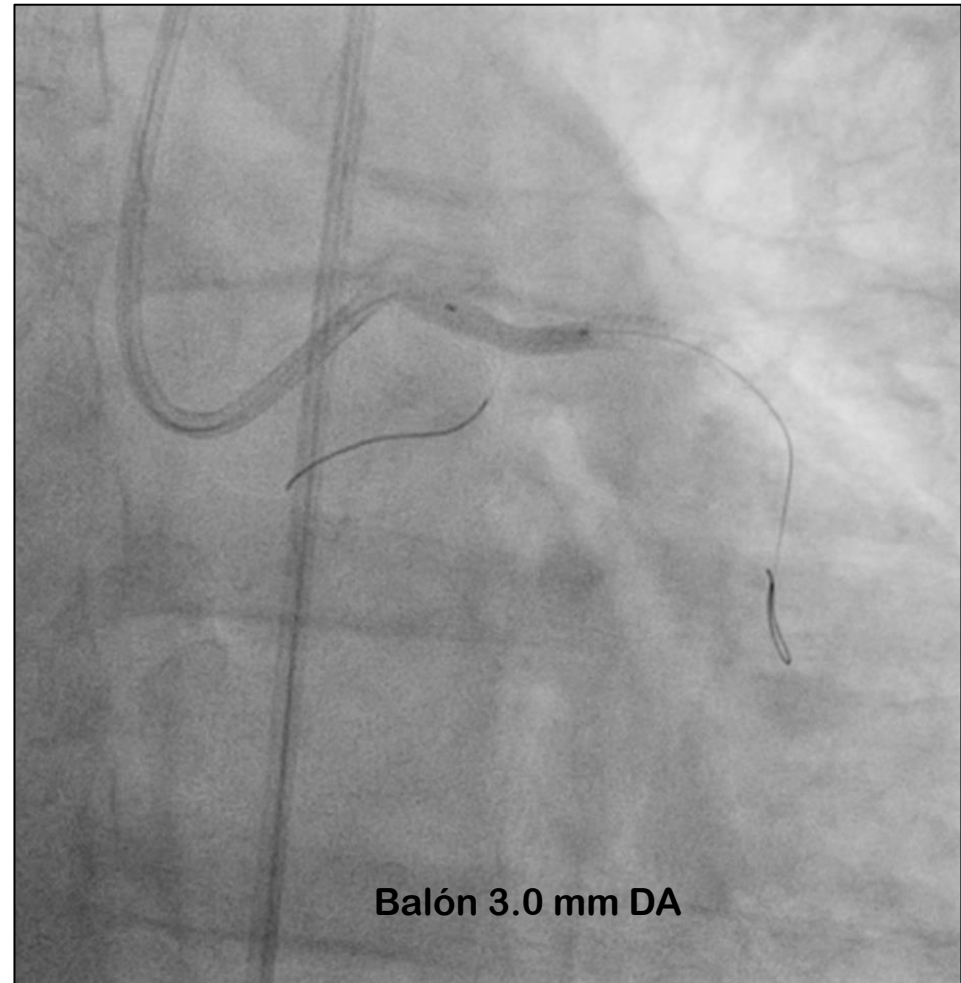
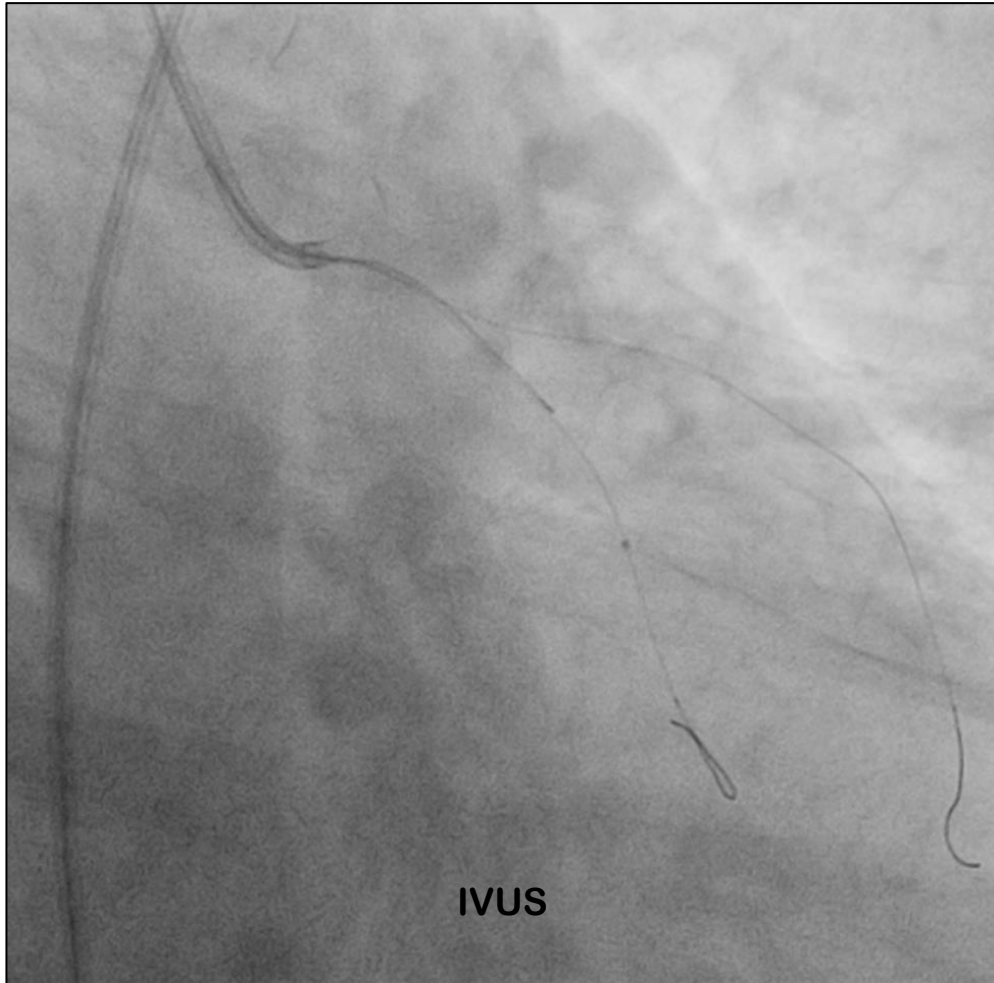


Angiografía Final

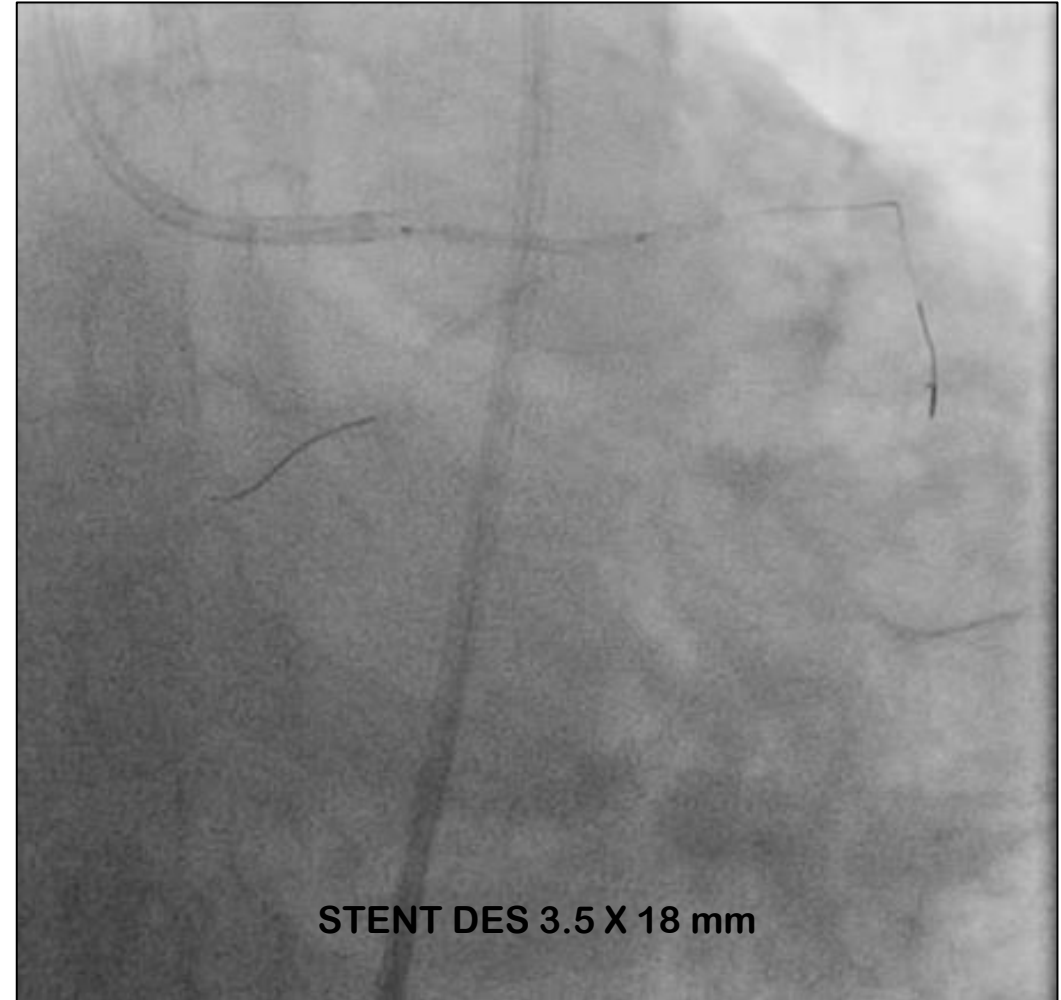
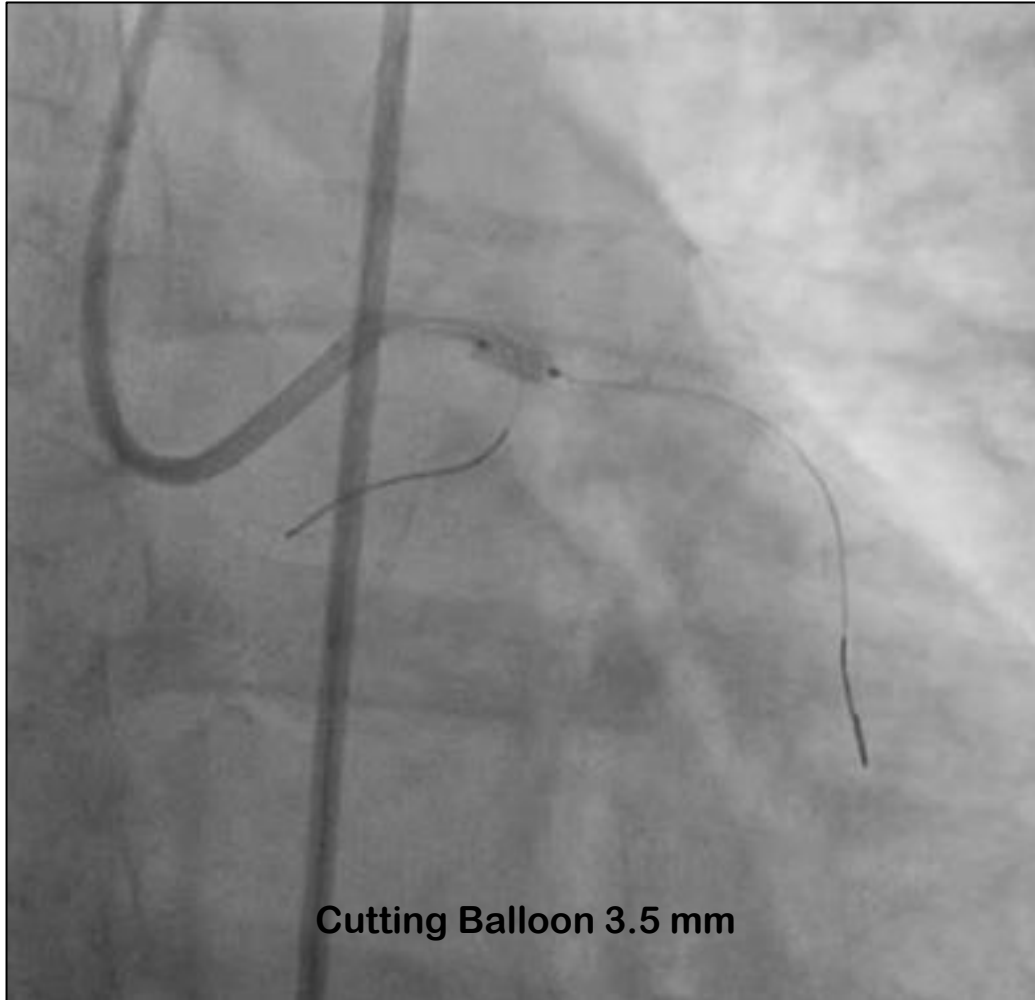
**CORONARIOGRAFÍA**  
**Masculino 64 años (hepatocarcinoma) con Angina Inestable progresiva**



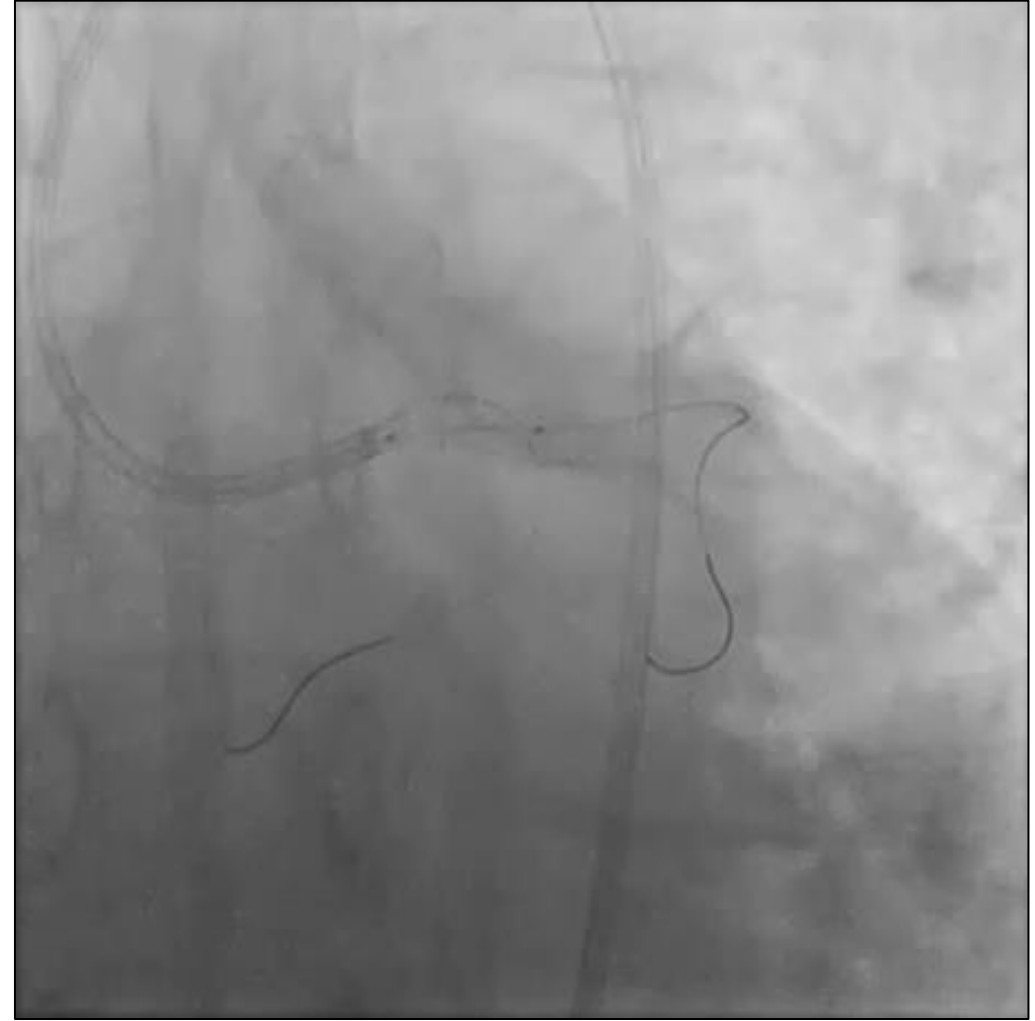
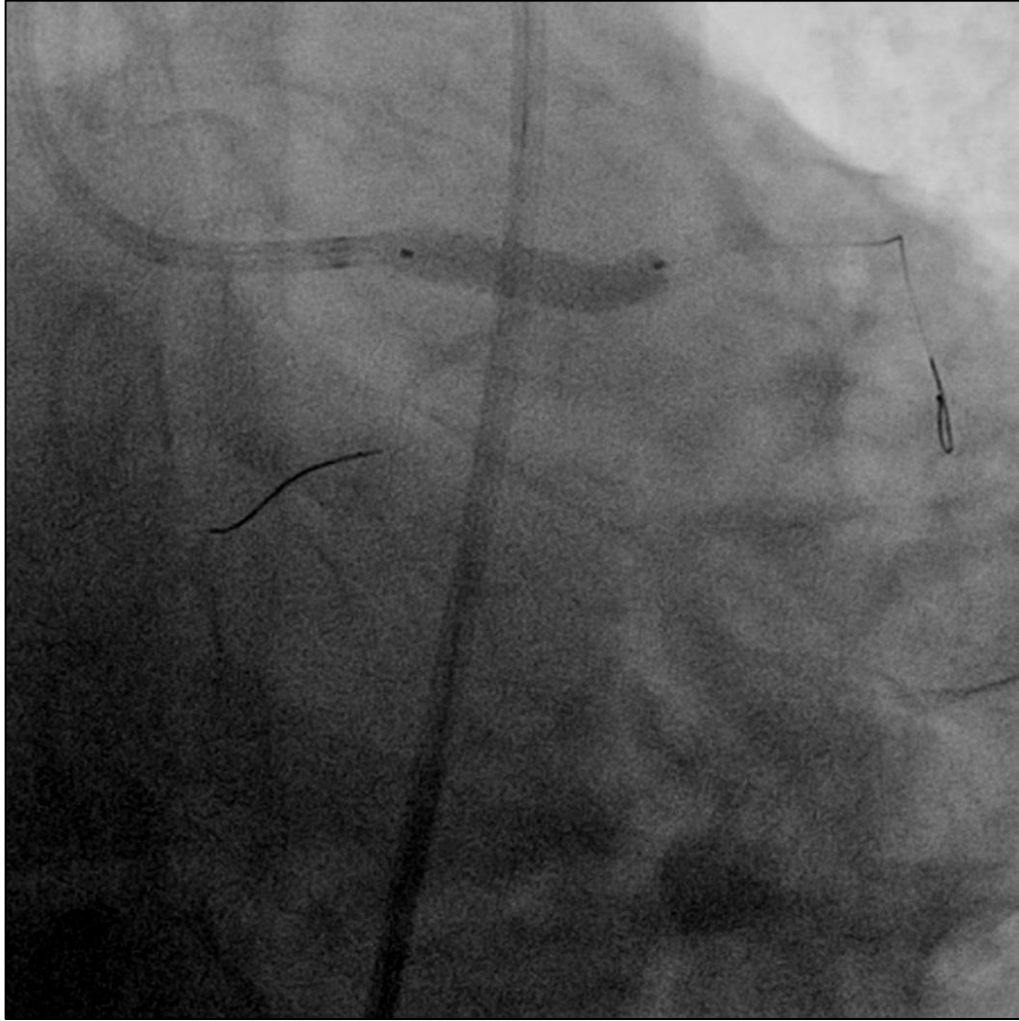
## ANGIOPLASTIA DEL TRONCO CORONARIO IZQUIERDO



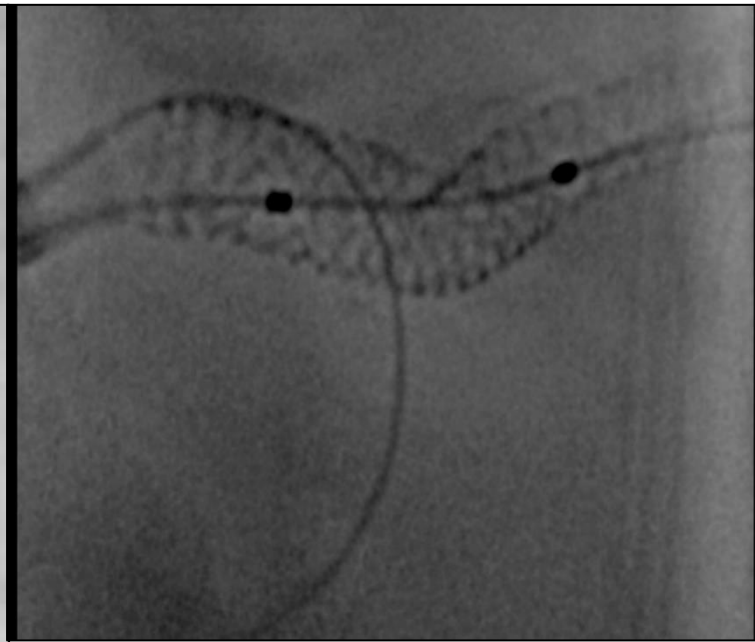
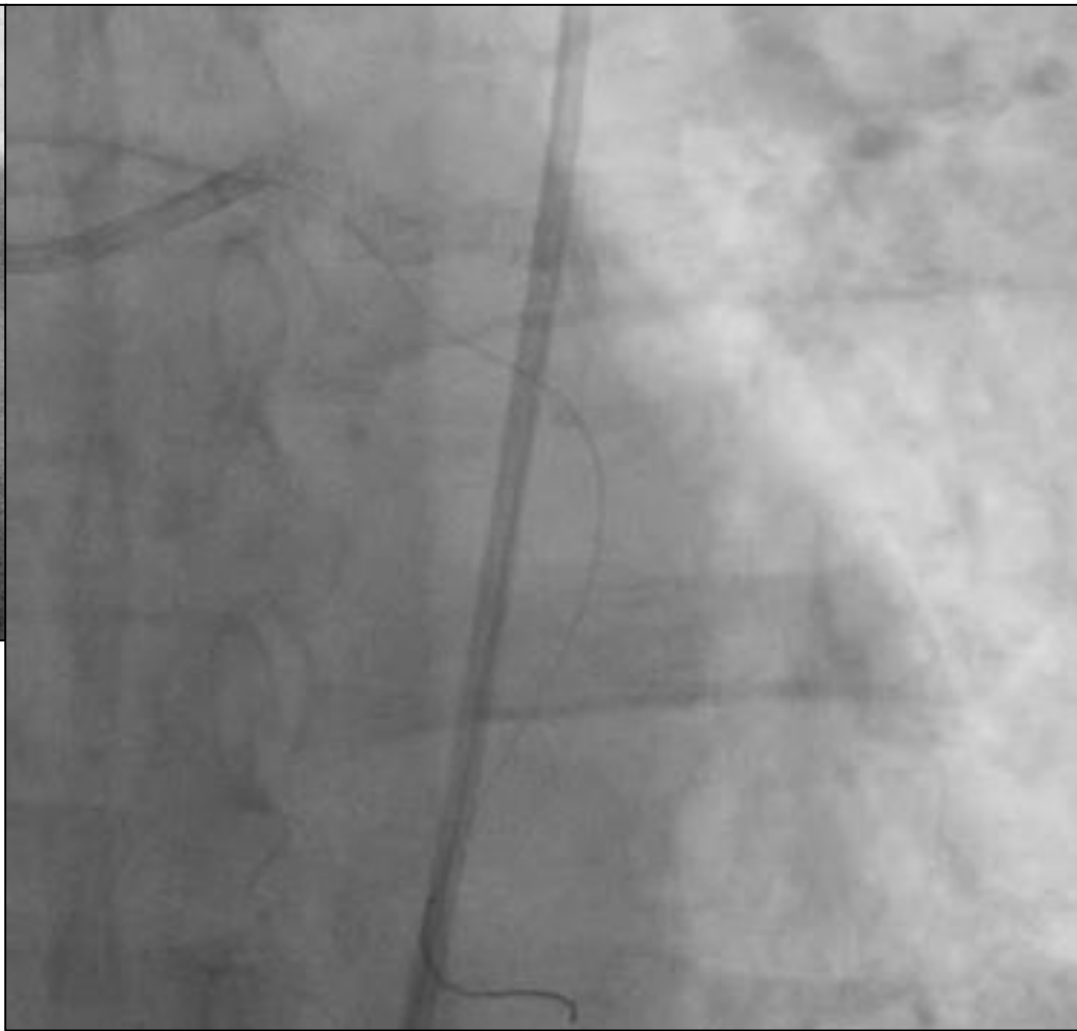
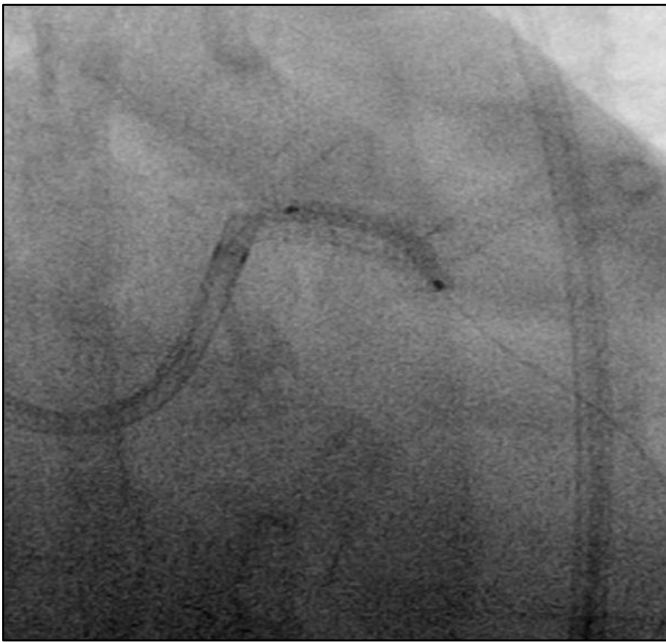
## ANGIOPLASTIA DEL TRONCO CORONARIO IZQUIERDO



## ANGIOPLASTIA DEL TRONCO CORONARIO IZQUIERDO

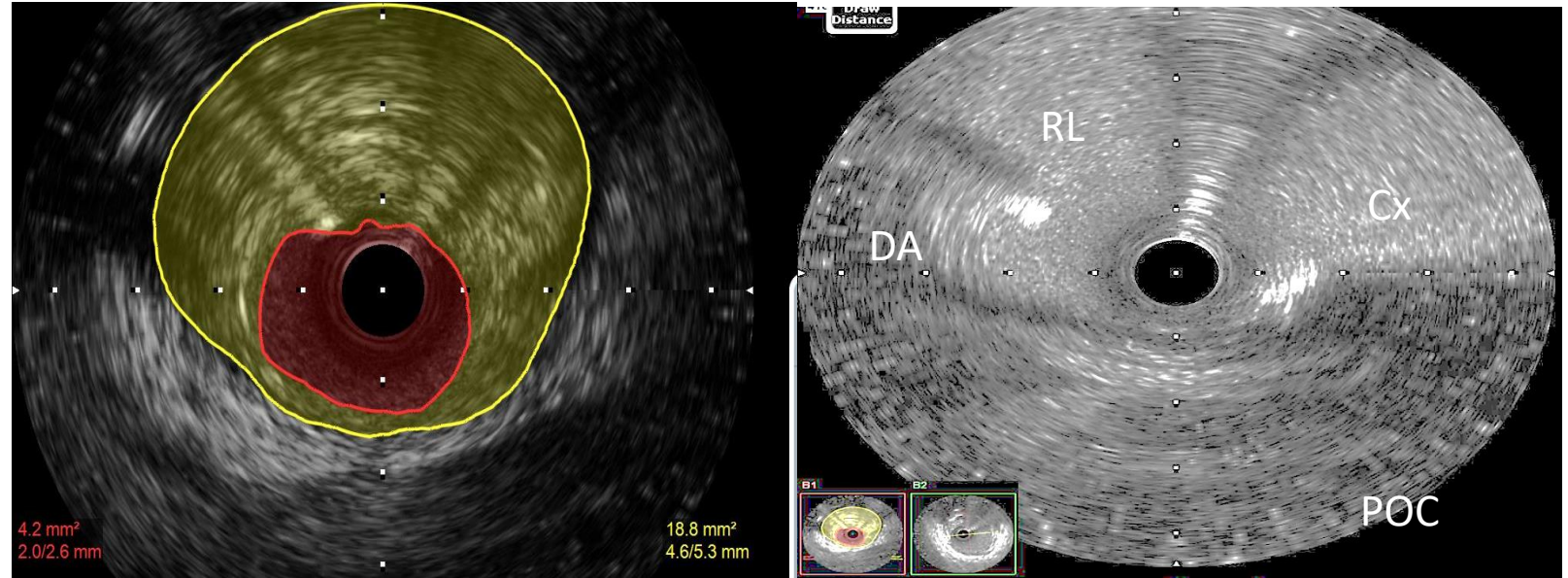


POT Balón 4.0 mm

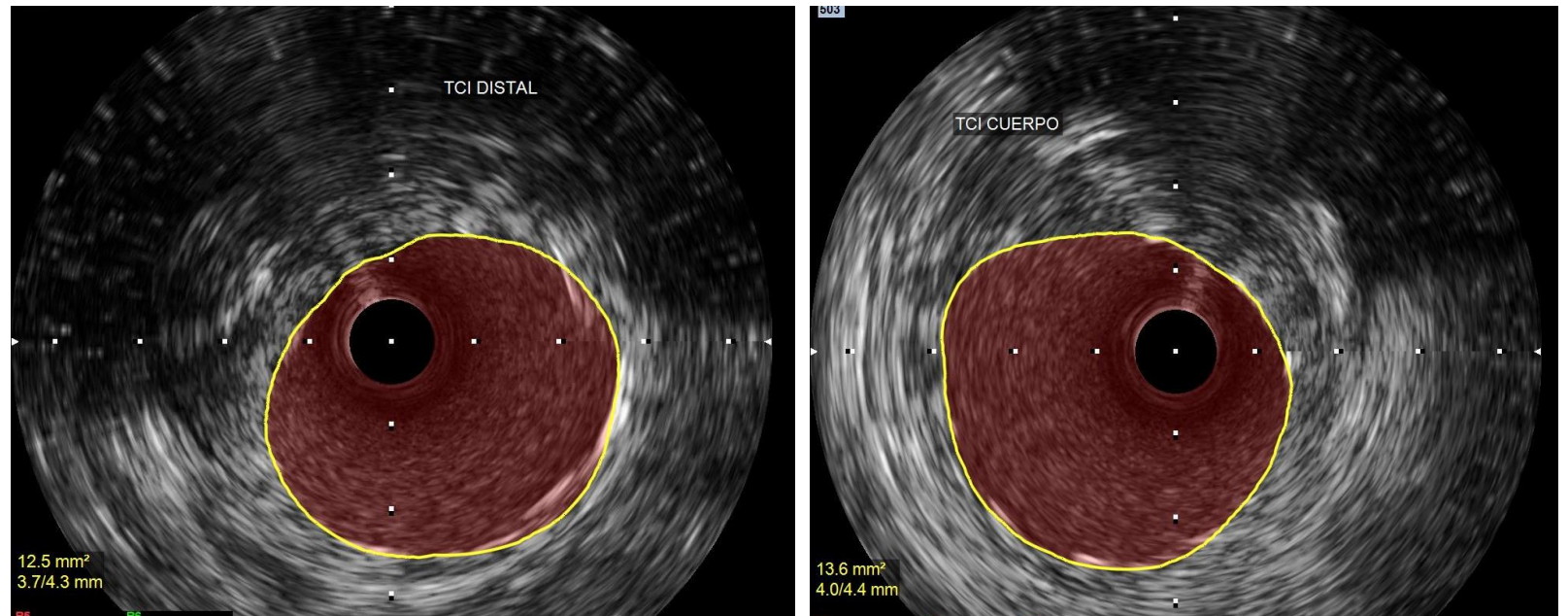


# ANGIOPLASTIA DEL TRONCO CORONARIO IZQUIERDO

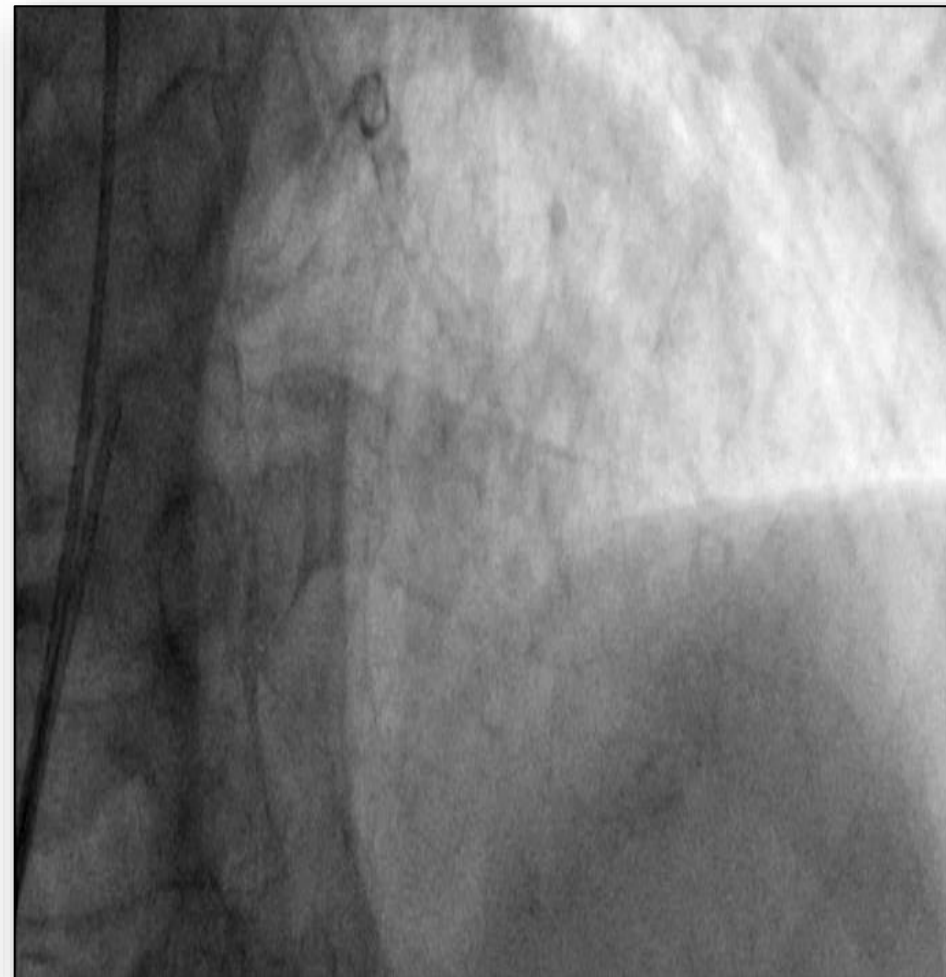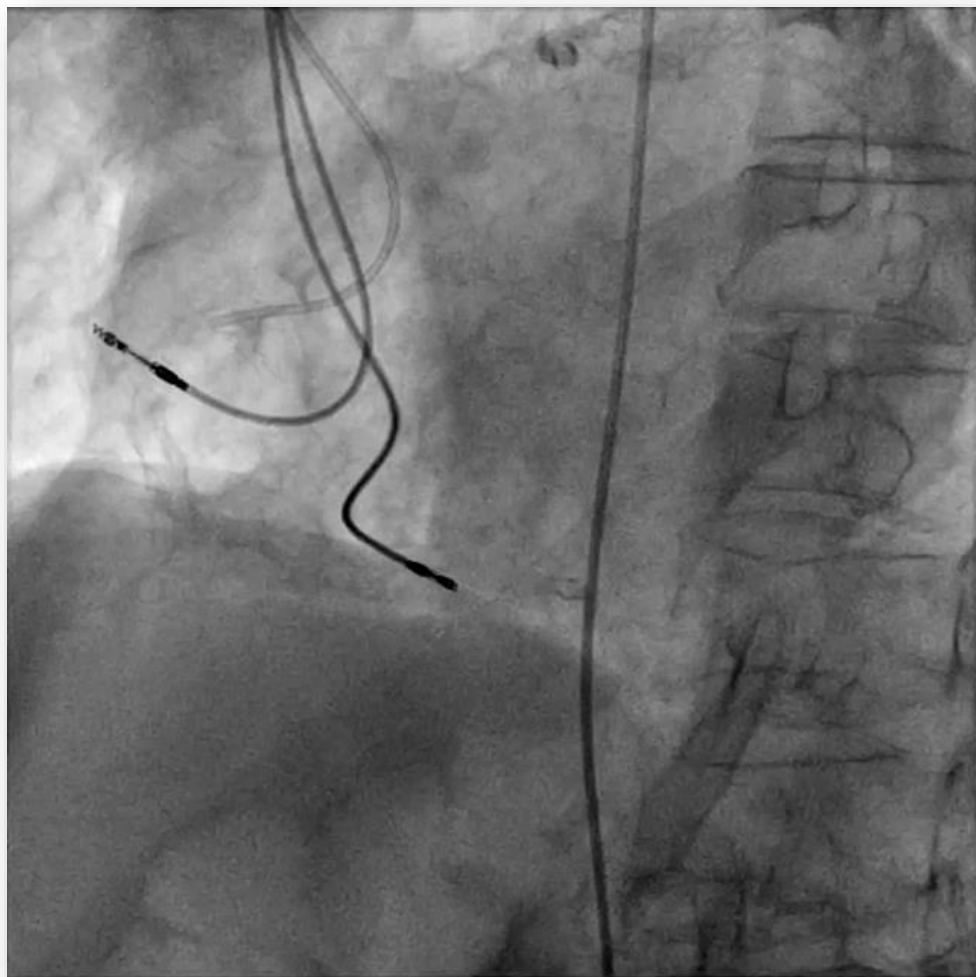
IVUS PRE



IVUS POST



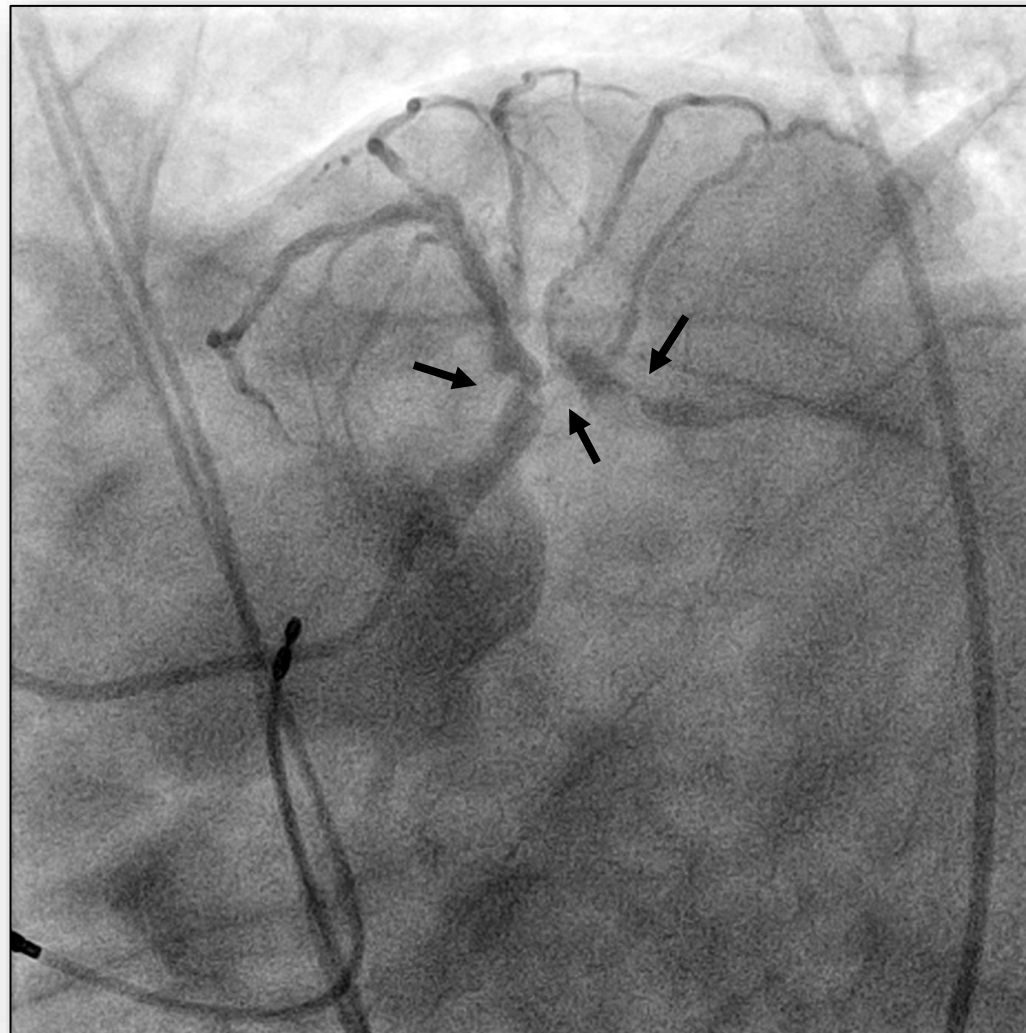
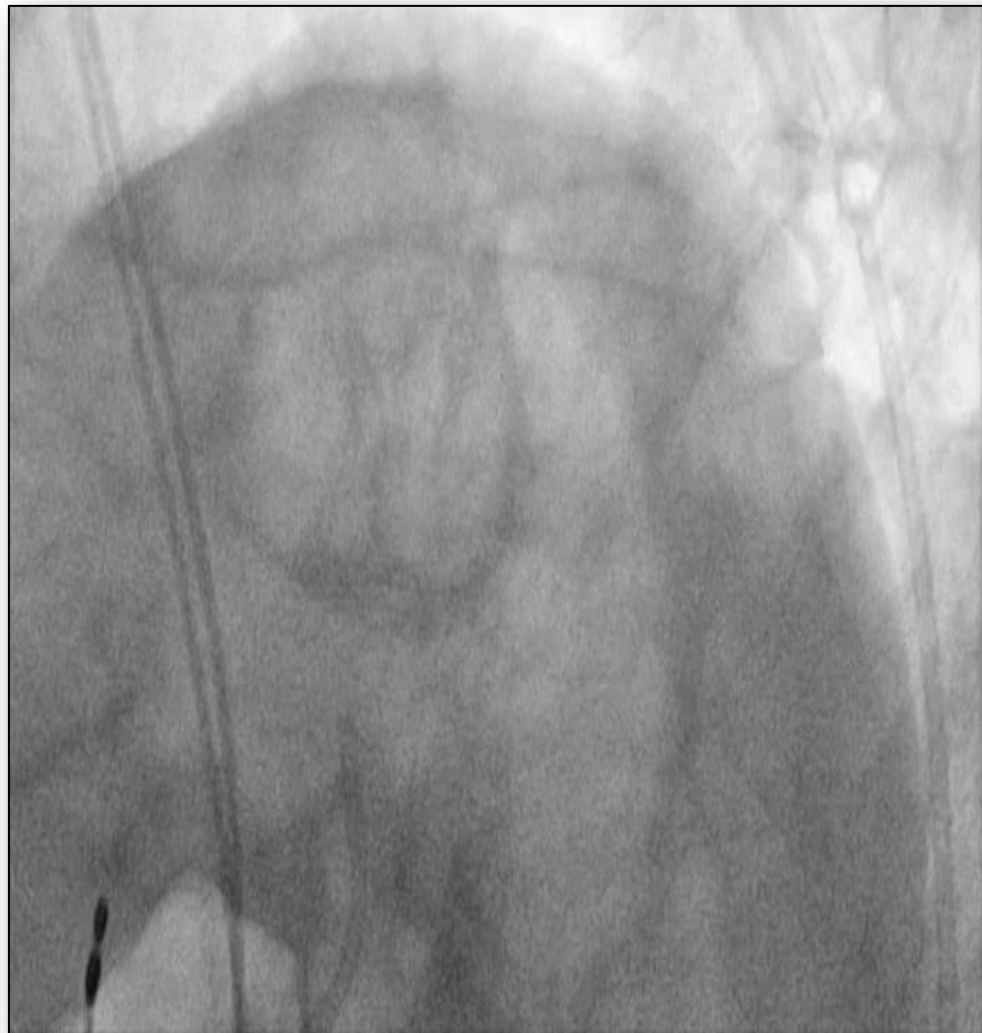**CORONARIOGRAFÍA**  
**Masculino 84 años con Angina Inestable de alto riesgo CF IV**



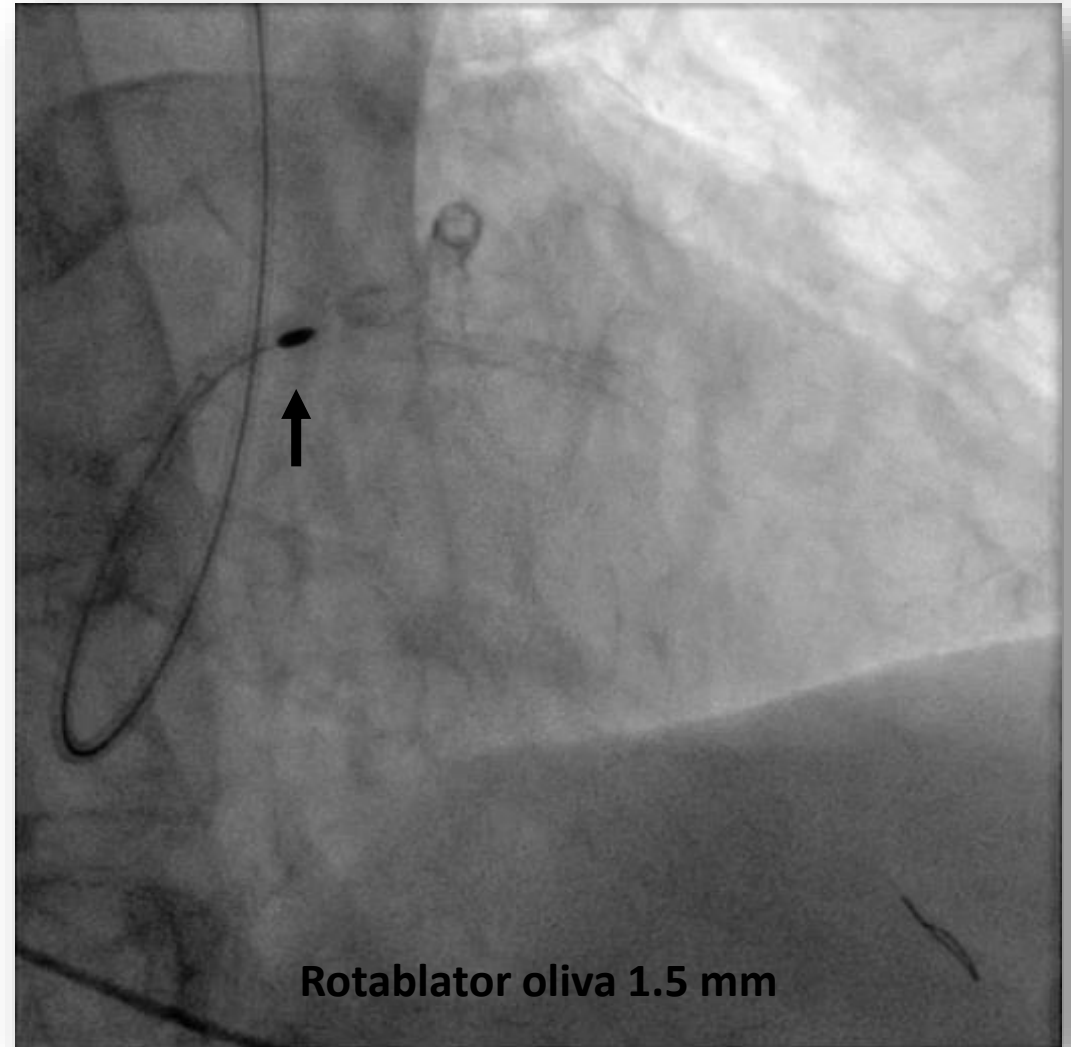
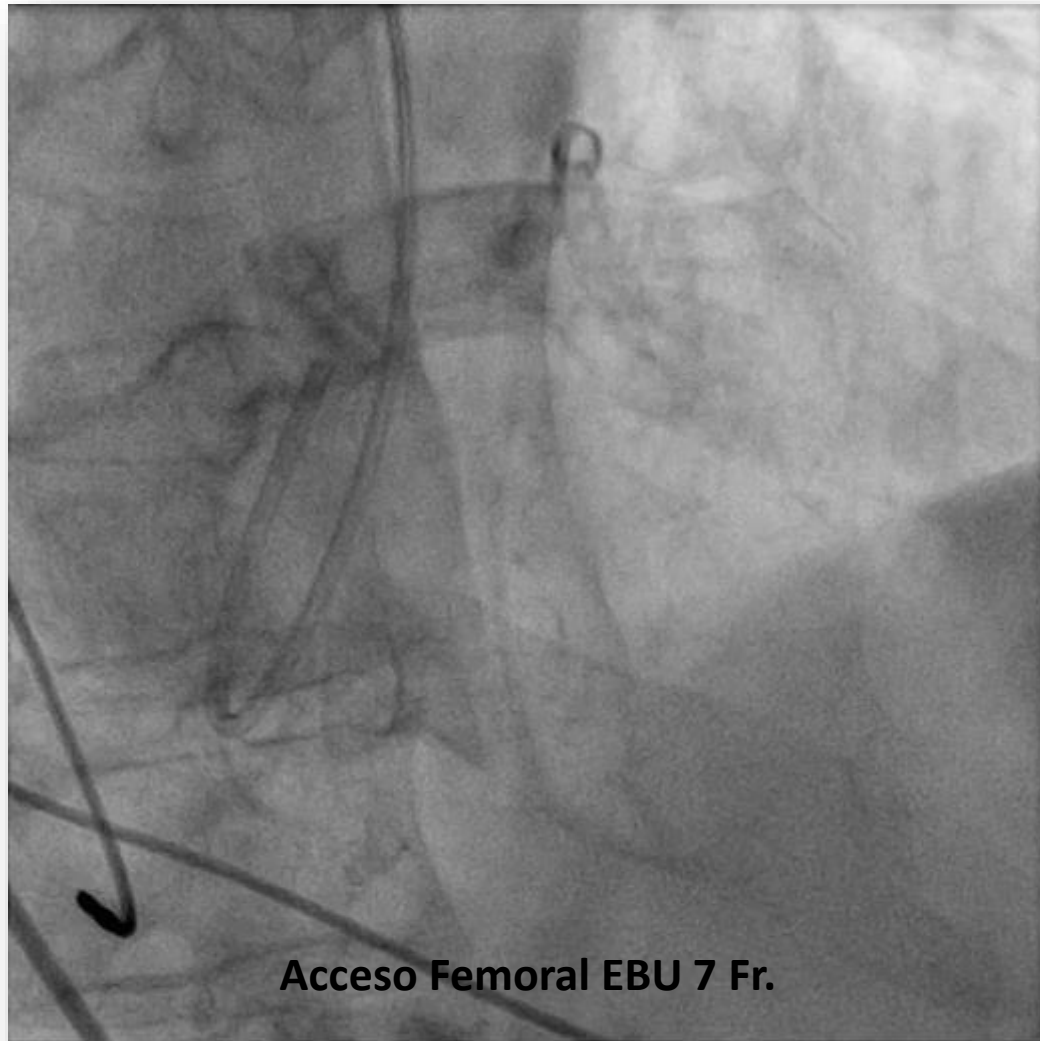




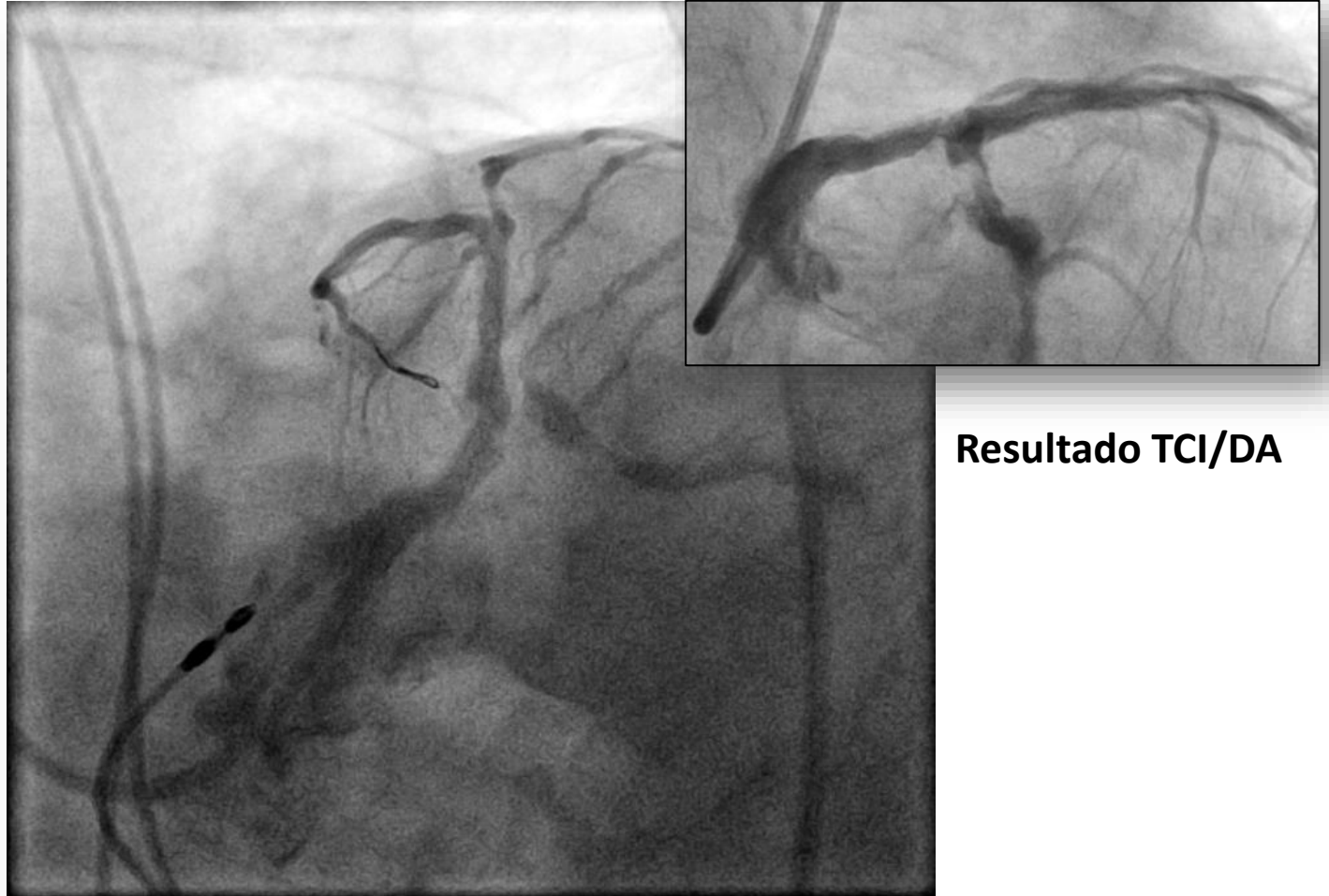
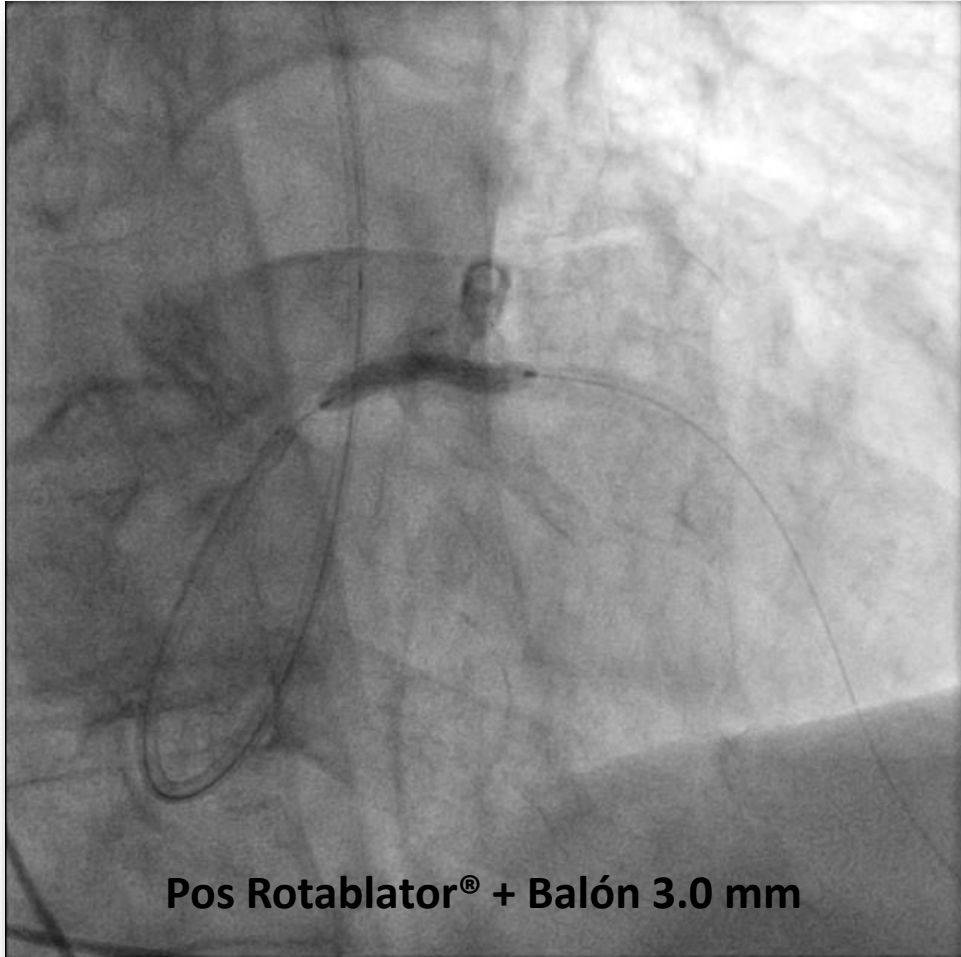
## ANGIOPLASTIA DEL TRONCO CORONARIO IZQUIERDO



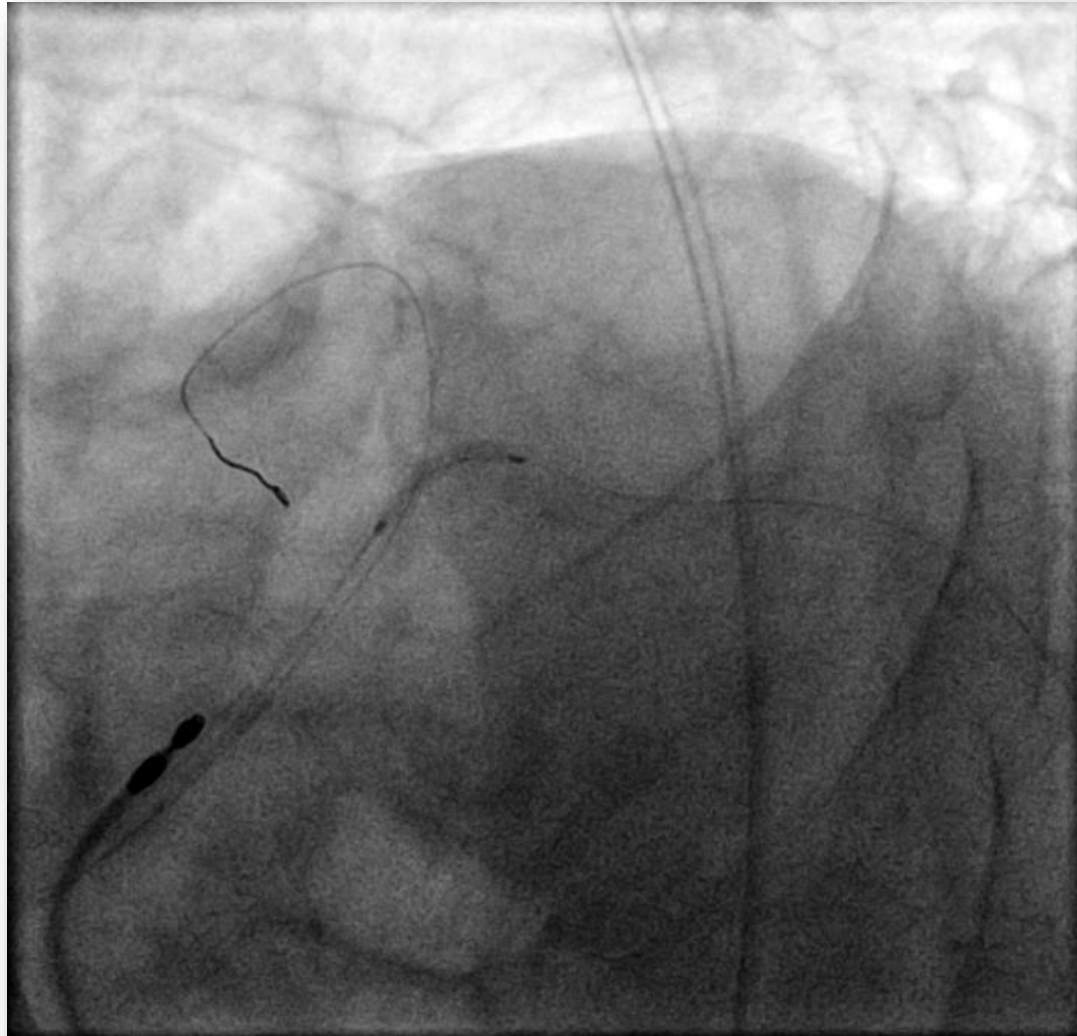
# ANGIOPLASTIA DEL TRONCO CORONARIO IZQUIERDO



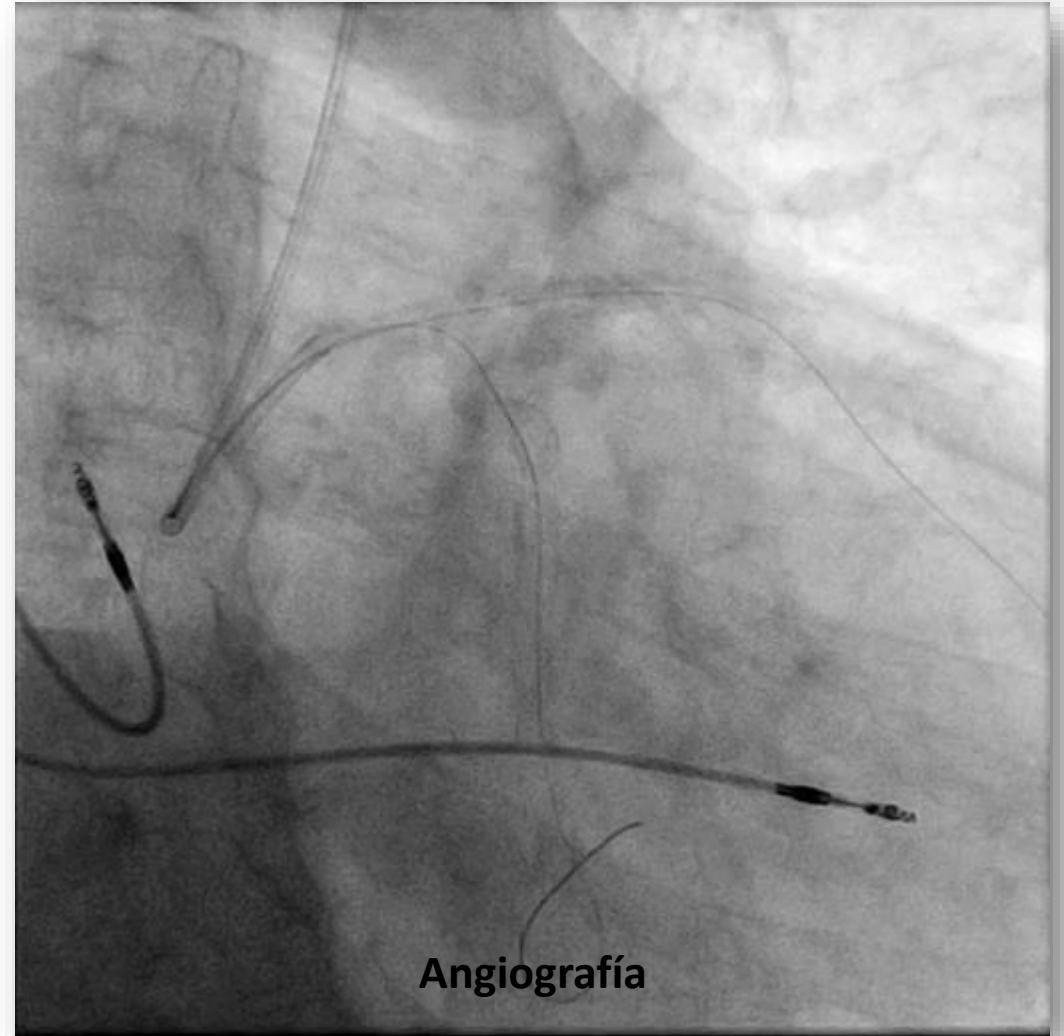
# ANGIOPLASTIA DEL TRONCO CORONARIO IZQUIERDO



## ANGIOPLASTIA DEL TRONCO CORONARIO IZQUIERDO

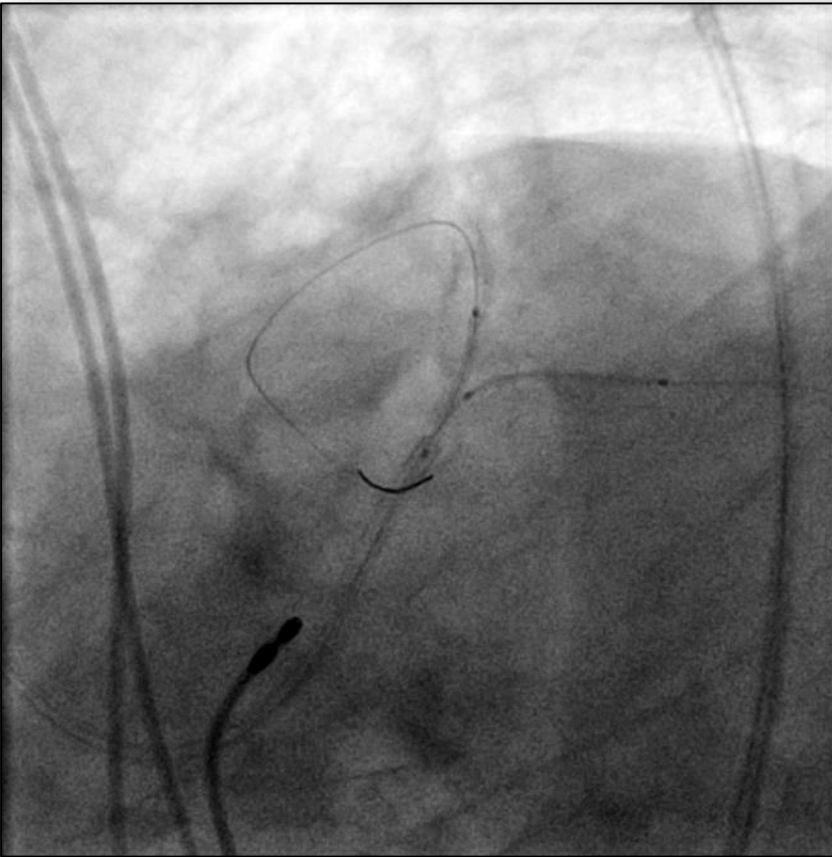


Balón 3.0 mm Cx

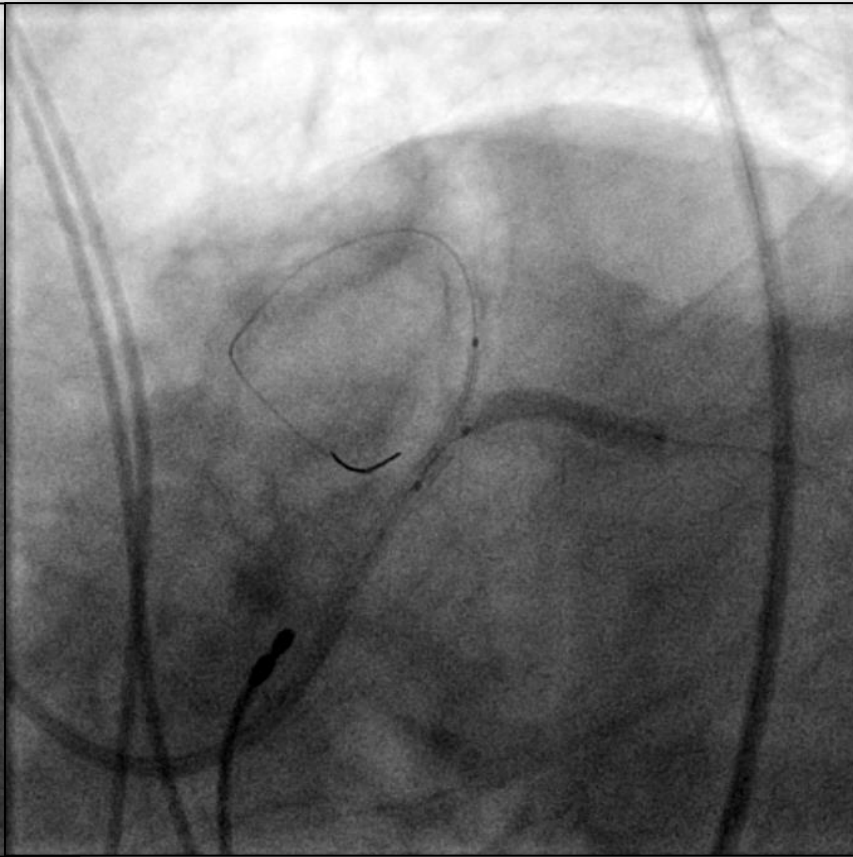


Angiografía

# ANGIOPLASTIA DEL TRONCO CORONARIO IZQUIERDO

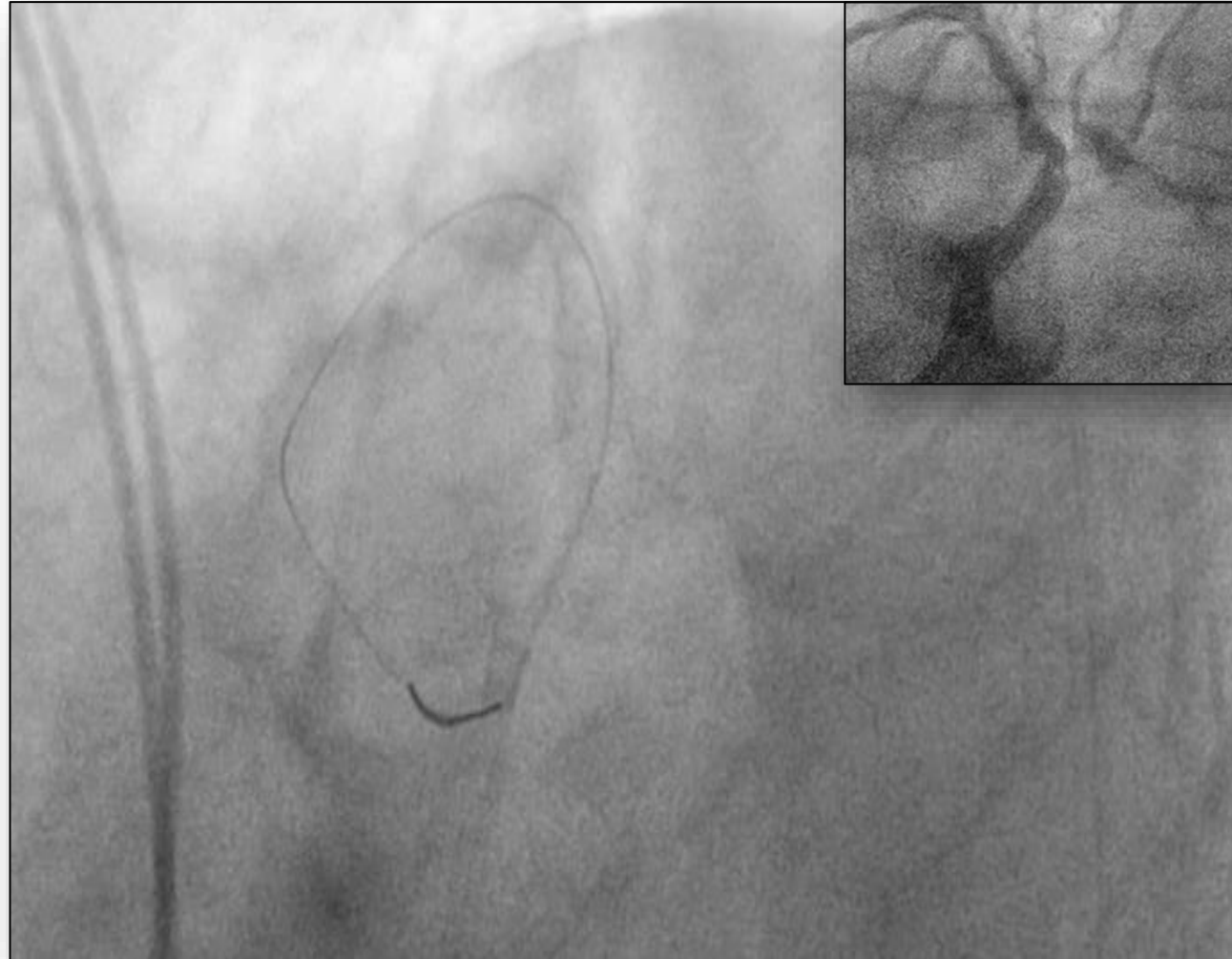


T-CRUSH



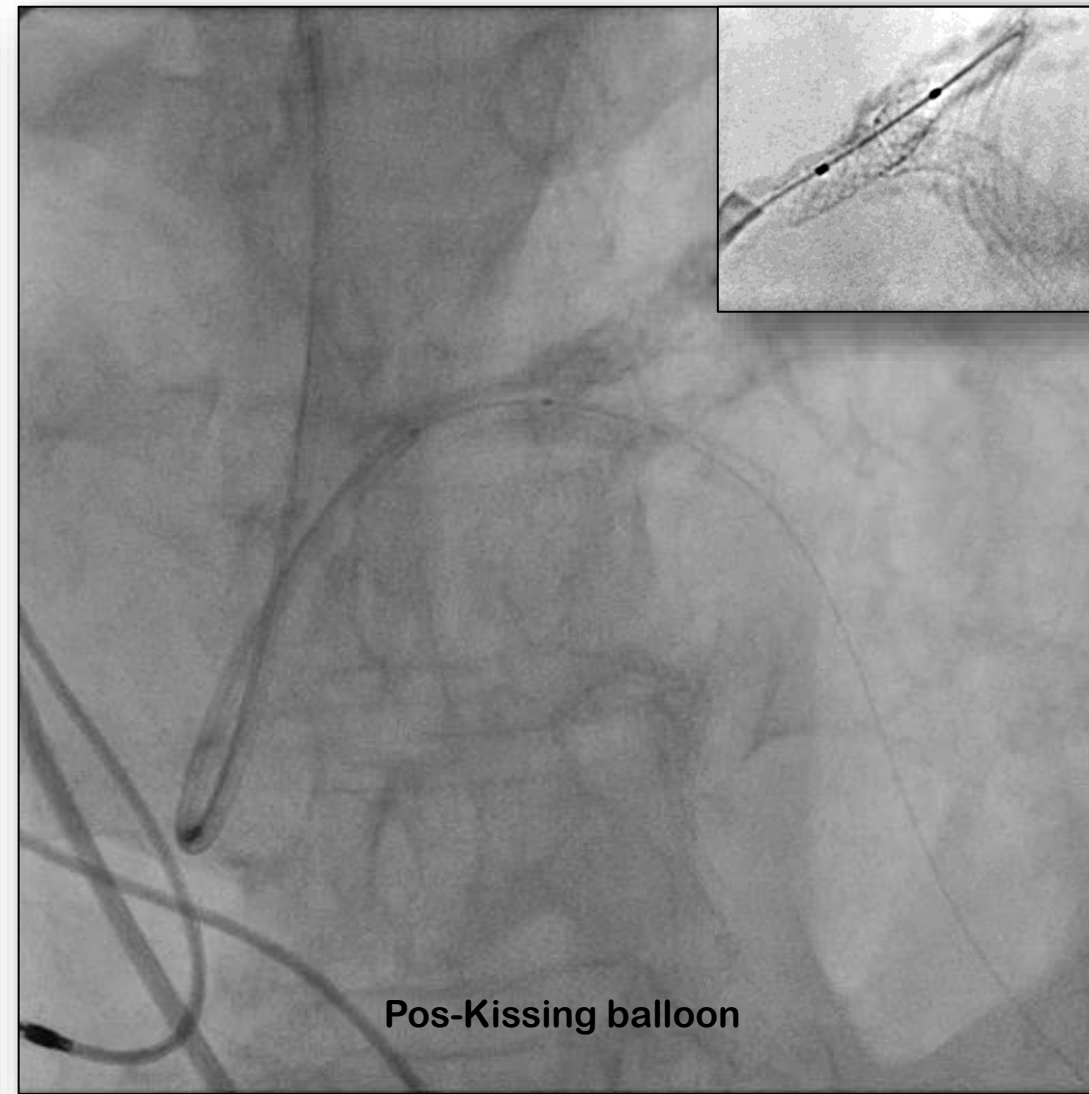
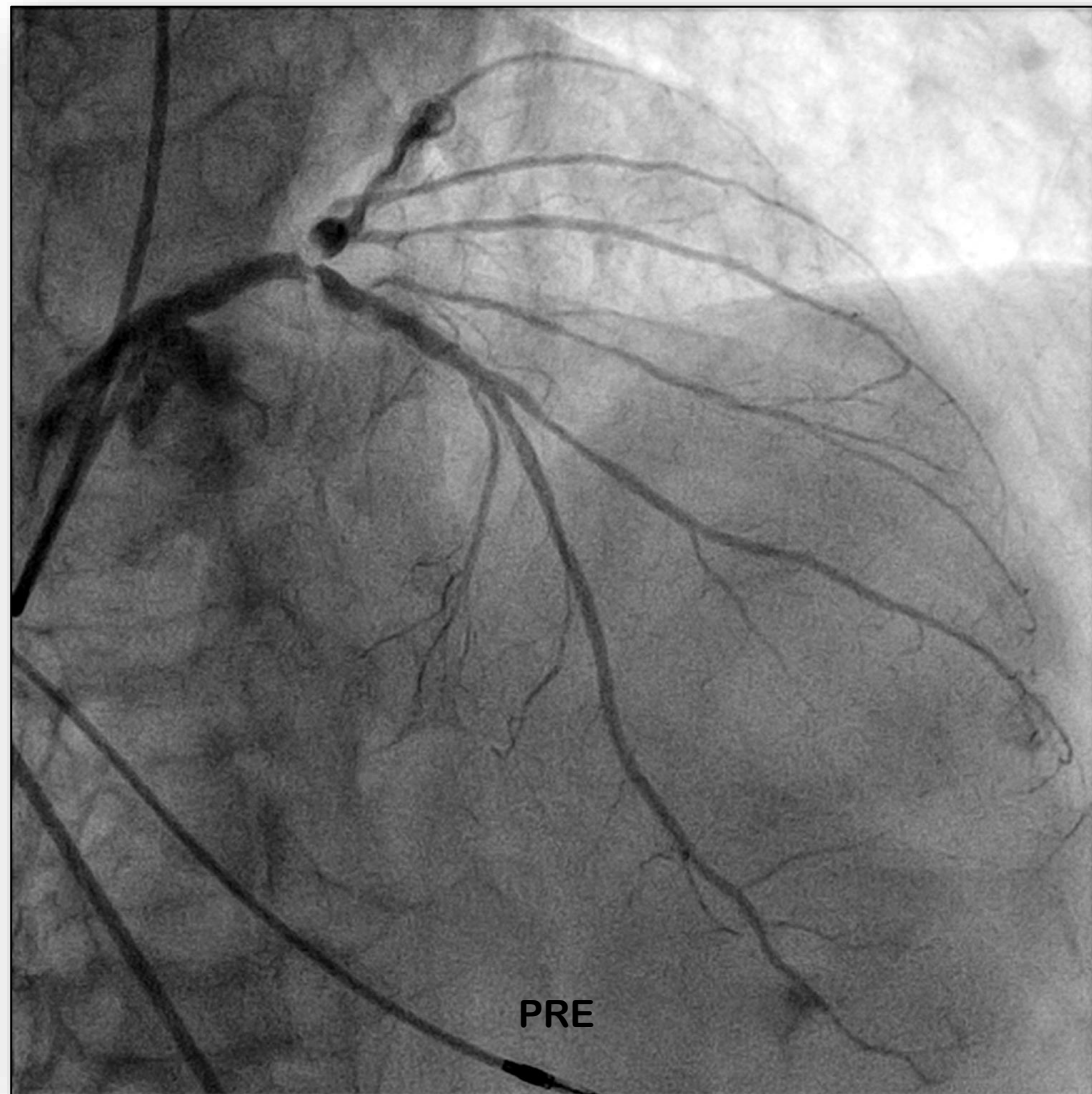
CRUSH

# ANGIOPLASTIA DEL TRONCO CORONARIO IZQUIERDO





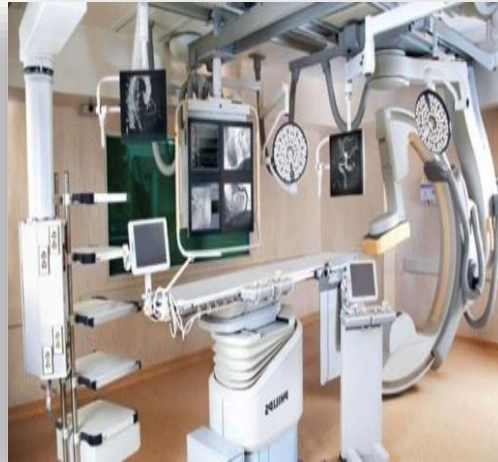## ANGIOPLASTIA DEL TRONCO CORONARIO IZQUIERDO



### *“Mensajes para llevar a casa”*

- 1) Aquellos Cardiólogos Intervencionistas con sólida experiencia en ATC (no TCI) adquirirán en un breve período formación en el tratamiento del Tronco.
- 2) Trabajar ordenadamente planificando como orientaremos cada intervención teniendo presentes eventuales complicaciones resulta básico.
- 3) Nuestros resultados, en terreno, a pesar de que frecuentemente no contamos con todos los materiales que quisiéramos, resultan similares si trabajamos con sentido común, formación clínica y formación técnica.





**GRACIAS**