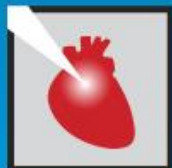



Incorrecto implante de stent en bifurcación y sus consecuencias



JORNADAS CIENTÍFICAS Y GREMIALES CACI 2021
4 Y 5 DE DICIEMBRE 2021 . HOTEL HILTON - PRESENCIAL



Cuadro clínico

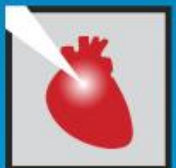

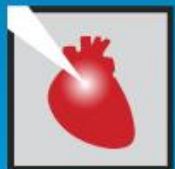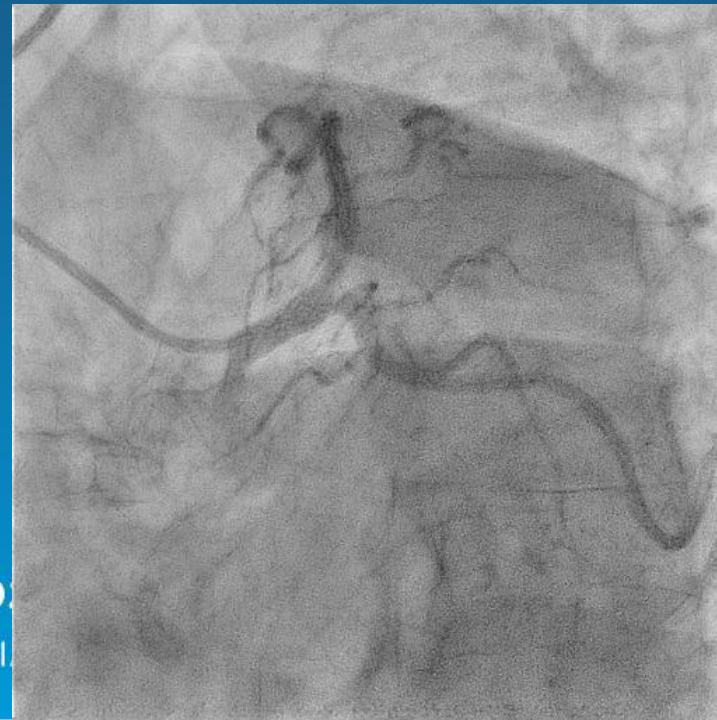

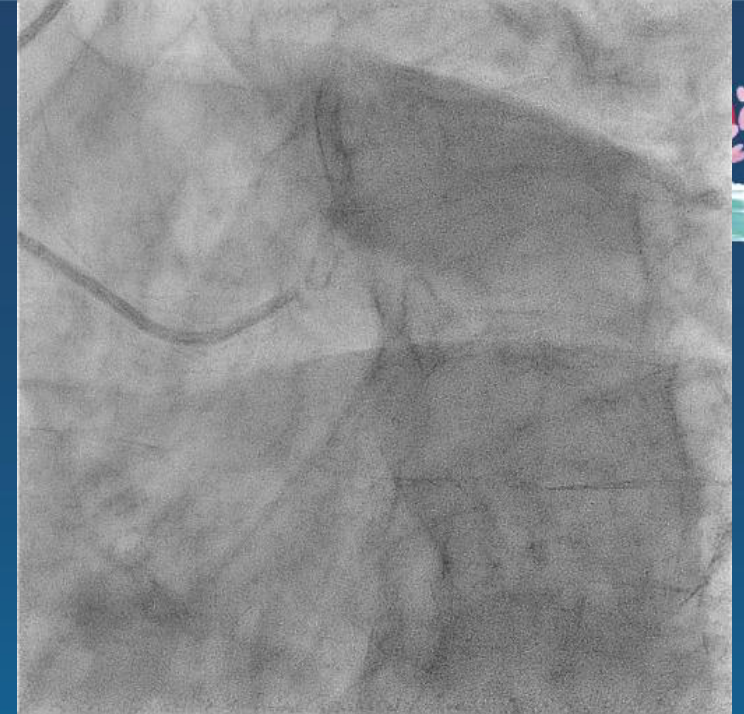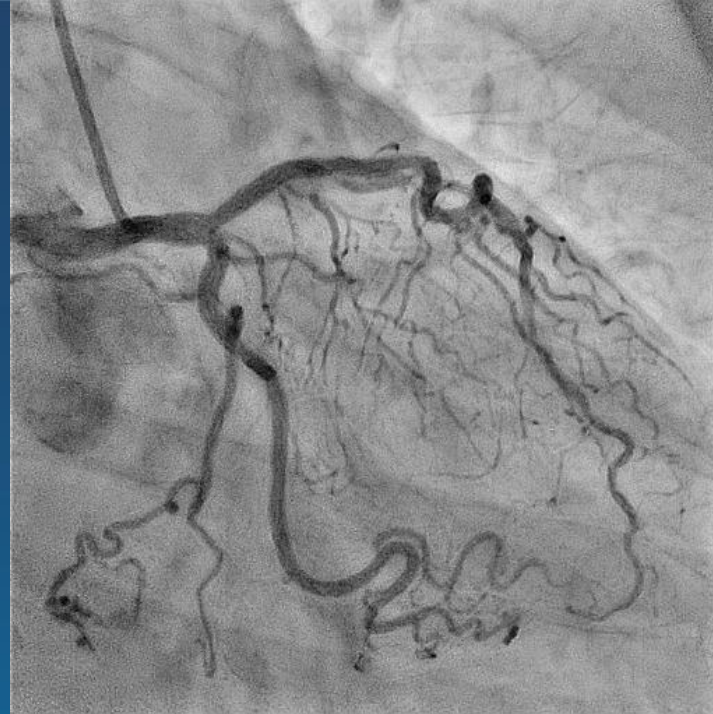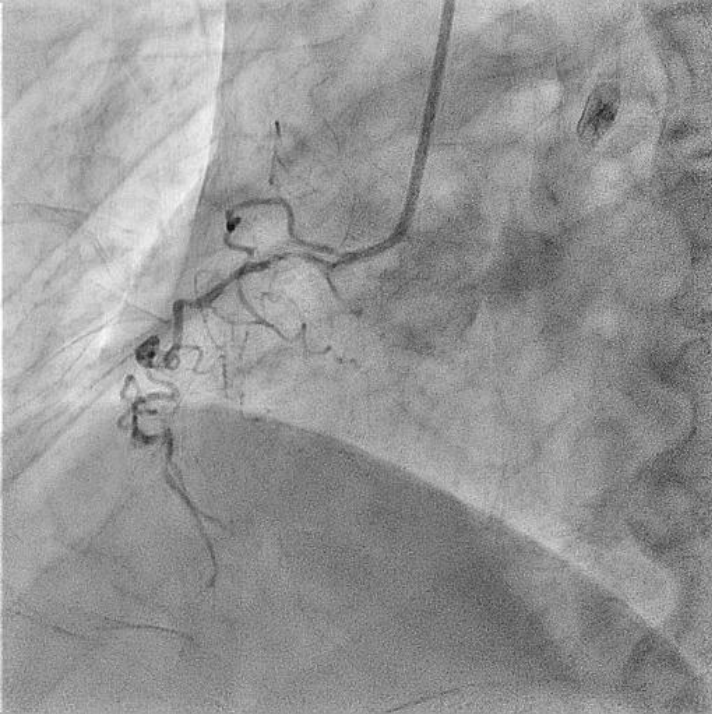
Femenina 70 años
FR: HTA, DLP, Ex TBQ,

Antecedentes cardiovasculares

- IAMSEST se decide TMO (2010)
- Angioplastia a circunfleja y descendente anterior por Sme coronario crónico (11/2018).

Angor CF III e isquemia inferior e inferolateral en cámara gama



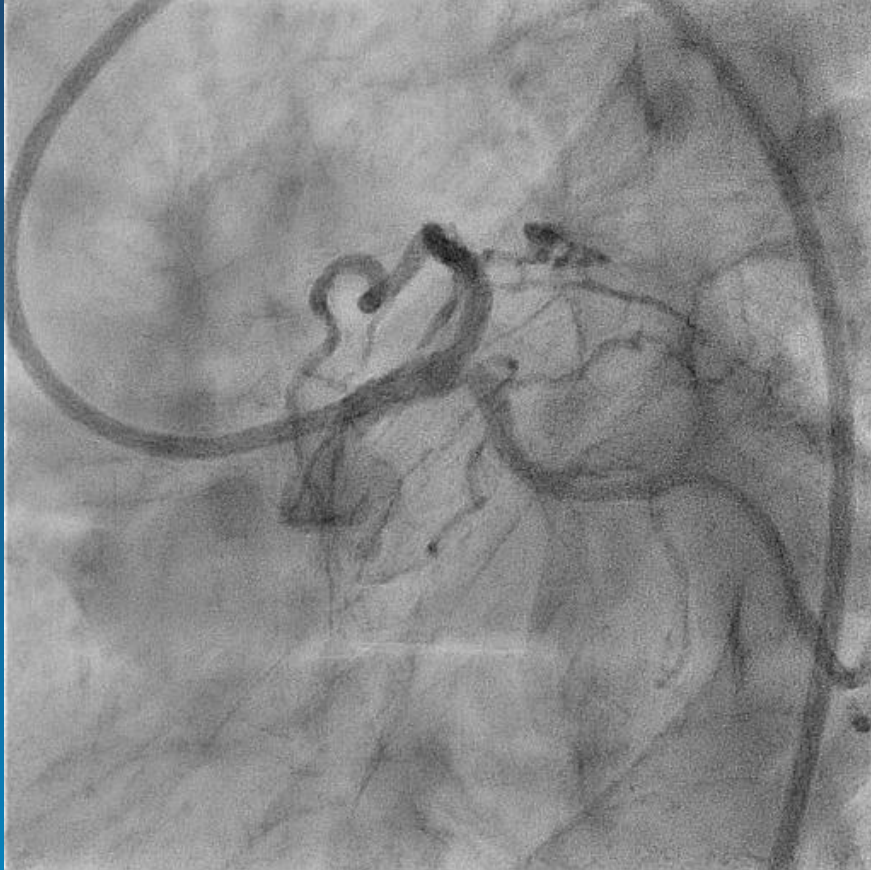


JORNA
4 Y 5 DE

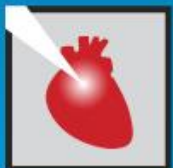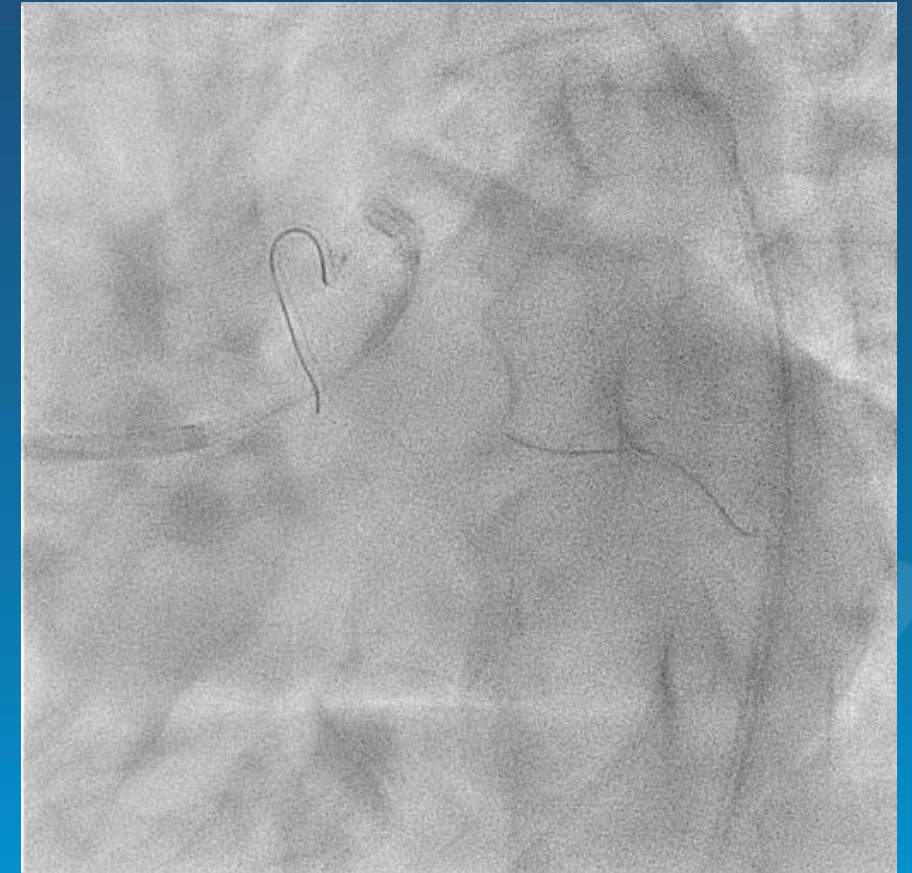
CACI 20
PRESENCI



Angioplastia TCI-DA-CX

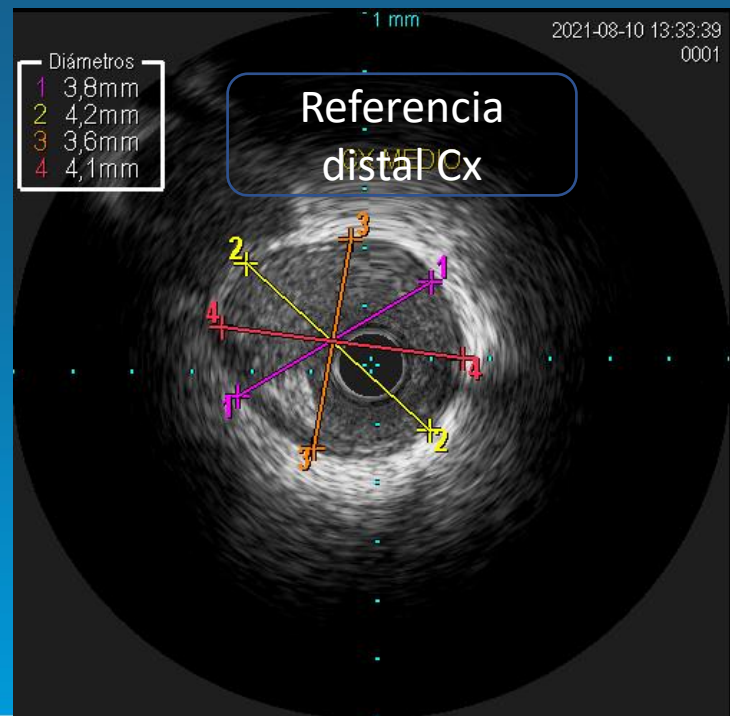
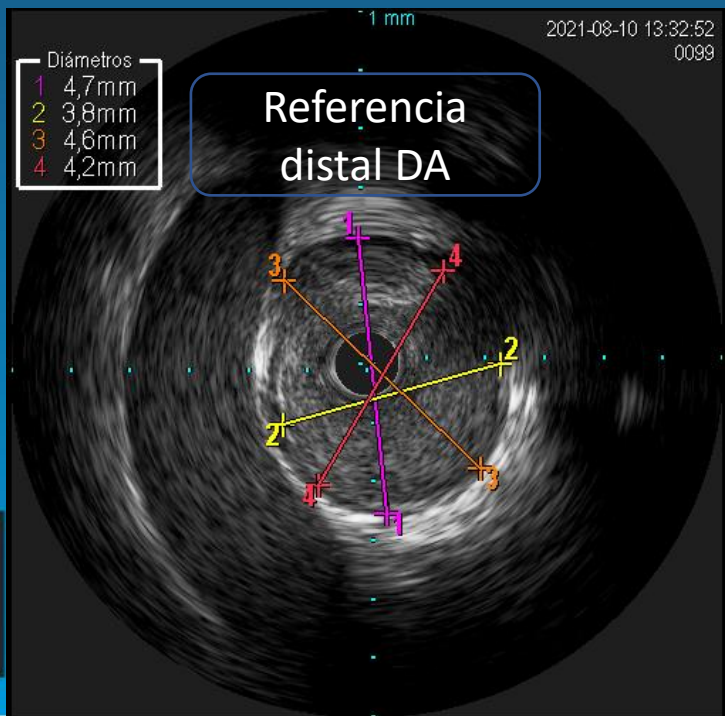
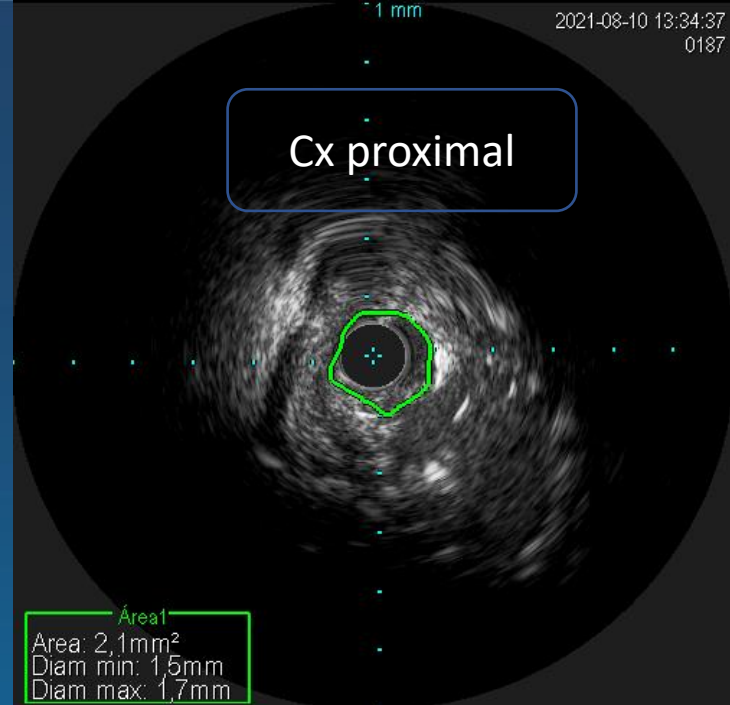
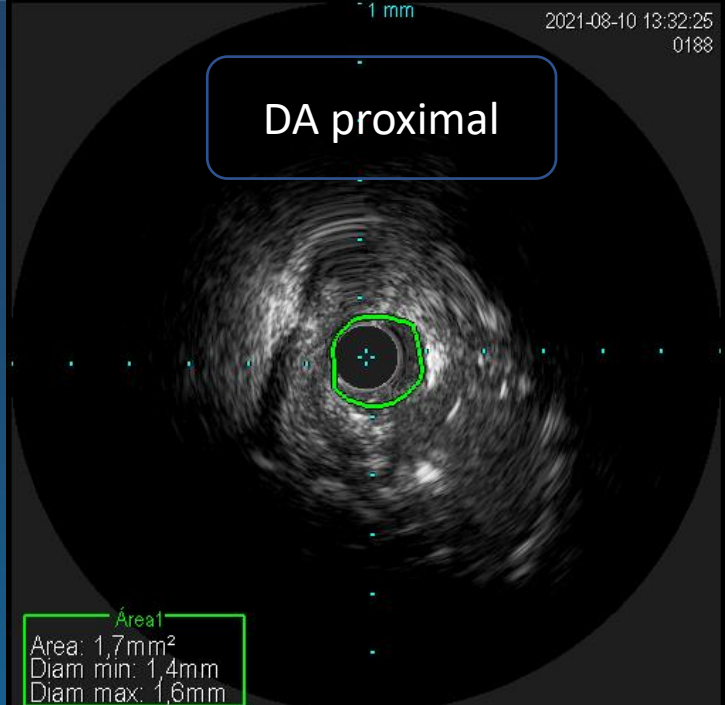


Acceso femoral 7 Fr
Guías BMW
IVUS

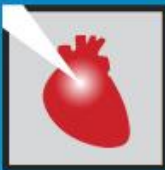

JORNADAS CIENTÍFICAS Y GREIALES CACI 2021
4 Y 5 DE DICIEMBRE 2021 . HOTEL HILTON - PRESENCIAL

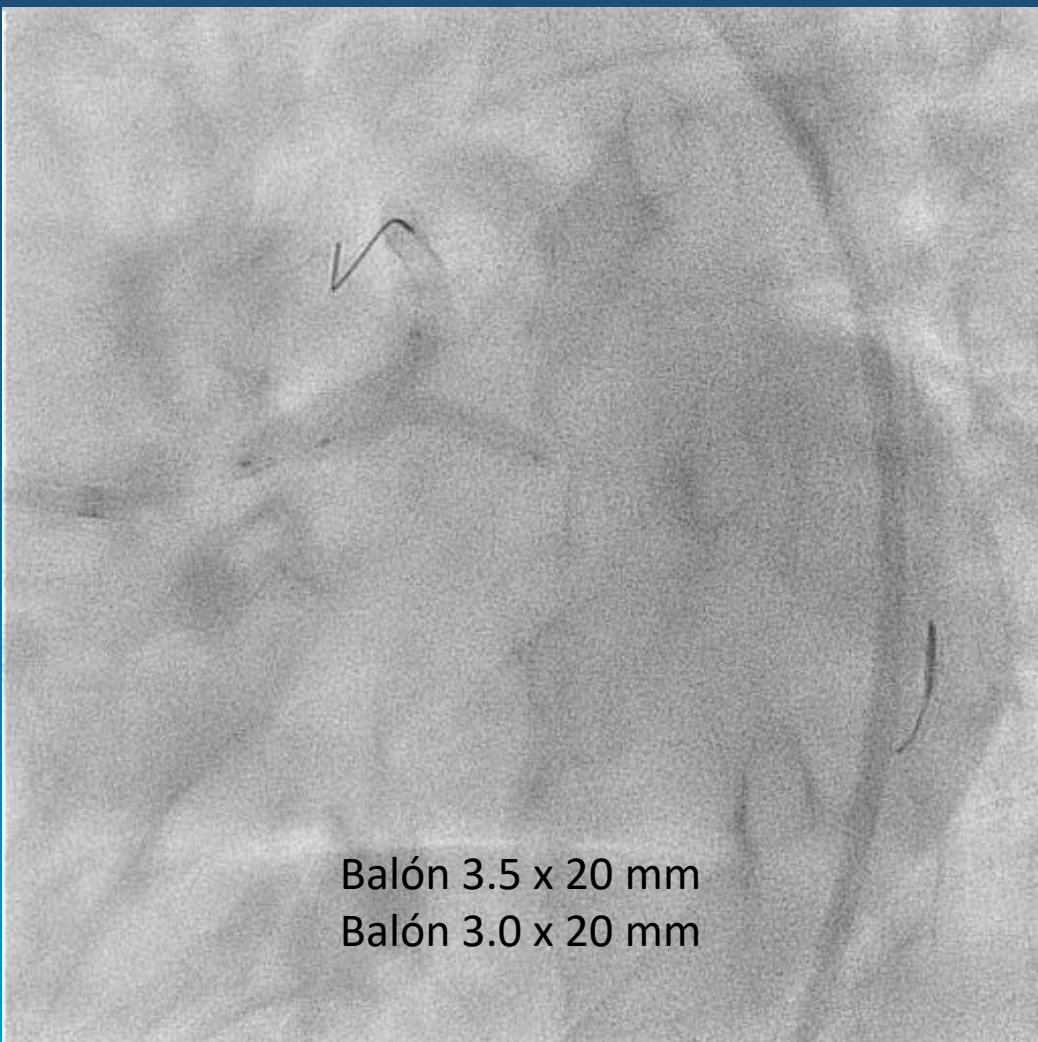
IVUS



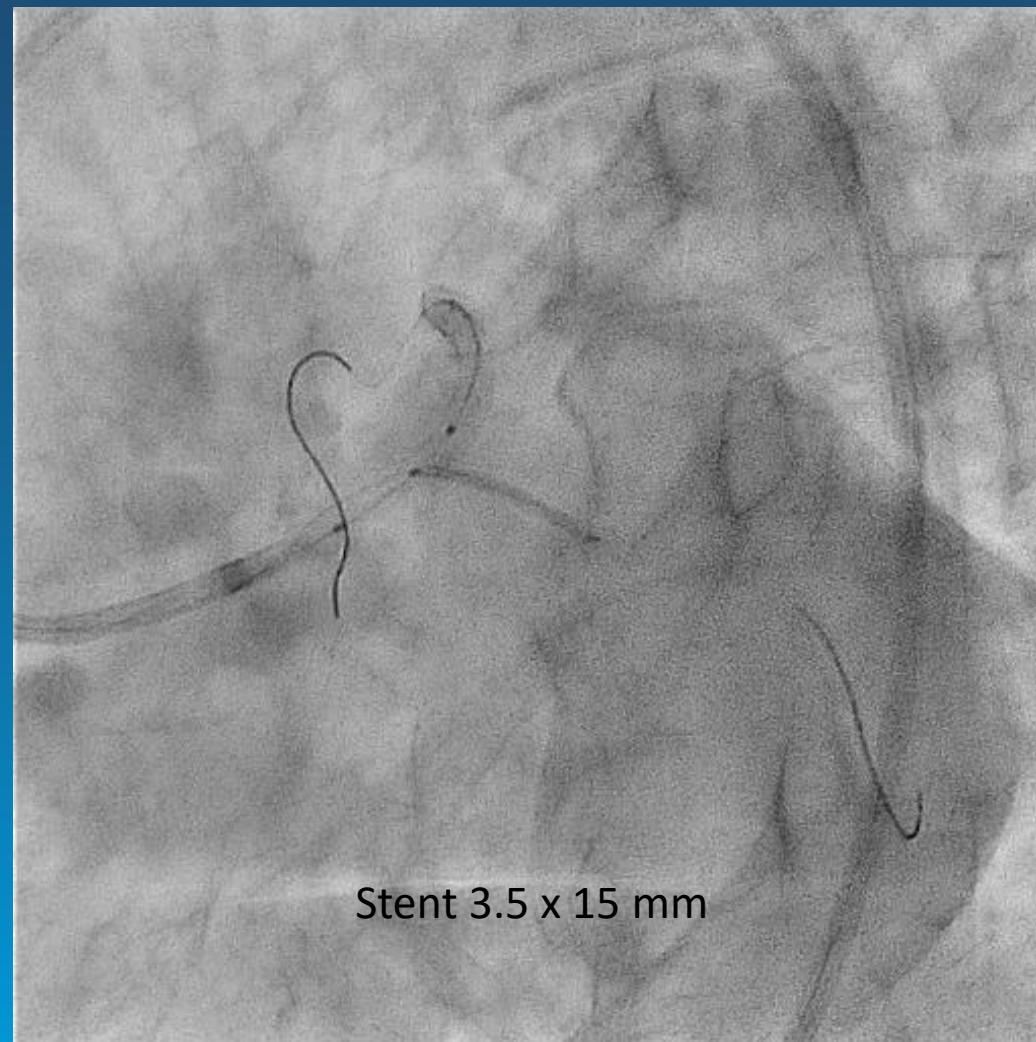
MIALES CACI 2021
MILTON - PRESENCIAL



1er Kissing Balloon y stent a Cx

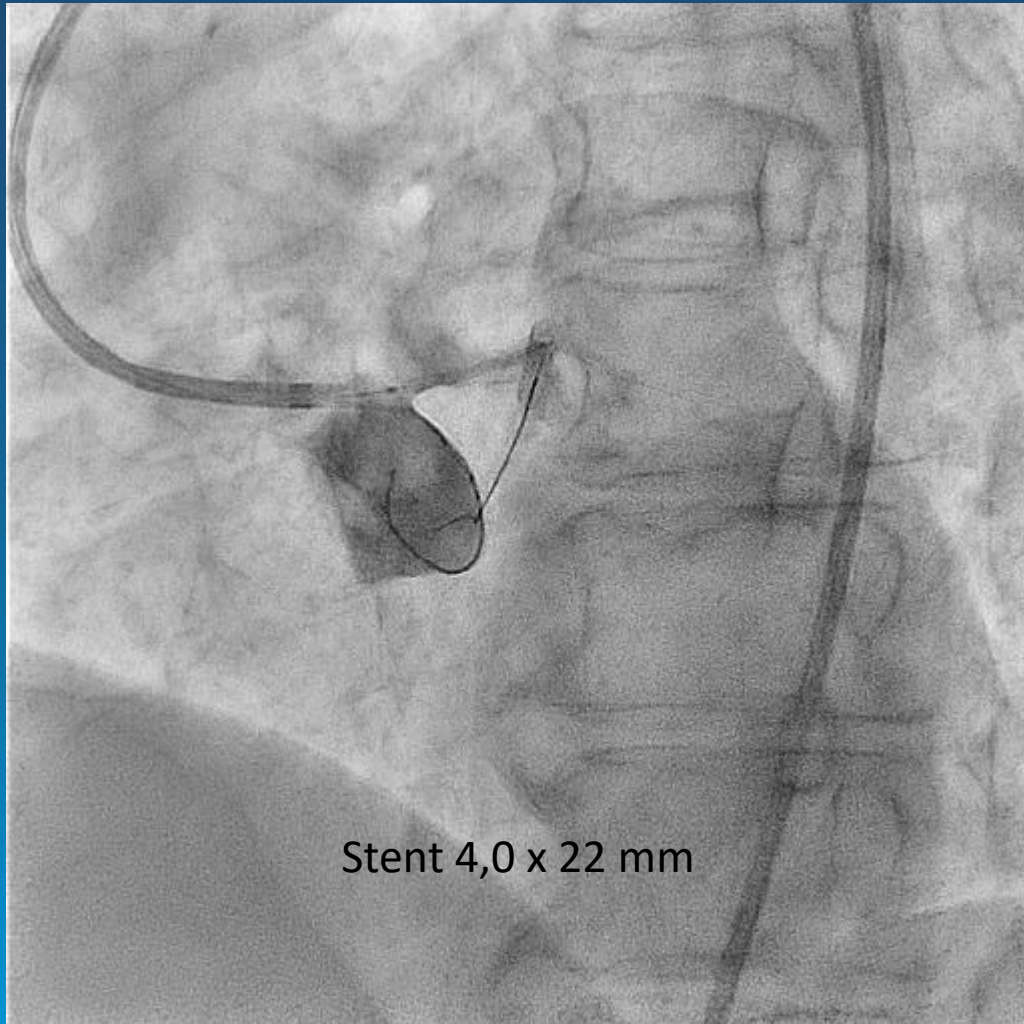


Balón 3.5 x 20 mm
Balón 3.0 x 20 mm

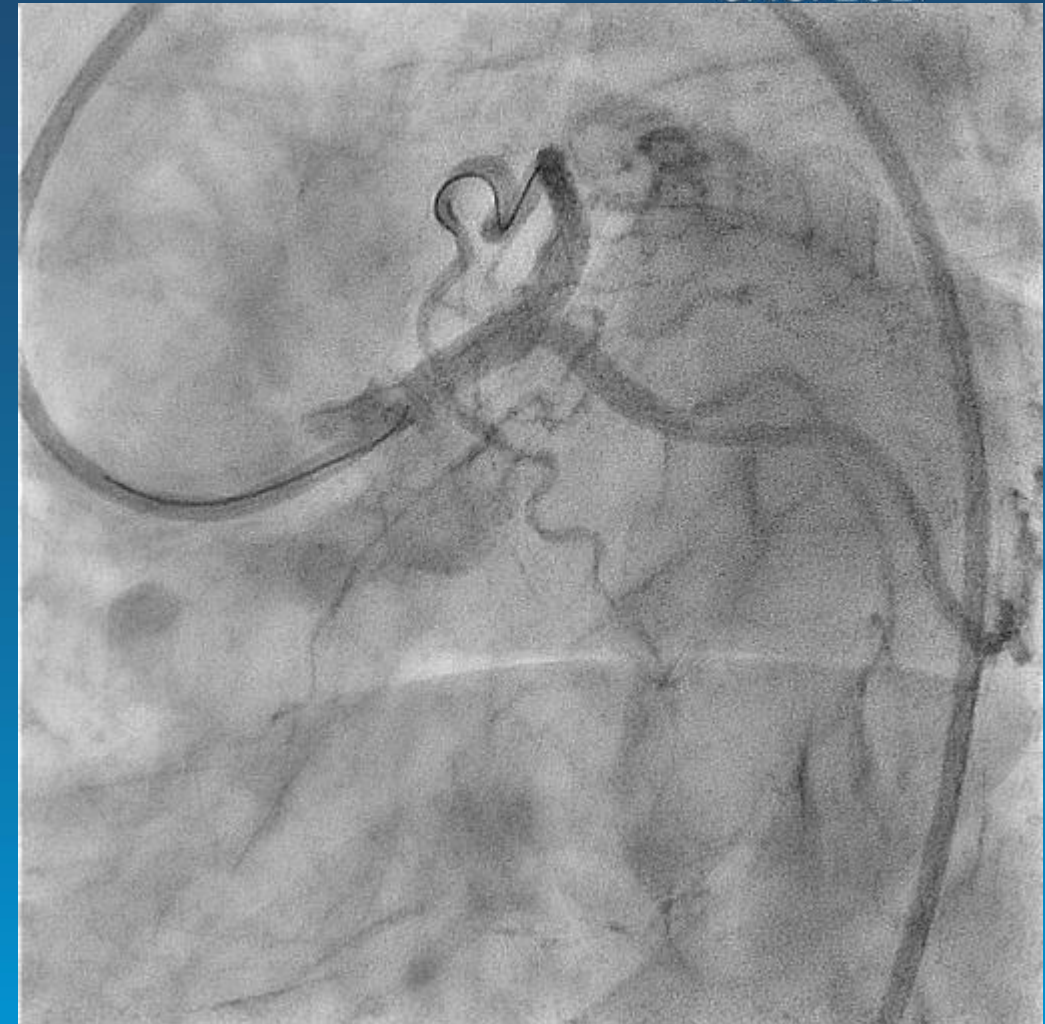


Stent 3.5 x 15 mm

Stent TCI-DA




Stent 4,0 x 22 mm

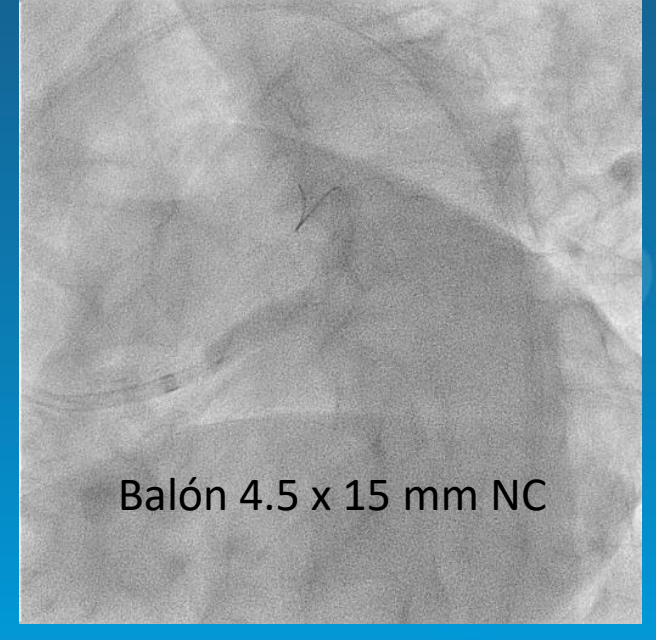
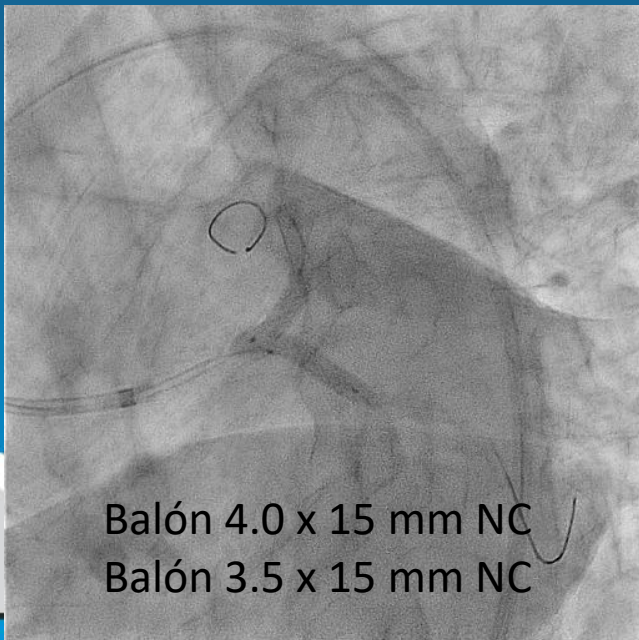
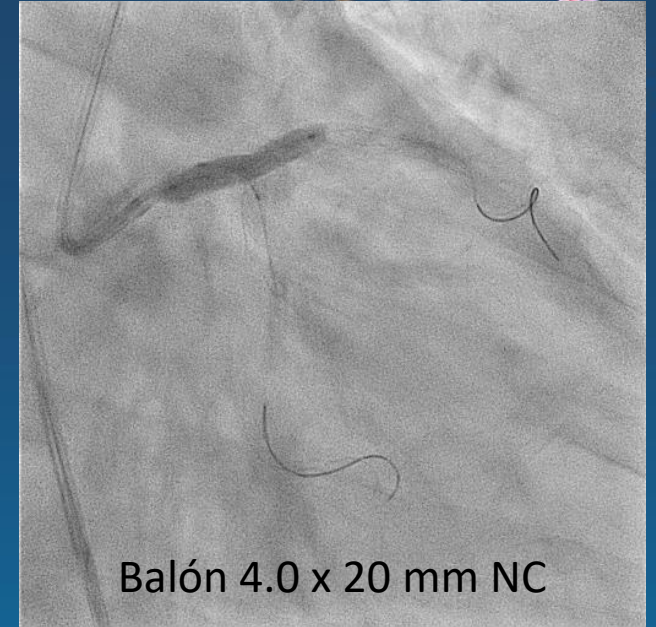
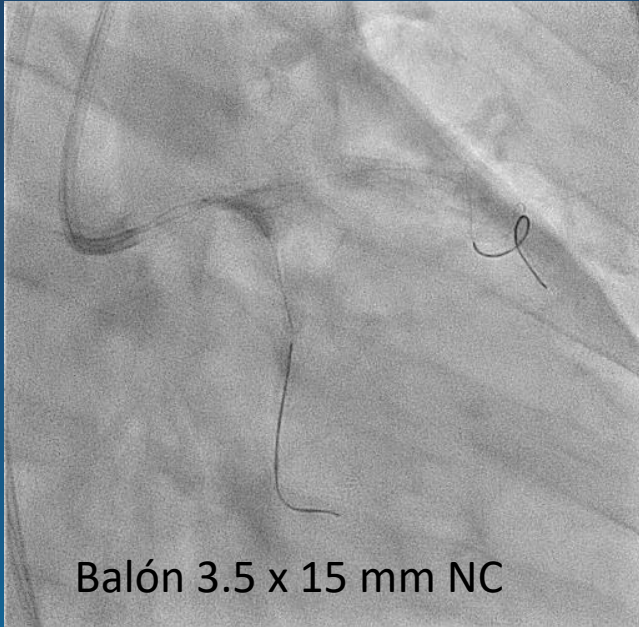


ES CACI 2021

4 Y 5 DE DICIEMBRE 2021 . HOTEL HILTON - PRESENCIAL



2do Kissing Balloon y POT



Resultado final



CI 2021
SENCIAL

IVUS final

