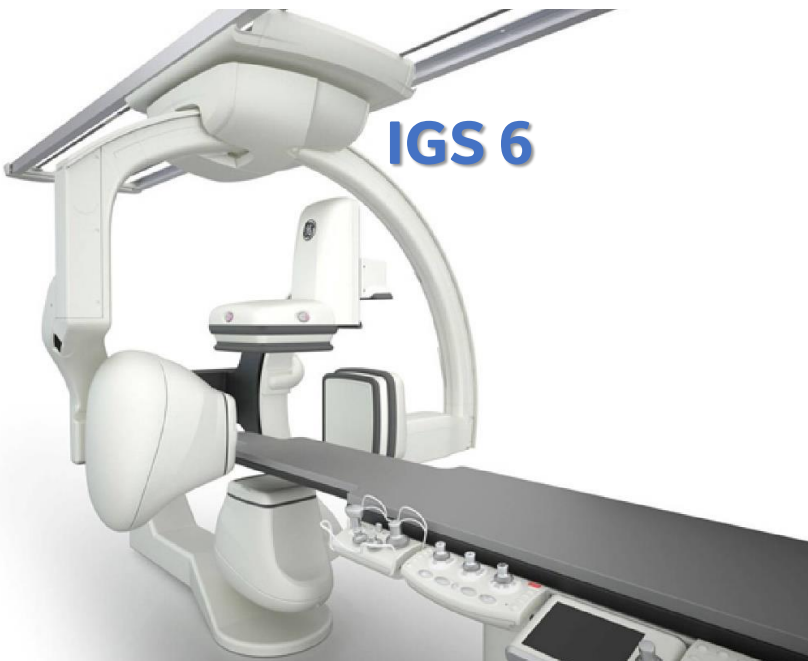
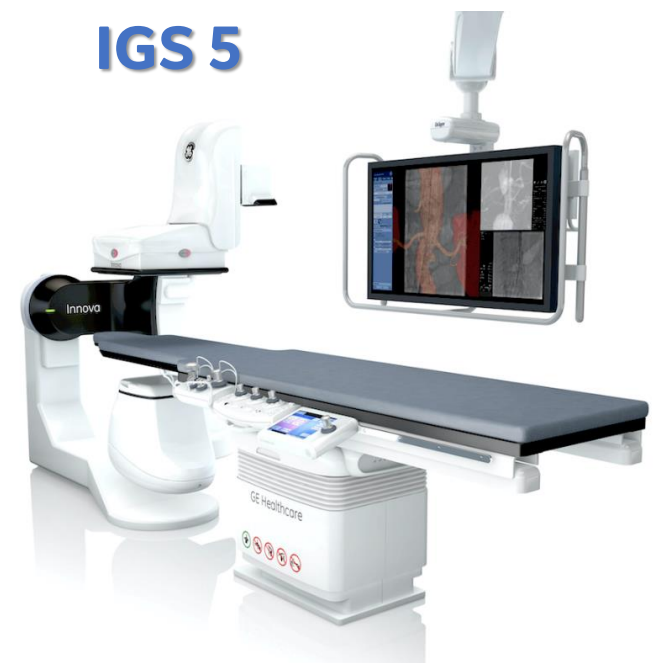
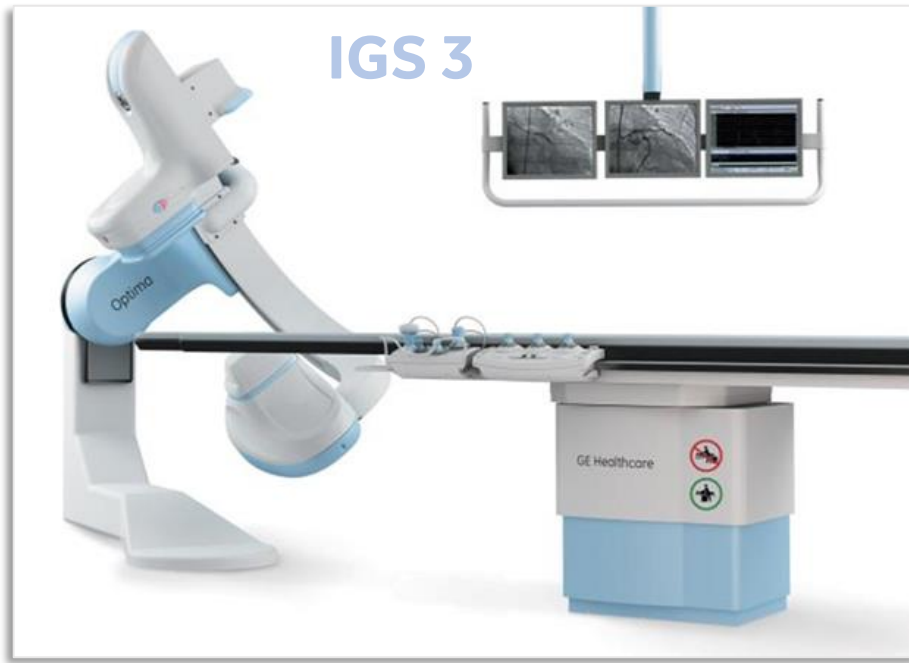Aplicación del uso de la tecnología en territorio aórtico y periférico.

Rodrigo Souza

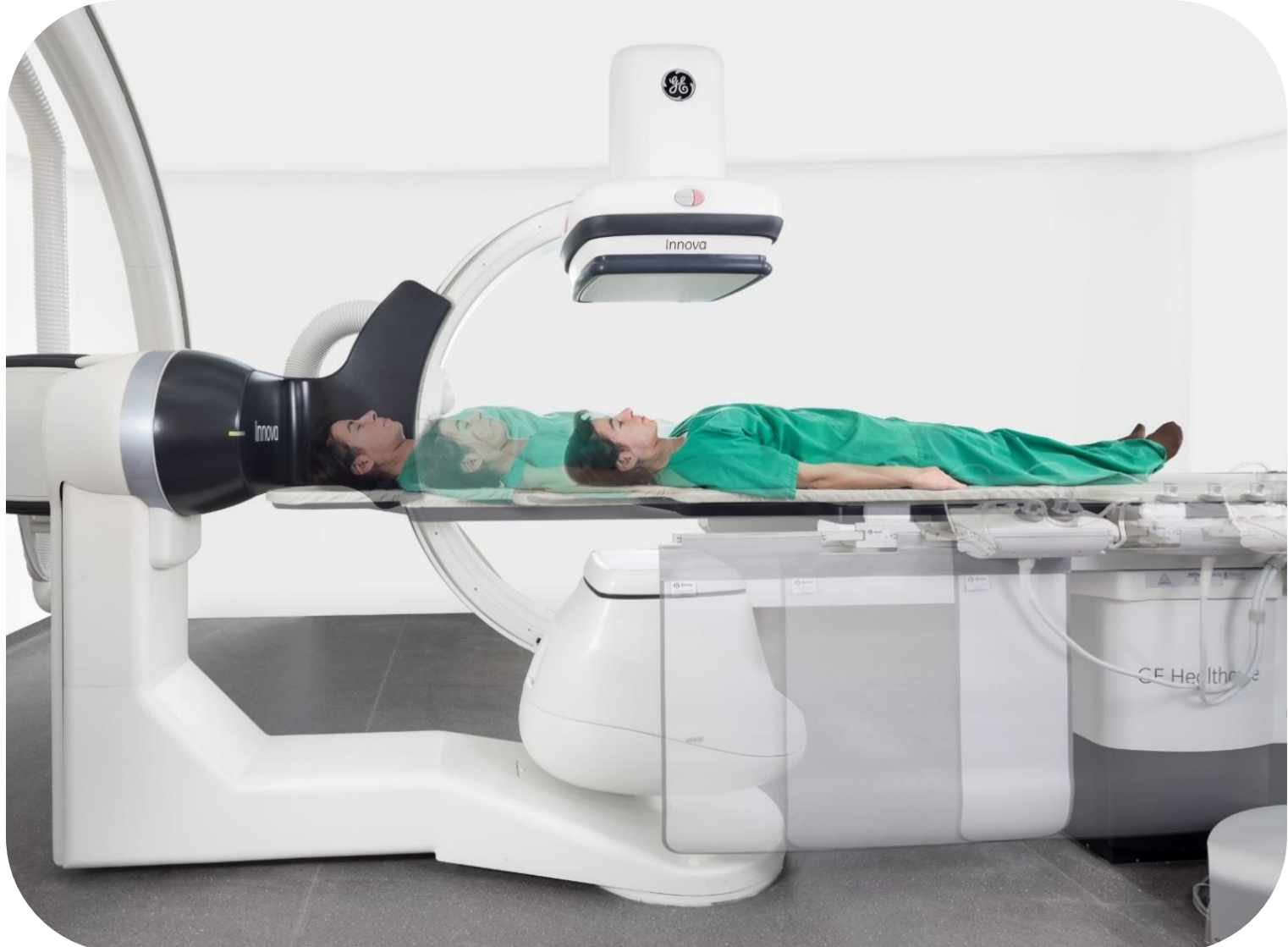Clinical Marketing Leader LATAM

GE HealthCare



Intervenciones rápidas

Proporciona cobertura femoral a la cabeza.

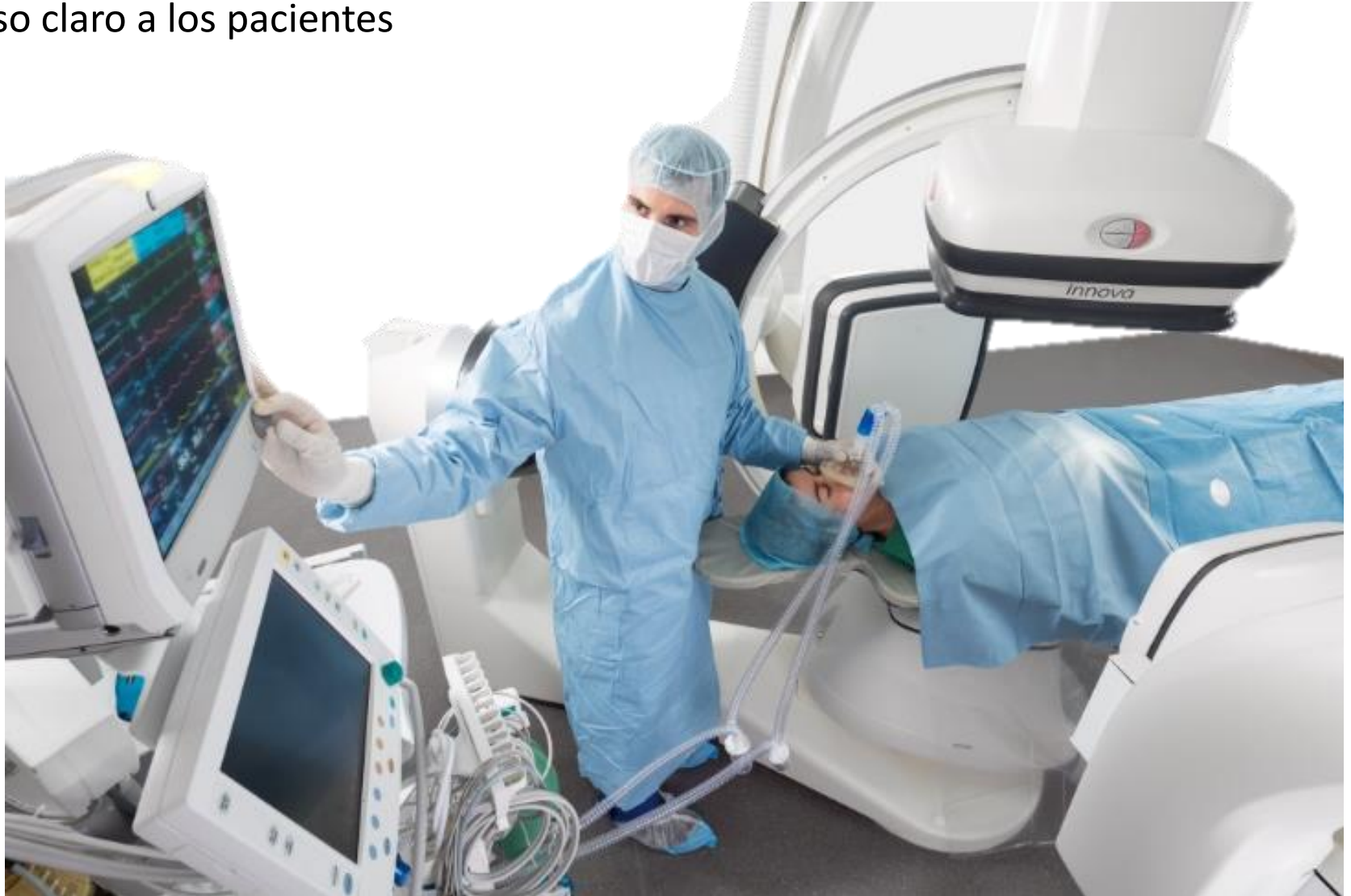

Intervenciones rápidas

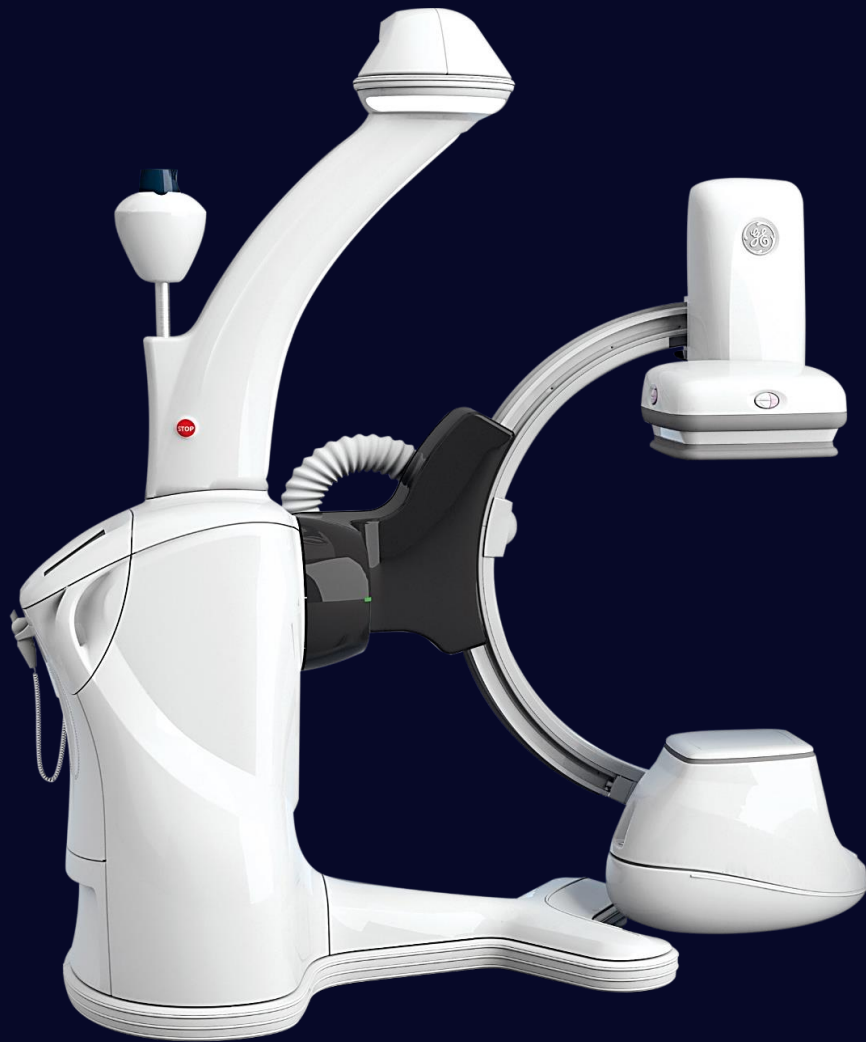

Arco C Desplazado

Acceso claro a los pacientes



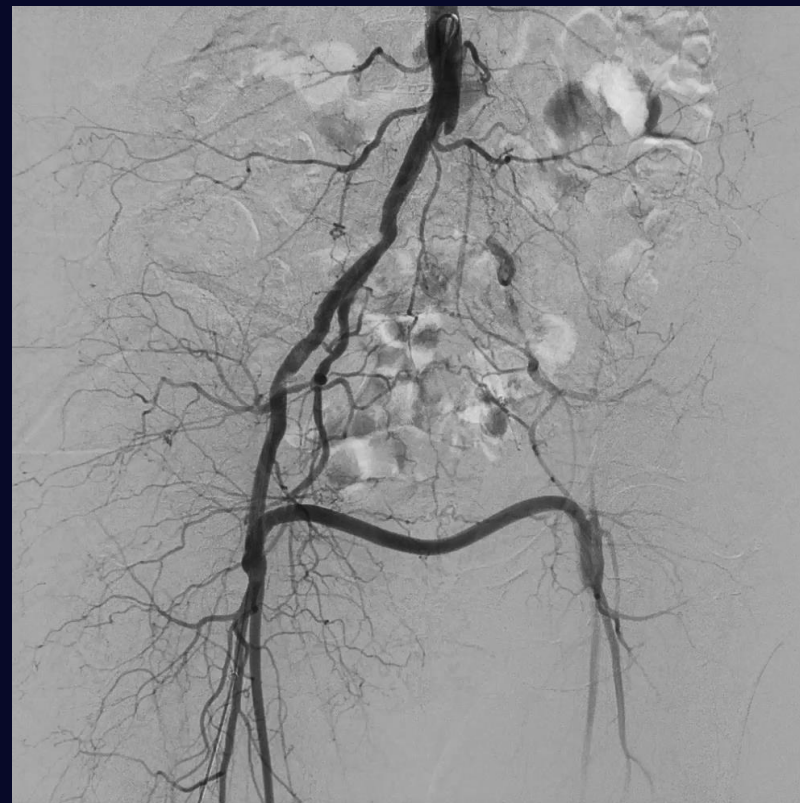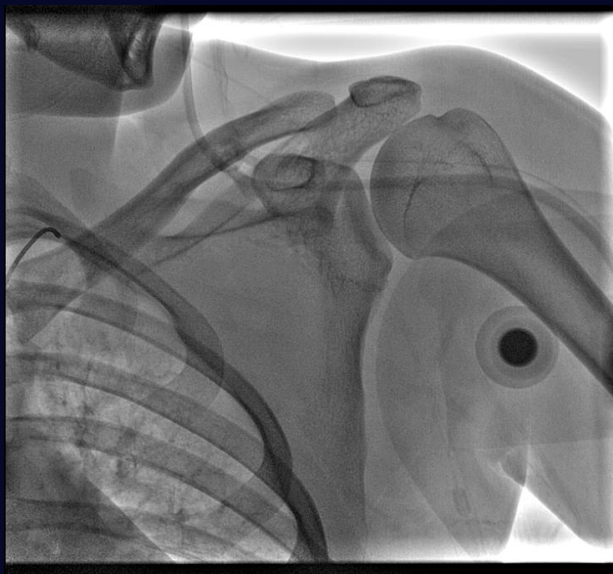
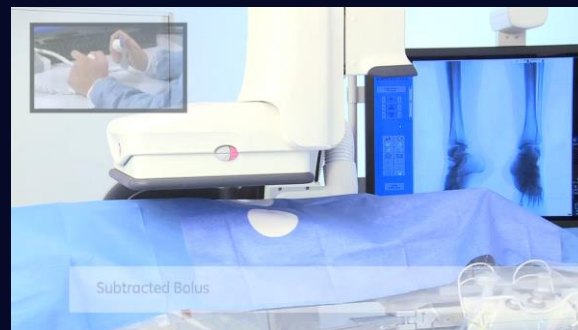movimiento libre robótico



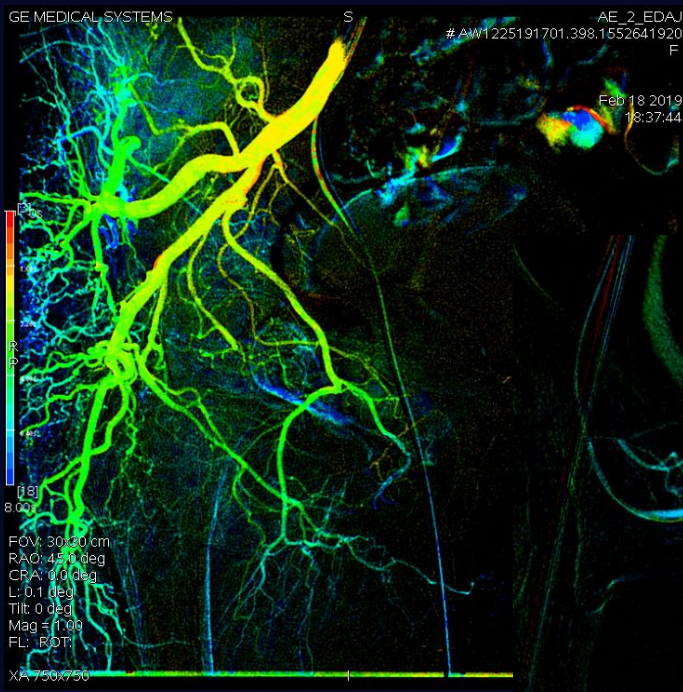
Adquisiciones en movimiento



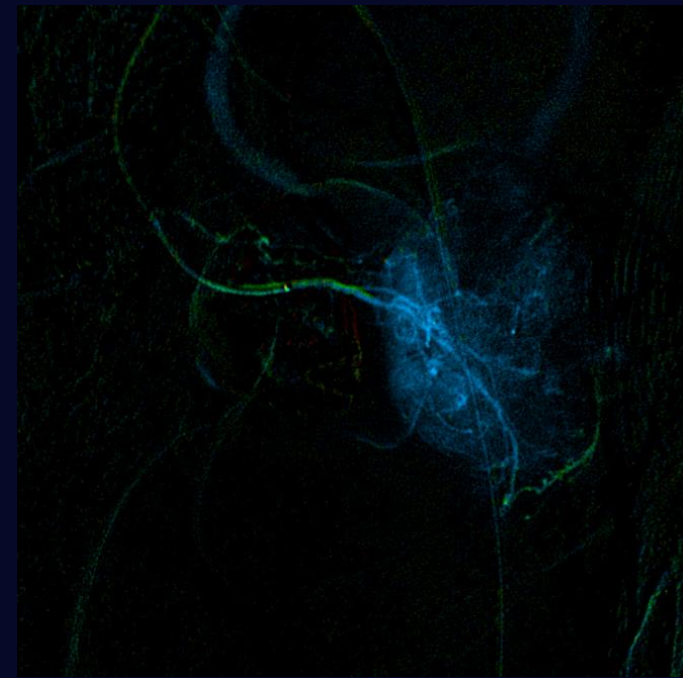
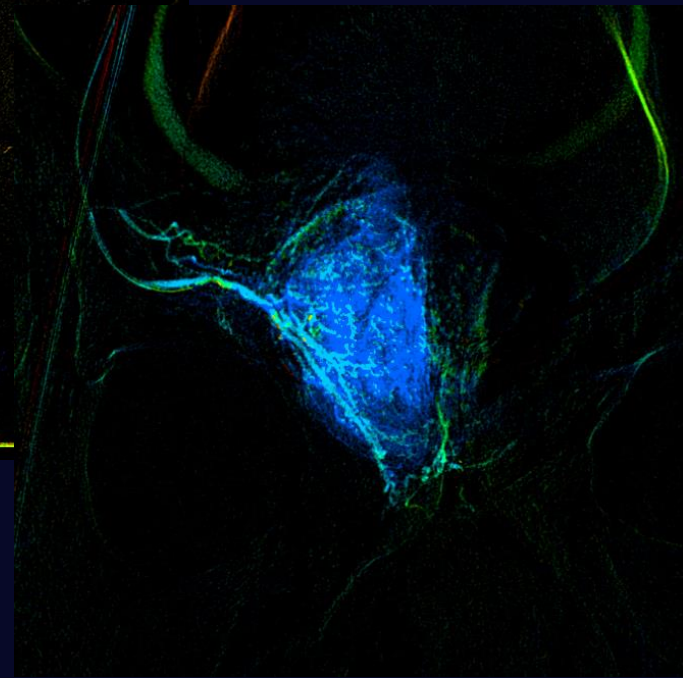
Innova Chase / Breeze



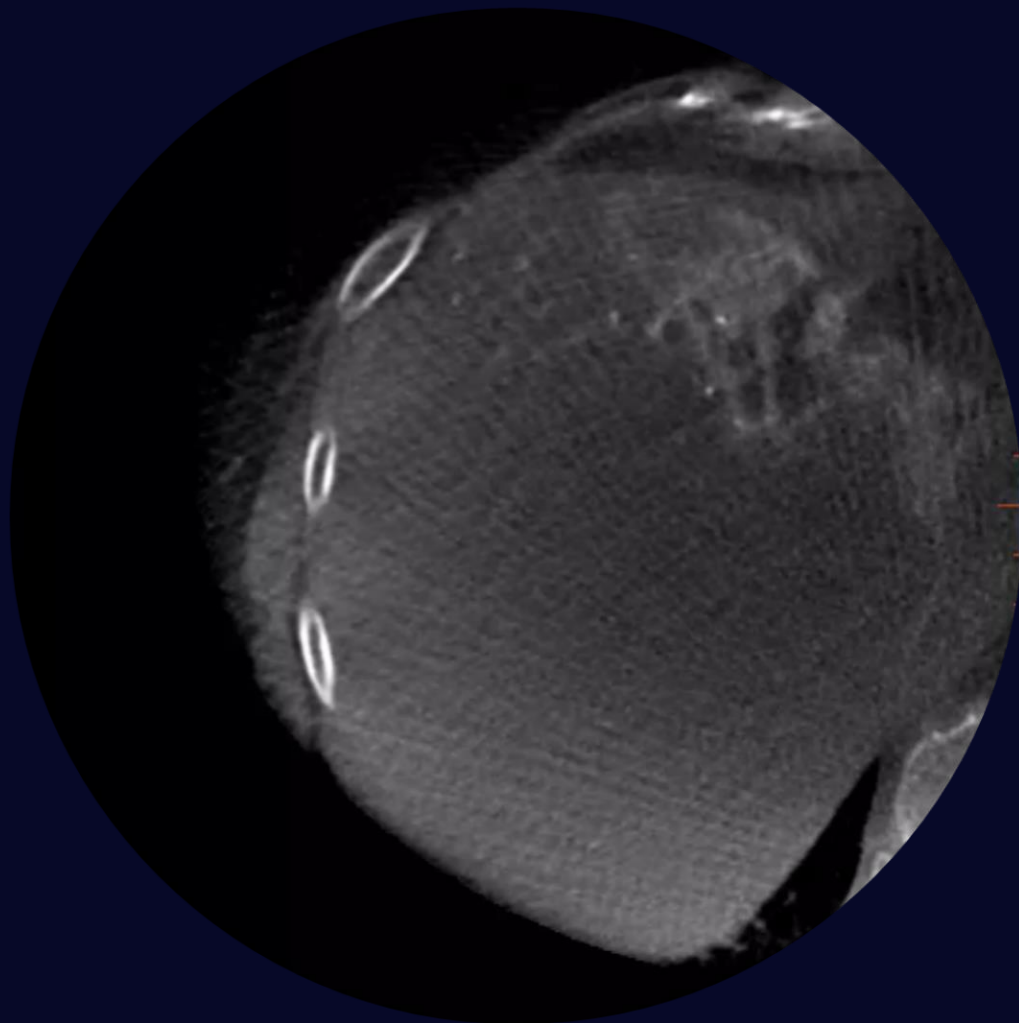
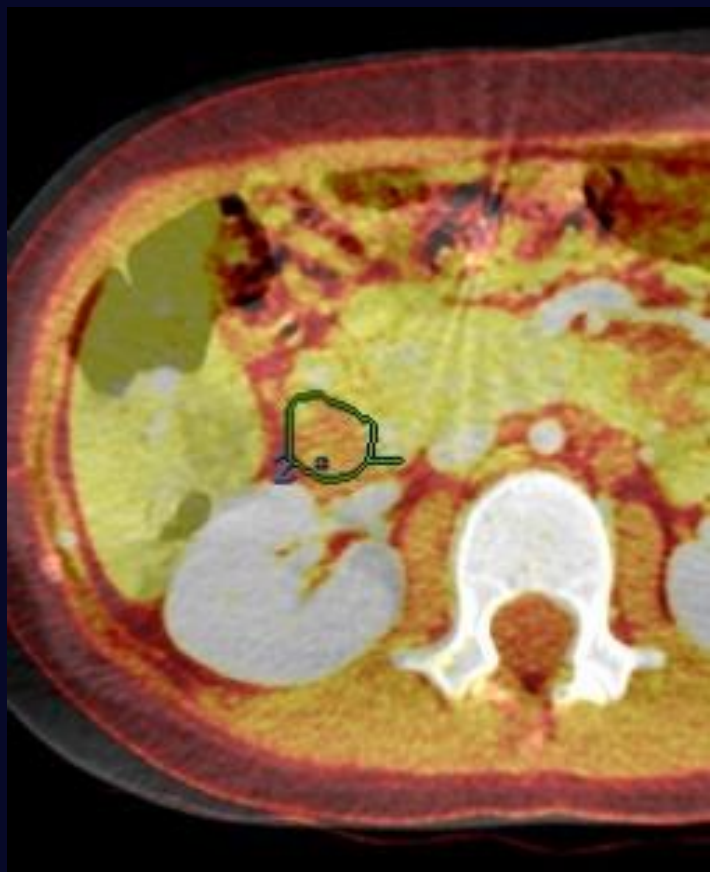
Angioviz – perfusión vascular



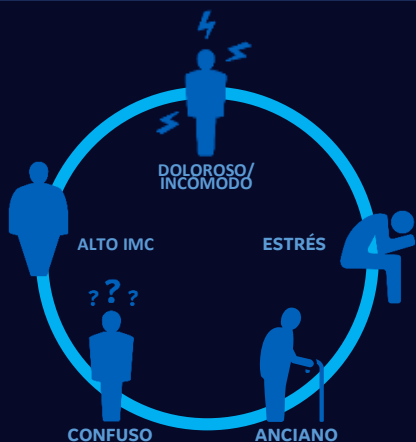Antes y Después



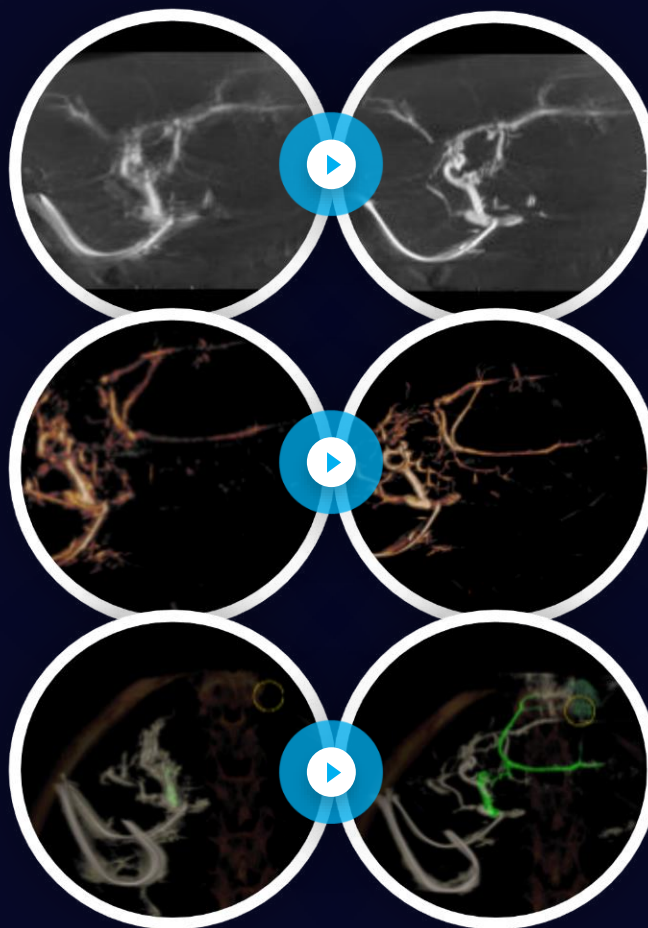
Registro integrado



Movimiento respiratorio



Más de **40%** de las imágenes se degradan debido al movimiento respiratorio



1a Motion Freeze

Solución de compensación del movimiento respiratorio involuntario comercializado para CBCT intervencionista

Ayuda a salvar la adquisición de CBCT

Mejora la visibilidad

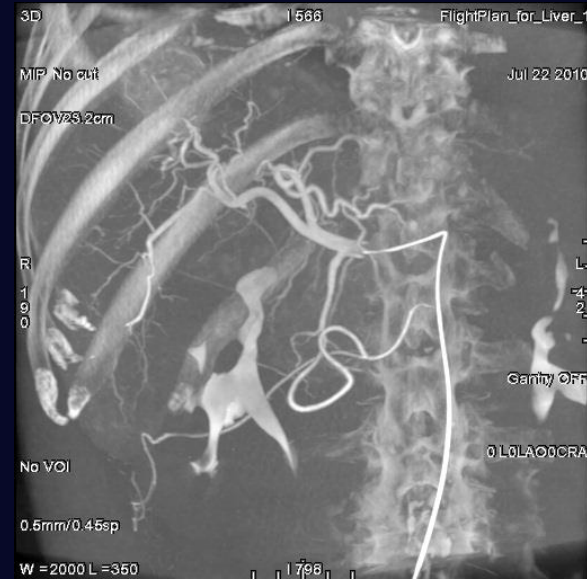
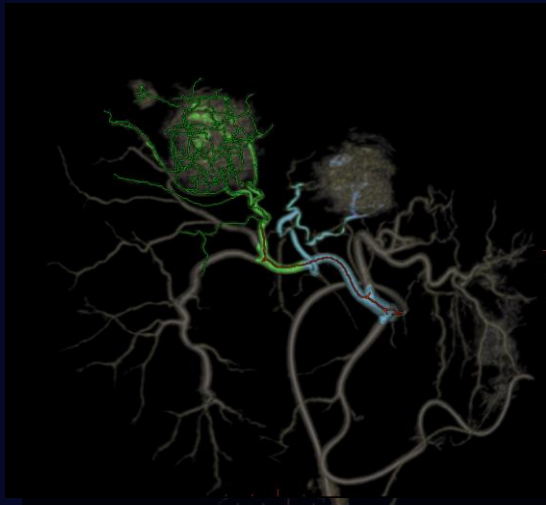
Permite la reducción de adquisiciones repetitivas



Facilita el uso de software avanzado

RoadMap 3D



Ejemplos de casos clínicos*

-25%
Tempo de
fluoro¹

70%
redução de dose

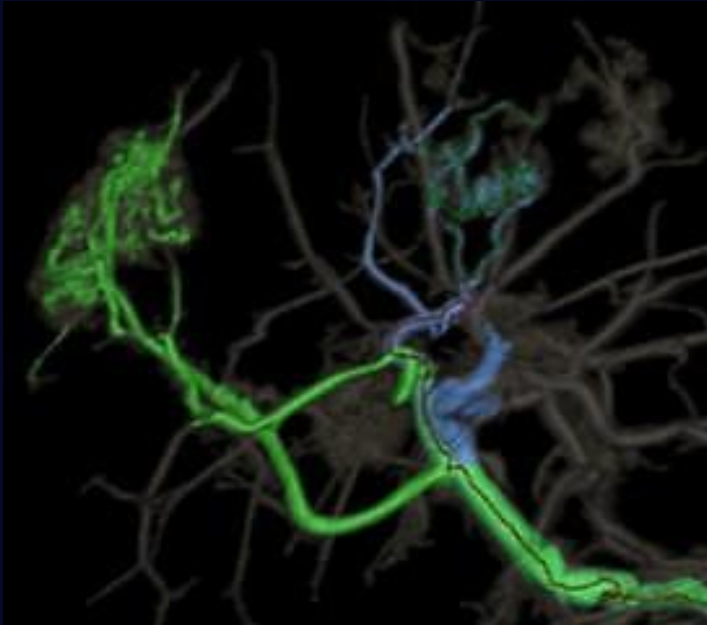
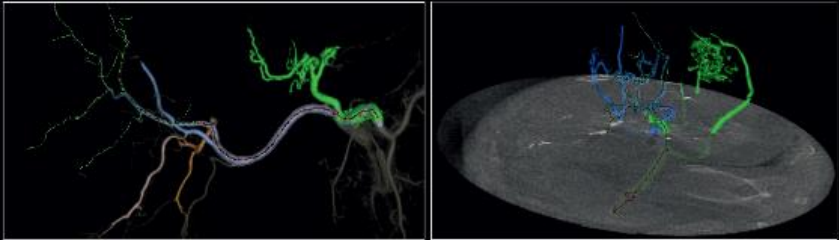
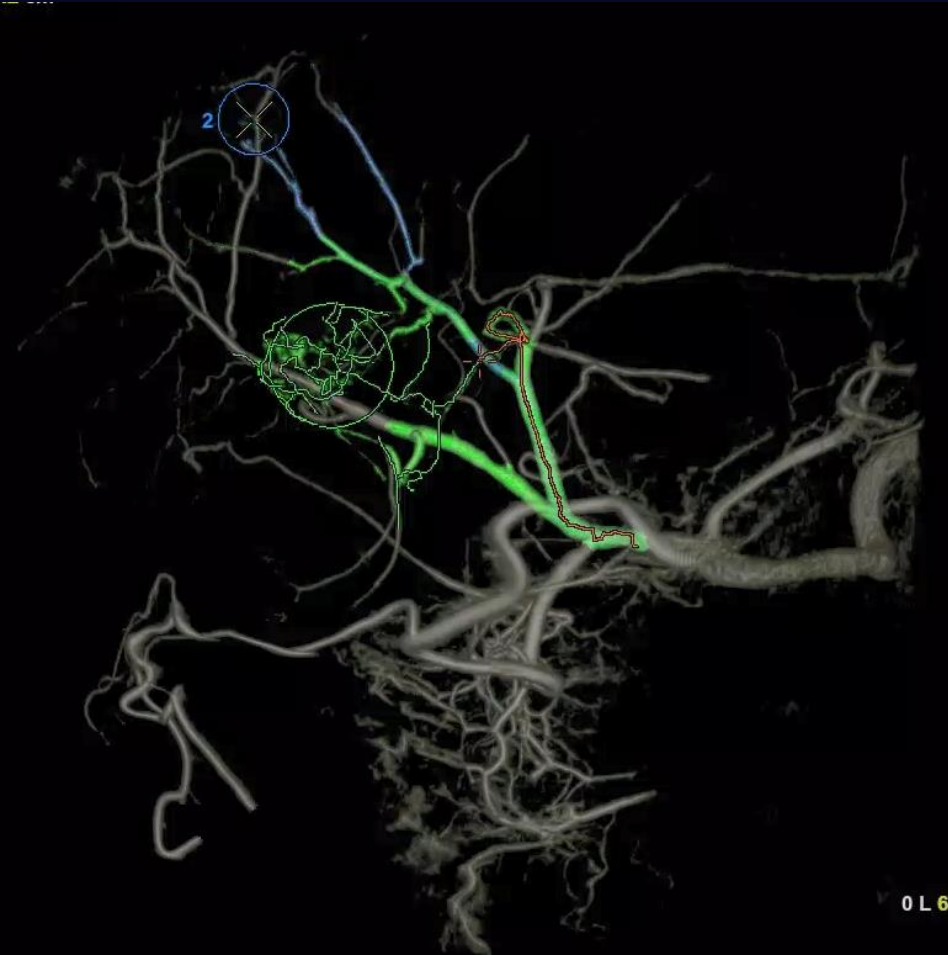
78%
Redução de contraste

28%
Redução de tempo de
procedimento

¹ Novel Integrated 3D Multi-Detector Computed Tomography and Fluoroscopy Fusion for Left Atrial Appendage Occlusion Procedures - Publication in JACC, Volume 68, Issue 18_S, November 2016

Liver ASSIST V.I. ³

Assistente para embolização hepática

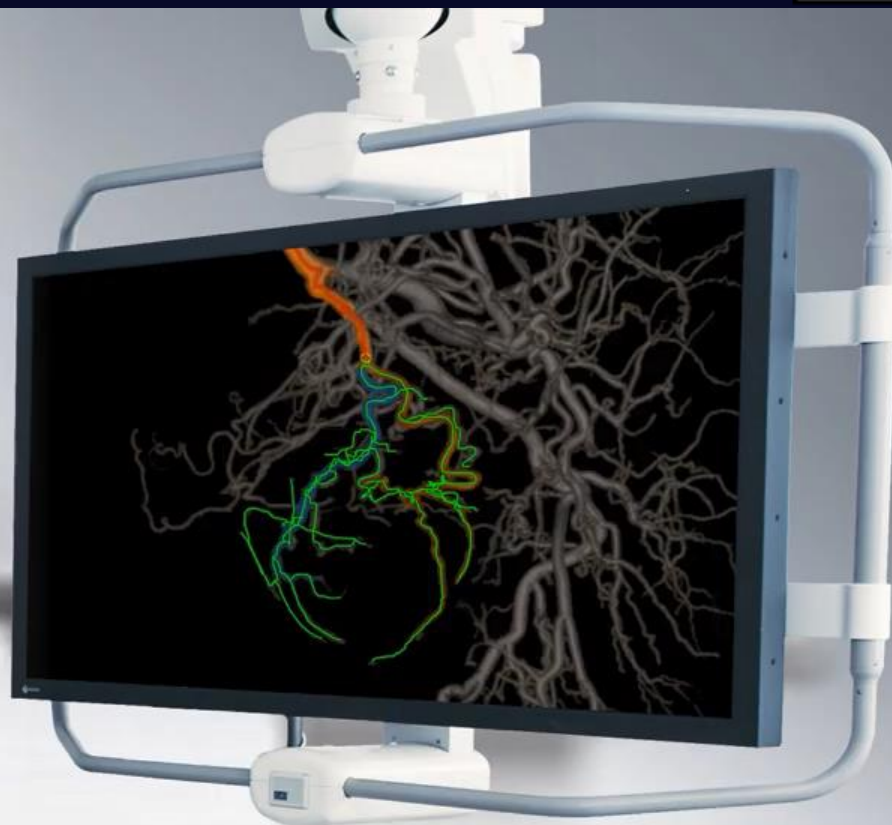



GE Healthcare

Embo ASSIST

Simulate your embolization procedure with **Virtual Injection** before you treat



Powered By
Edison

Embo ASSIST solution includes FlightPlan For Embolization, Vision 2, VessellQ Xpress, Autobone Xpress and requires AW workstation with Volume Viewer, Volume Viewer Innova. These applications are sold separately. Not available for sale in all regions. FlightPlan for Embolization is \$10(k) pending at FDA. Not available for sale in the United States. Not yet CE marked. May not be marketed or placed into service until it has been made to comply with CE marking.

© 2019 General Electric Company.

Vessel ASSIST



Mouse Modes

Visualization

Export

Measure / Annotate

3D HORd_Aortolliac_CTO#01_Vision2 730_63
HD MIP No cut S 1690
 DFOV 39.2 x 43.8 cm
 FC08
 Ex:Jun 13 2015

Calc. Incl.

Gantry OFF
0 L 0 LAO 0 CRA

No VOI
 kV 120
 1.0mm 71.00sp
 W = 800 L = 100
 S 1212

HORd_Aortolliac_CTO#01_Vision2 730_63
 Coronal S 1870
 A: 87.7 Ex:Jun 13 2015
 DFOV 39.2 x 87.7 cm
 No Filter

0.77
 W = 800 L = 100 S 993

HORd_Aortolliac_CTO#01_Vision2 730_63
 Oblique S 2133
 R: 42.5 Ex:Jun 13 2015
 DFOV 39.2 x 140.2 cm
 No Filter

0.77
 W = 800 L = 100 S 993

Pre-Stent Aorta Analysis

Edit Volume

Start of Section

- Celiac Trunk
- Superior Mesenteric Artery
- Right Renal
- Left Renal
- Inferior Mesenteric Artery
- Right External Iliac
- Left External Iliac

Clear tracking

Edition

Edit trace

Interpolation:

Undo edit Accept

Next ▶

Axial HORd_Aortolliac_CTO#01_Vision2 730_63
 S: 1547.5 A 195
 DFOV 58.5 x 39.2 cm
 No Filter
 Im: 78
 Ex:Jun 13 2015

1.00
 W = 800 L = 100
 P 197

HORd_Aortolliac_CTO#01_Vision2 730_63
 Sagittal S 1694
 R: 42.5 Ex:Jun 13 2015
 DFOV 39.2 x 52.7 cm
 No Filter

0.77
 W = 800 L = 100 S 1168

HORd_Aortolliac_CTO#01_Vision2 730_63
 Sagittal S 1694
 R: 42.5 Ex:Jun 13 2015
 DFOV 39.2 x 52.7 cm
 No Filter

0.77/No Lock
 W = 800 L = 100 S 731

0 L 90 LAO 0 CRA

Vessel ASSIST



Rendering Status: in Progress...

WW=256 WL=128

AW1810817118.47.1431702124
HORd_AortolliaC_CTO#01_Vision2
730_63

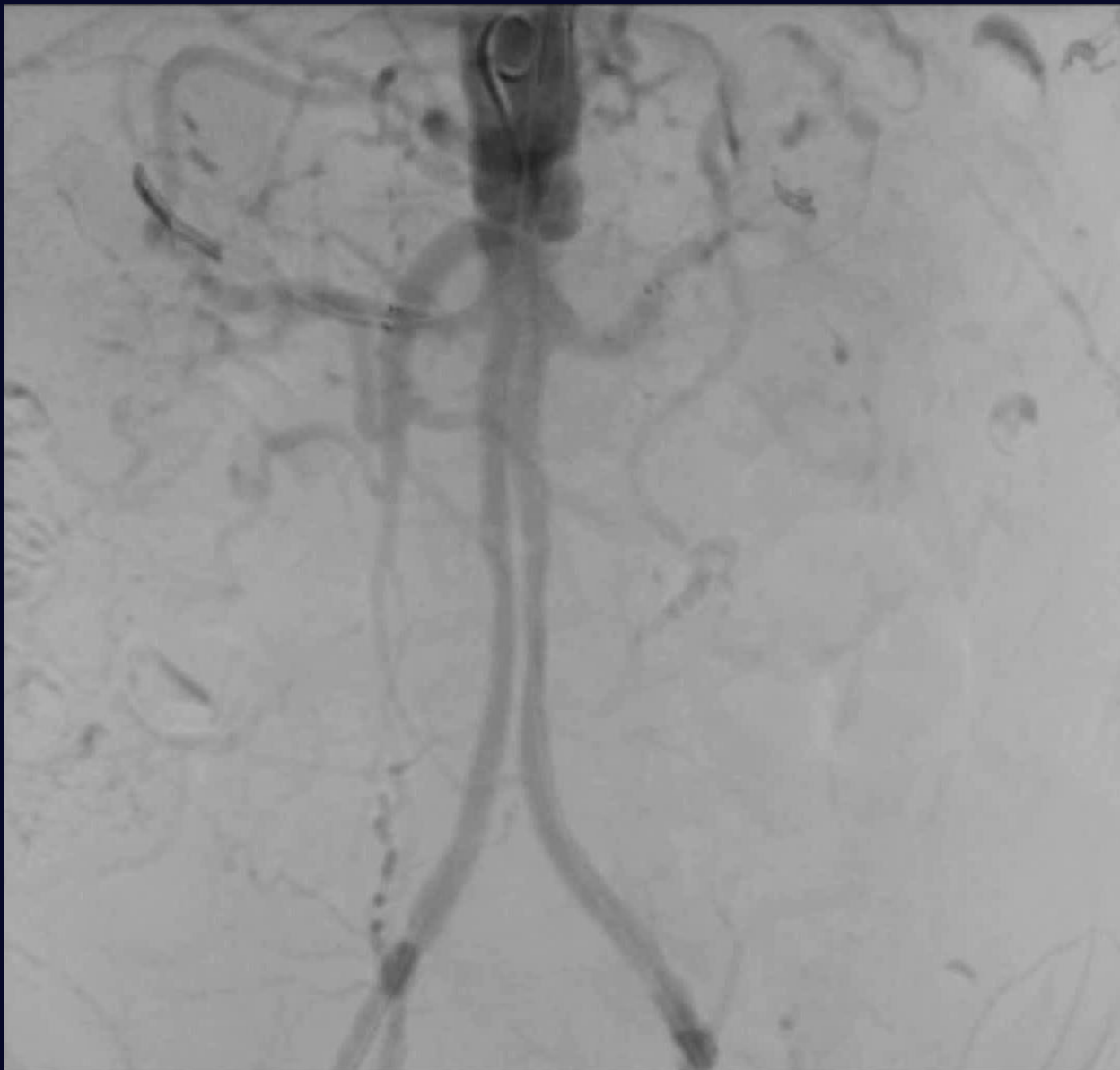Subvolume: Bone
Rendering: VR
Threshold: 0 [-1127 2568]
Opacity: 40%

Image 1

FOV 30.0 cm
LAO 0.0 deg
CRA 0.0 deg
L 0.0 deg

Move the gantry to an appropriate angulation. Acquire a sequence for registration.

Vessel ASSIST



Vessel ASSIST

[youtube.com/watch?v=cdbHAautVqs](https://www.youtube.com/watch?v=cdbHAautVqs)



The screenshot displays the GE Volume Viewer software interface for a lower limb CT scan. The main window shows a 3D reconstruction of the lower limbs with the right external iliac artery highlighted in yellow. The interface is divided into several panels:

- 3D Panel (Left):** Shows the 3D MIP (Maximum Intensity Projection) of the lower limb. Text includes: "3D HD MIP No cut", "DFOV 79.2 x 141.2 cm", "IMR1, Soft Tissue", "Start", "Lower Limb2", "Ex: Apr 25 2016", "Calc. incl.", "R. Iliac", "L. Iliac", "Gantry OFF", "0 L 0 LAO 0 CRA", "No VOI", "kV 120", "1.2mm / 0.63var.sp", "W = 800 L = 100", "I 1509".
- Axial Panel (Top Middle):** Shows two axial slices of the iliac vessels. Text includes: "Axial A 43", "Lower Limb2", "Left External Iliac I: 832.84", "Im: 1116", "DFOV 47.5 x 42.4 cm", "No Filter", "Ex: Apr 25 2016".
- Oblique Panel (Bottom Middle):** Shows an oblique view of the iliac vessels. Text includes: "Oblique", "Lower Limb2", "Left External Iliac LP: 679.8", "DFOV 17.9 x 16.0 cm", "No Filter", "Ex: Apr 25 2016", "SRA", "P 384", "ILP", "0 L 102 LAO 13 CRA".
- Right Panel (Pre-Stent Aorta Analysis):** Contains a control panel for vessel tracking. It includes "Edit Volume" options (Single point, Multi points), a list of tracked vessels ("Start of Section", "Right External Iliac", "Left External Iliac"), and buttons for "Clear tracking", "Edit trace", "Interpolation", "Undo edit", "Accept", and "Next".

Vessel ASSIST



The screenshot displays the Vessel ASSIST software interface. On the left is a control panel with the following sections:

- Top Panel:** "In Vision Exam" dropdown, "Select 3D Model" button.
- Review Panel:** "Review" button, "Film" icon, "Lock Review" button, and navigation icons.
- Subvolume Panel:** "Subvolume" dropdown set to "Calcification", "Rendering" dropdown set to "VR", "Threshold" slider (0 to 3172), and "Opacity" slider (40%).
- Navigation Panel:** "Start Bi-View" and "Recall Bi-View" buttons, and two circular navigation controls.
- Advanced Tools Panel:** "Undo" and "Redo" buttons, "Frontal Roadmap", "Lateral Roadmap", and "Reset" buttons.

The main display area shows a grayscale CT scan of a vessel. A red text overlay reads "NOT FOR DIAGNOSIS". A yellow arrow points to the vessel, with "Frm 119" below it. A green vertical line is drawn on the right side of the vessel. In the top right corner, the following text is displayed:

AW1635837127.714.1446638568
HORd_SFA_CTO#02_Vision2
740_83

In the bottom right corner, the following technical data is shown:

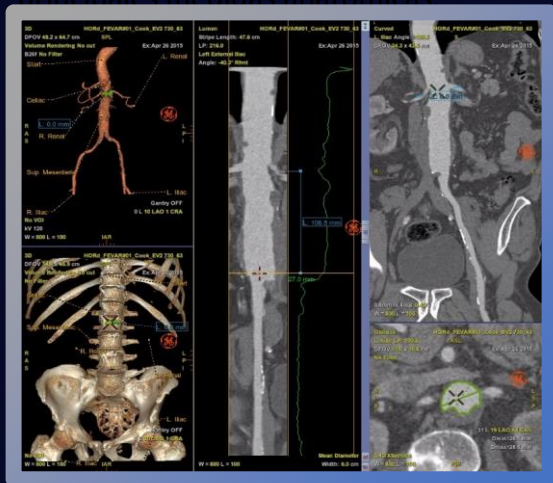
FOV 20.0 cm
LAO 3.8 deg
CAU 1.2 deg
L -89.9 deg

EVAR ASSIST2

Planifique, guíe y evalúe con confianza procedimientos endovasculares complejos

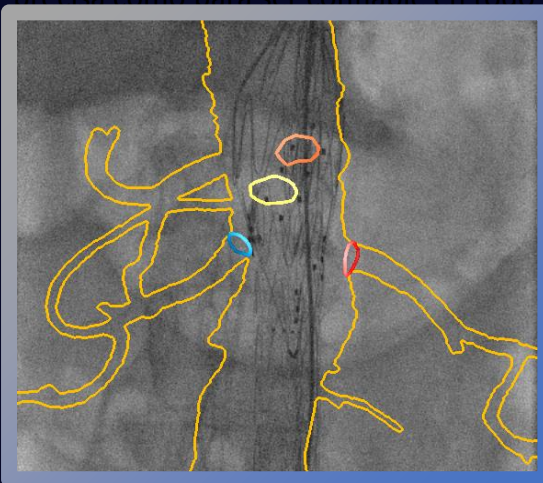
Plan:

Extracción ósea con cero clic y seguimiento aórtico, así como las principales medidas anatómicas



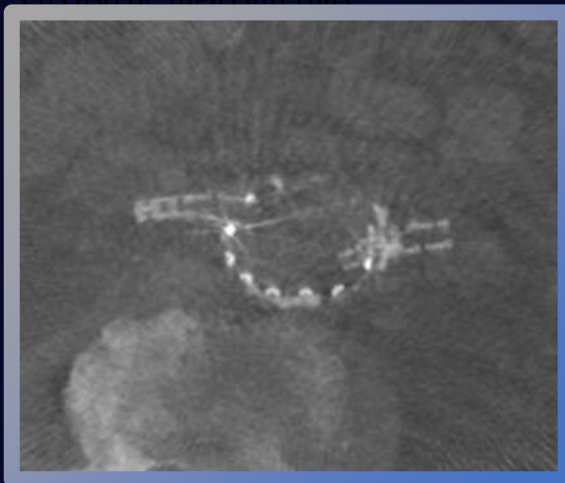
Guía:

Fusión lo suficientemente fácil para usarse de forma rutinaria y lo suficientemente precisa como para ser confiable en todo

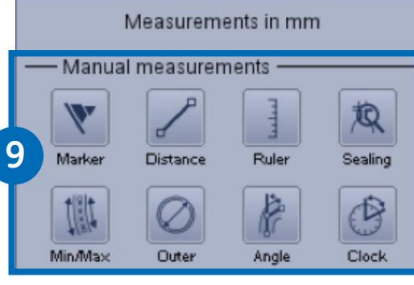
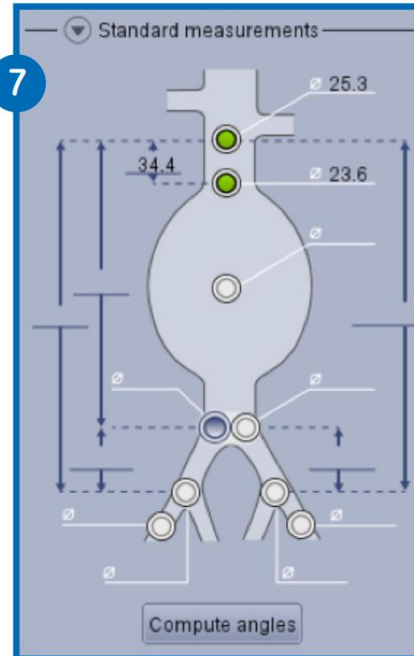
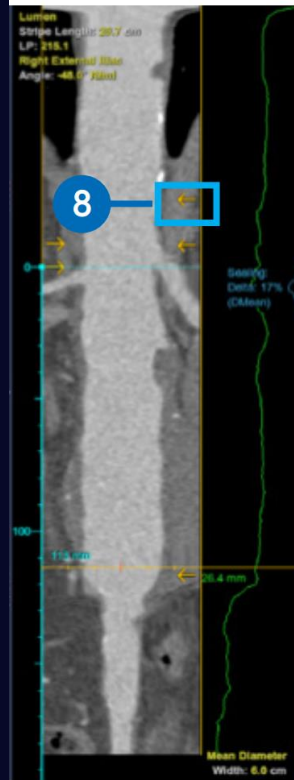
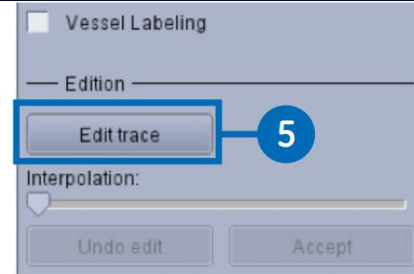
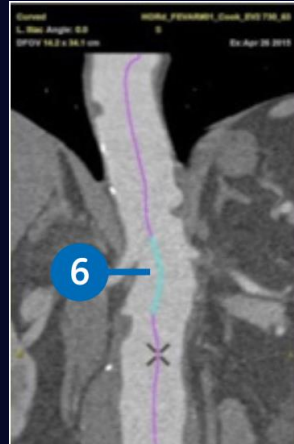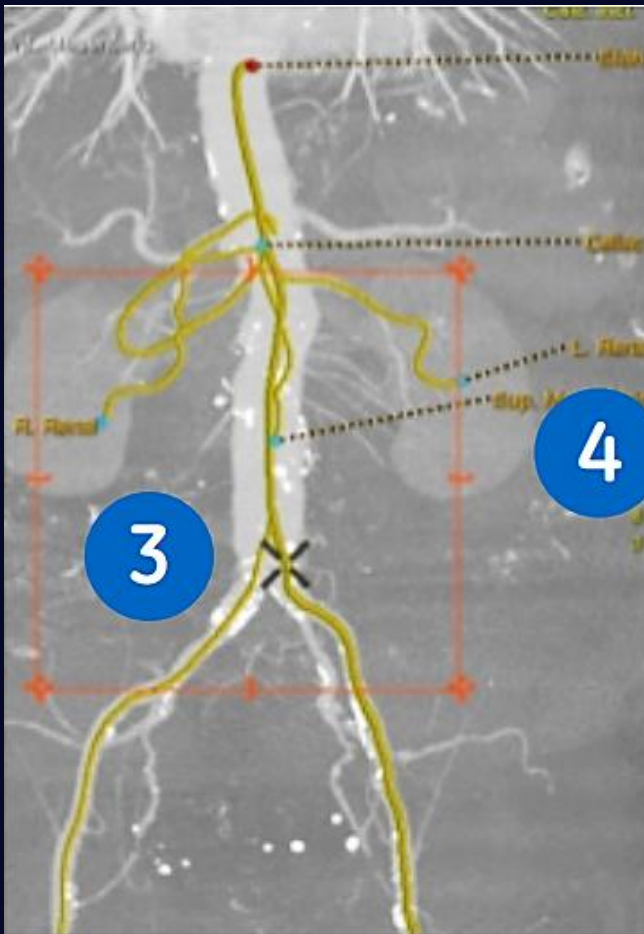


Acceso:

Evaluación de la primera implantación del injerto para una acción inmediata en caso de fugas internas



EVAR ASSIST



EVAR ASSIST



EVAR Nov 28 2017 - 04:37:13

Geral
- Oct 19 2017

Ponto abaixo da extremidade inferior da artéria renal

Extremidade proximal do aneurisma

Bifurcação da aorta direita

Extremidade ilíaca direita

Bifurcação ilíaca esquerda

Artéria ilíaca externa esquerda

Medições em mm

2/4

Nov 28 2017 - 04:37:13

Bifurcação ilíaca esquerda

Artéria ilíaca externa esquerda

Nov 28 2017 - 04:37:13

2/4

EVAR Nov 28 2017 - 04:37:13

Nome: ID do exame: 00000189
 Data de nascimento: May 03 1940 Descrição do exame: Vascular*AOA/TA_ABD_IAG (Adult)
 ID: 222725 Modalidade: CT
 Sexo: M Espessura da série: 1
 Nome do Hospital: Data do Estudo: Oct 19 2017
 Médico responsável: KV: 110
 Número de acesso: 1972471 mA: Modulada

Informação necessária

Lado de introdução: Nenhuma selecionada Renal mais baixo: Nenhuma selecionada
 Ângulo do pescoço infra-renal: NaN* Ângulo do pescoço supra-renal: NaN*

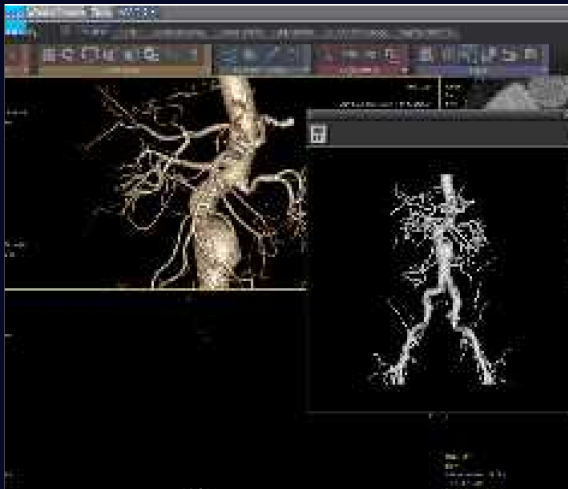
A precisão das medições depende dos parâmetros de aquisição (espessura do recorte, qualidade de imagem) e da tortuosidade dos vasos. As capturas de ecrã deste relatório não correspondem ao tamanho real e foram ajustadas para escala de impressão. Não as utilize para medições diretas. Os diâmetros calculados automaticamente são medidos com base na secção transversal real do lúmen em qualquer ponto. Correspondem aos diâmetros internos que não têm em conta outras estruturas anatómicas (trombo...) para além do lúmen dos vasos. Os diâmetros exibidos no gráfico são do tipo diâmetro médio.

1/4

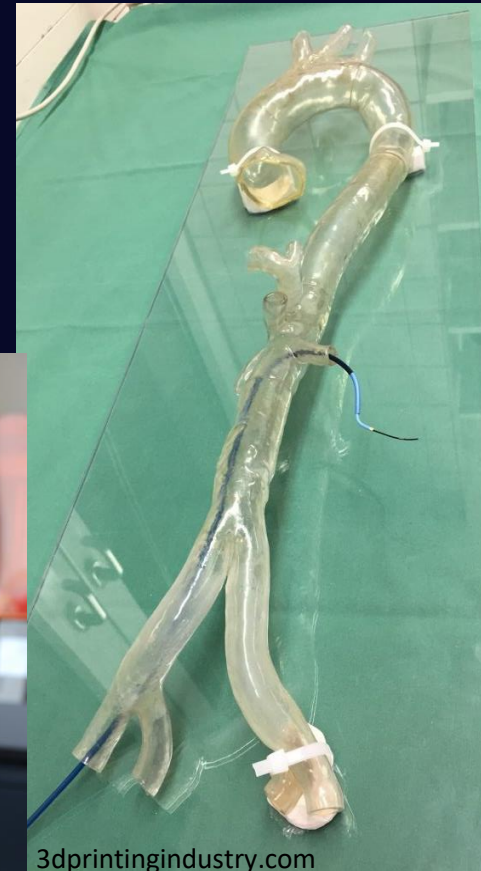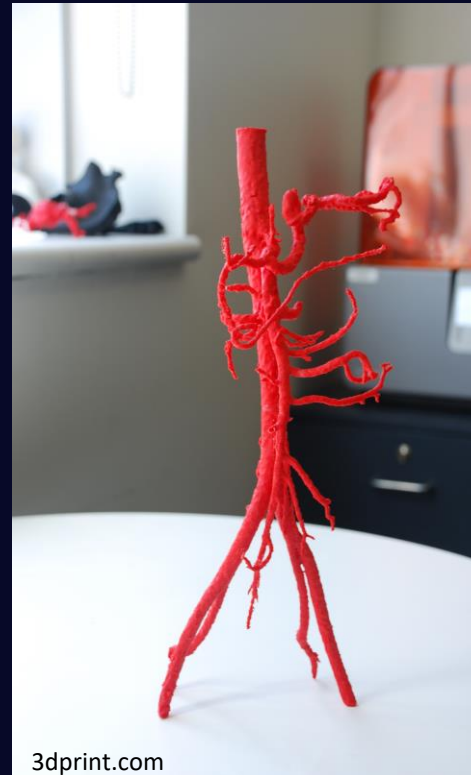
As capturas de ecrã deste relatório não correspondem ao tamanho real e foram ajustadas para escala de impressão. Não as utilize para medições diretas.

4/4

EVAR ASSIST



AW 3D Suíte



EVAR ASSIST



GE NOT FOR C AutoBone XPress ABDOMEN Pre-Stent Aorta Analysis Post-Stent Aorta Analysis Abdominal Analysis Reformat

Mouse Modes Visualization Export Measure / An

3D HORd_FEVAR#01_Cook_EV2 730_63
DFOV 48.2 x 64.7 cm SPL
Volume Rendering No cut
B26f No Filter
Ex: Apr 26 2015

L. Renal
Celliac
R. Renal
Sup. Mesenteric
L. Iliac
R. Iliac
Gantry OFF
0 L 10 LAO 1 CRA
No VOI
KV 120
W = 800 L = 100

Lumen HORd_FEVAR#01_Cook_EV2 730_63
Stripe Length: 47.6 cm
LP: 178.8
Left External Iliac
Angle: -125.0° Rfnt
Ex: Apr 26 2015

29.6 mm

Mean Diameter
Width: 6.0 cm

Curved HORd_FEVAR#01_Cook_EV2 730_63
L. Iliac Angle: -169.6
DFOV 24.3 x 43.6 cm
Ex: Apr 26 2015

0.8mm / 0.40sp 0.40
W = 800 L = 100

Oblique HORd_FEVAR#01_Cook_EV2 730_63
L. Iliac LP: 178.8
DFOV 11.9 x 10.6 cm
No Filter
Ex: Apr 26 2015

38 L 1 LAO 73 CAU
Dmin=25.9 mm
Dmax=32.0 mm

0.40/XSection
W = 800 L = 100

Pre-Stent Aorta Analysis

— Edition —

Edit trace Edit Section

Interpolation:

Undo edit Accept

— Manual measurements —

Curv. Dist. Marker Manual Dist.
3D Angle Min/Max Stenosis
Aneurysm ColorID Thrombus

— Pref measurements —

Name	Status
Point above Renal Arteries	
Most Inferior Renal Artery	
15 mm Below Most Inferior Ren...	
Proximal End of Aneurysm	
Distal End of Aneurysm	
Largest Enhanced Lumen	
Right Aortic Bifurcation	
Right Iliac Bifurcation	
Left Aortic Bifurcation	
Left Iliac Bifurcation	

— Saving —

Save State Save Protocol

Previous

EVAR ASSIST



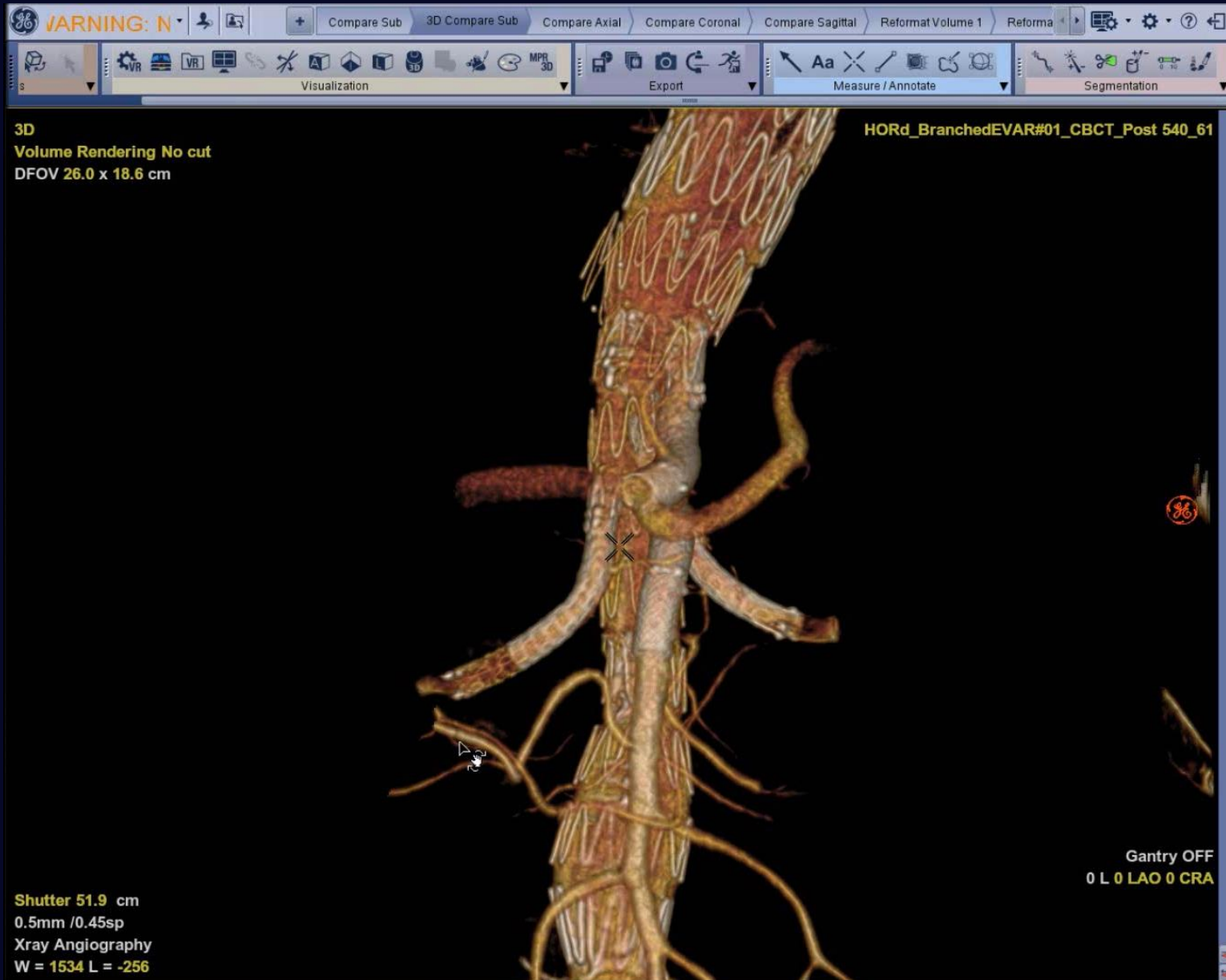
AW1213338373.636.1431710478
HORd_FEVAR#01_Cook_EV2
730_63

Image 1

FOV 30.0 cm
LAO 88.4 deg
CRA 0.0 deg
L 0.0 deg

Move the gantry to an appropriate angulation. Acquire a sequence for registration.

EVAR ASSIST

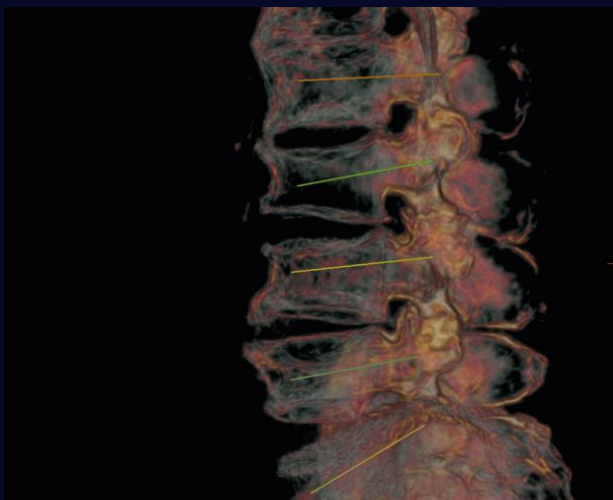


Needle ASSIST

Planifique, oriente y evalúe procedimientos complejos basados en agujas con confianza

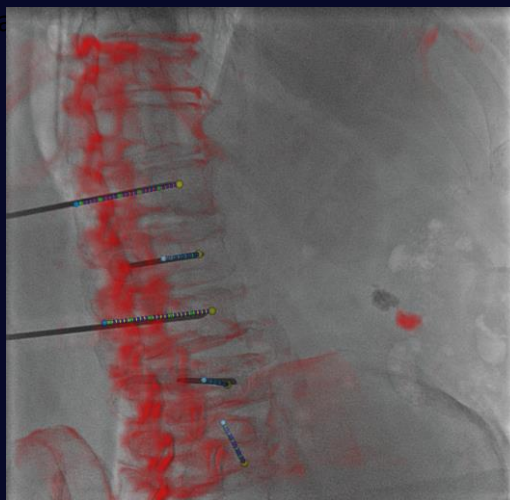Plan:

Con Trayectoria Planificación, puede planificar el procedimiento utilizando excelente información 3D y determinar



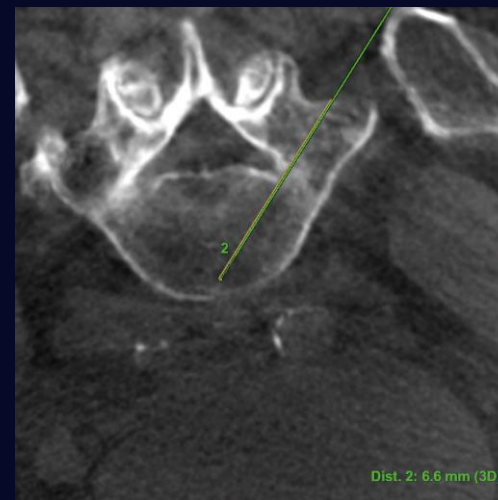Guía:

Con TrackVision 2¹, puede guiar su aguja a través del camino virtual que sigue el ángulo del brazo en C y el movimiento de la

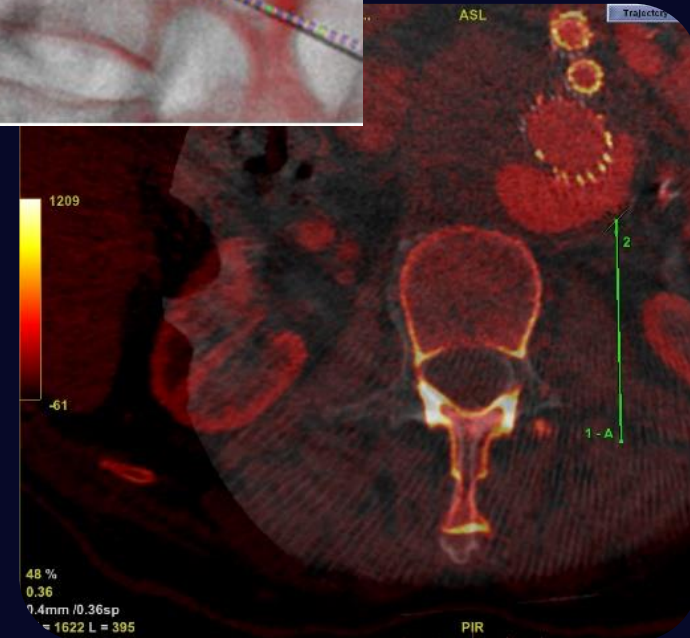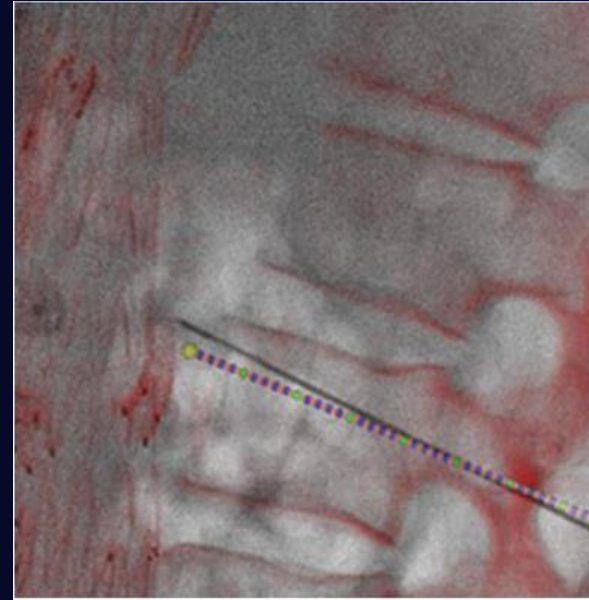
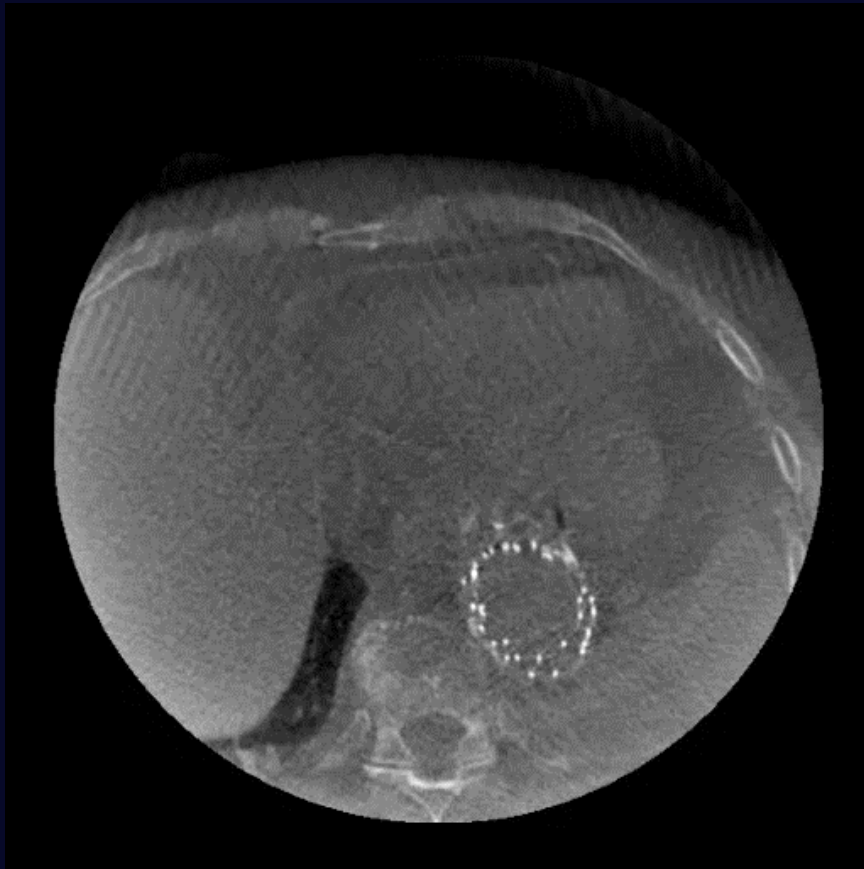


Acceso:

Con Stereo 3D¹, vea la aguja 3D reconstruida en la vista oblicua CBCT a partir de solo 2 imágenes

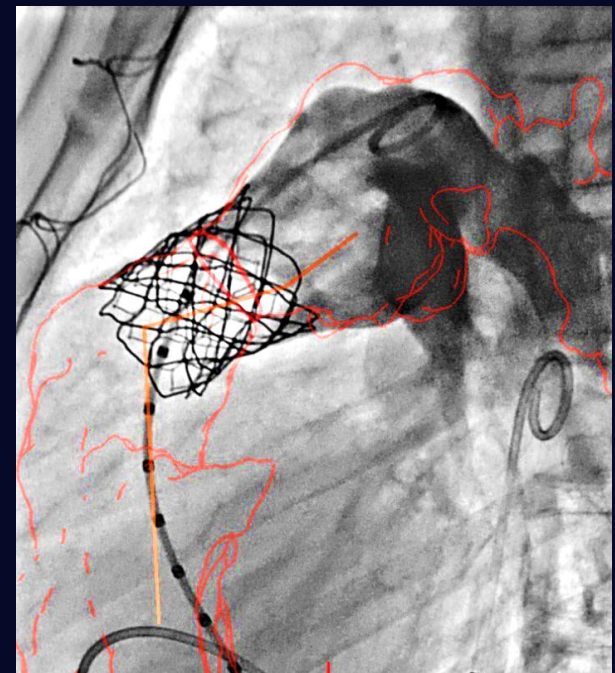
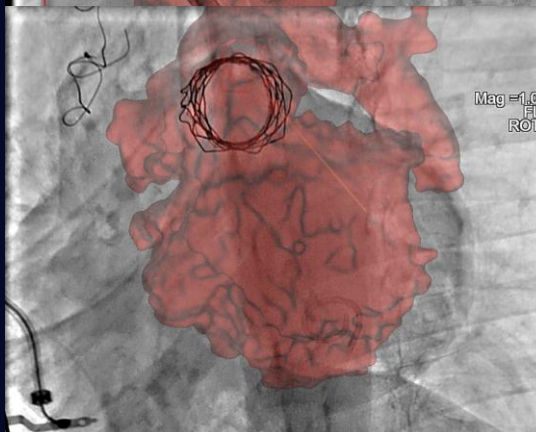
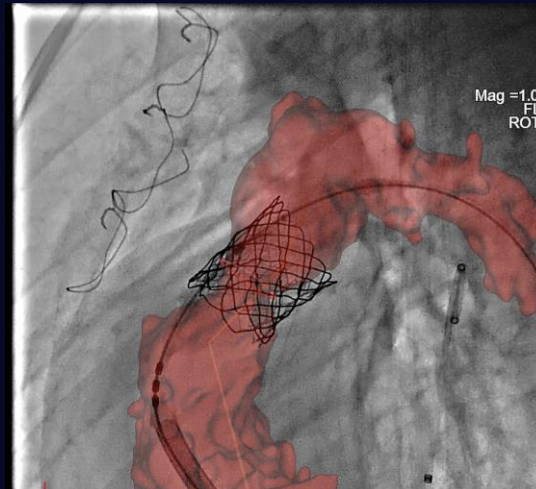
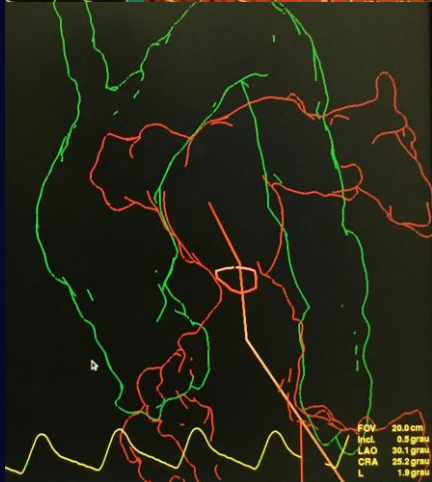


Needle ASSIST



RoadMap 3D

EP.Vision en arteria pulmonar





ELEVATING RADIOLOGY



Rodrigo Souza

Clinical Marketing Leader LATAM

+55.15.99837-7368

