



# ATENEIO CACI

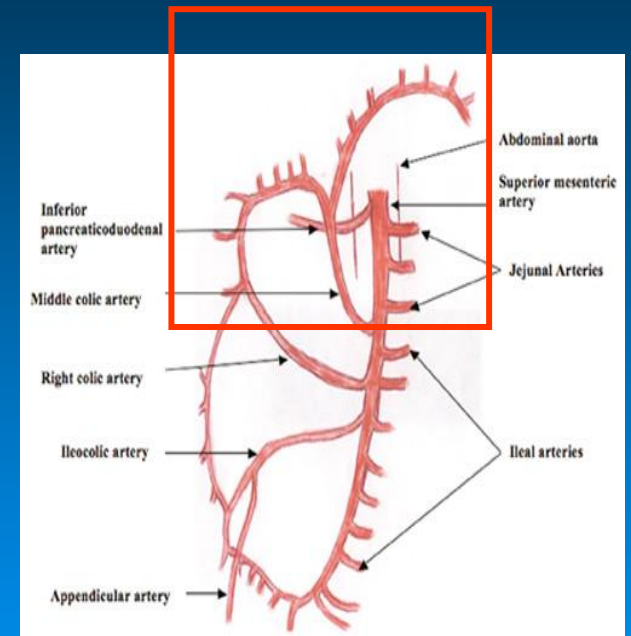
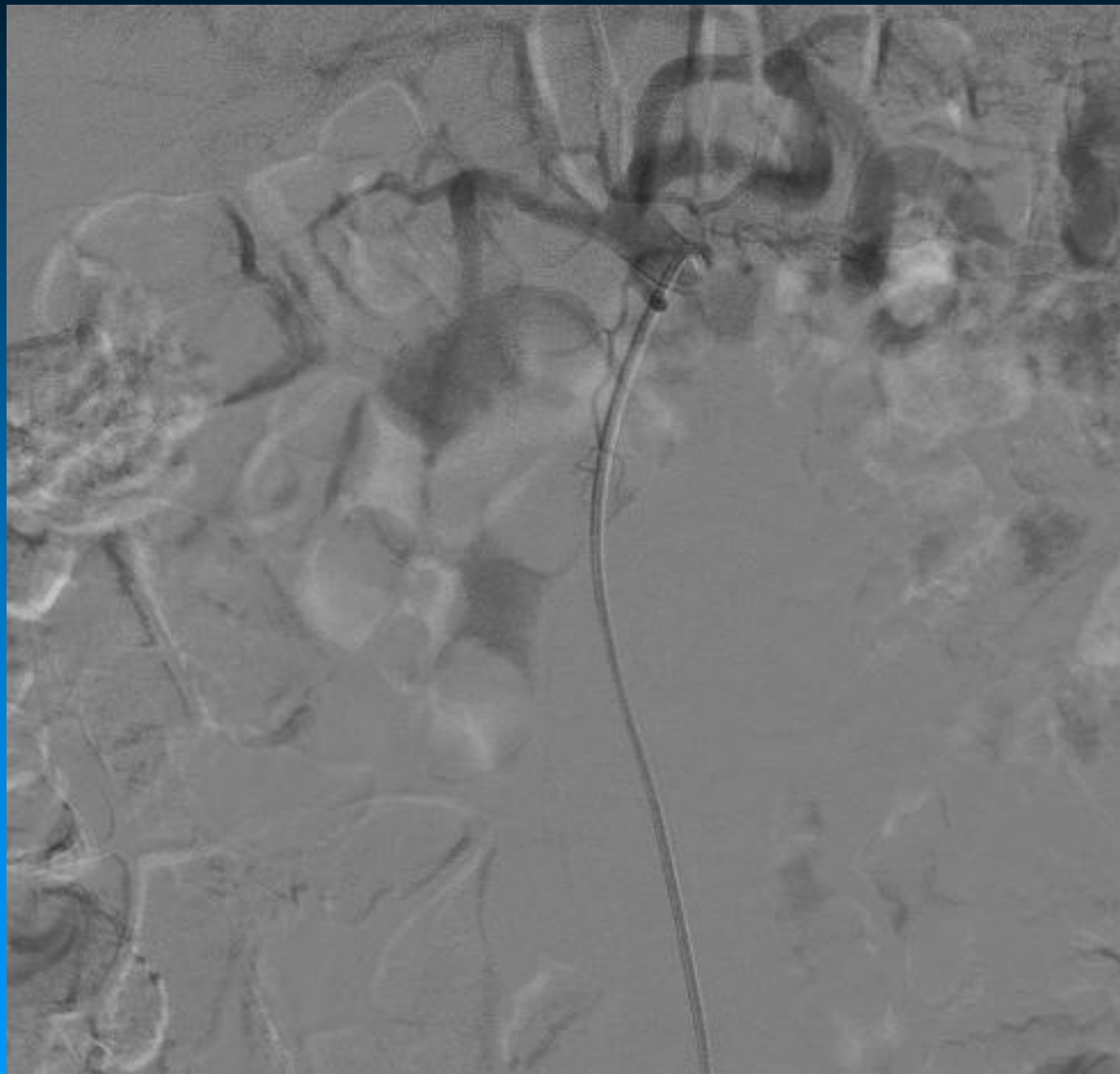
## HEMORRAGIA DIGESTIVA

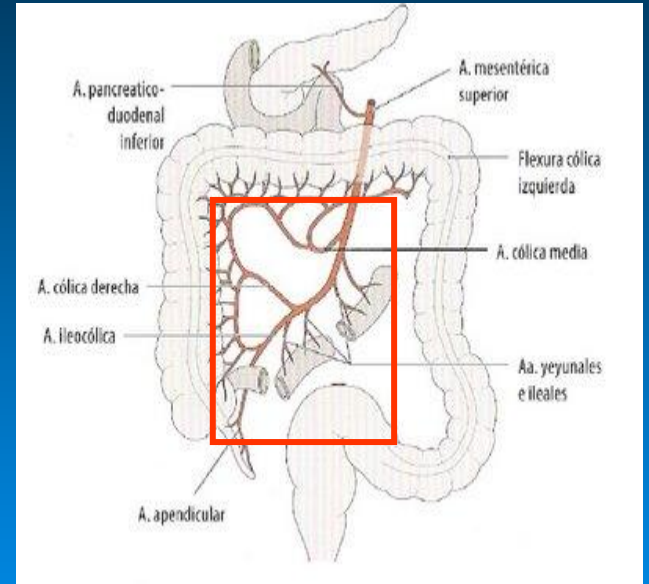
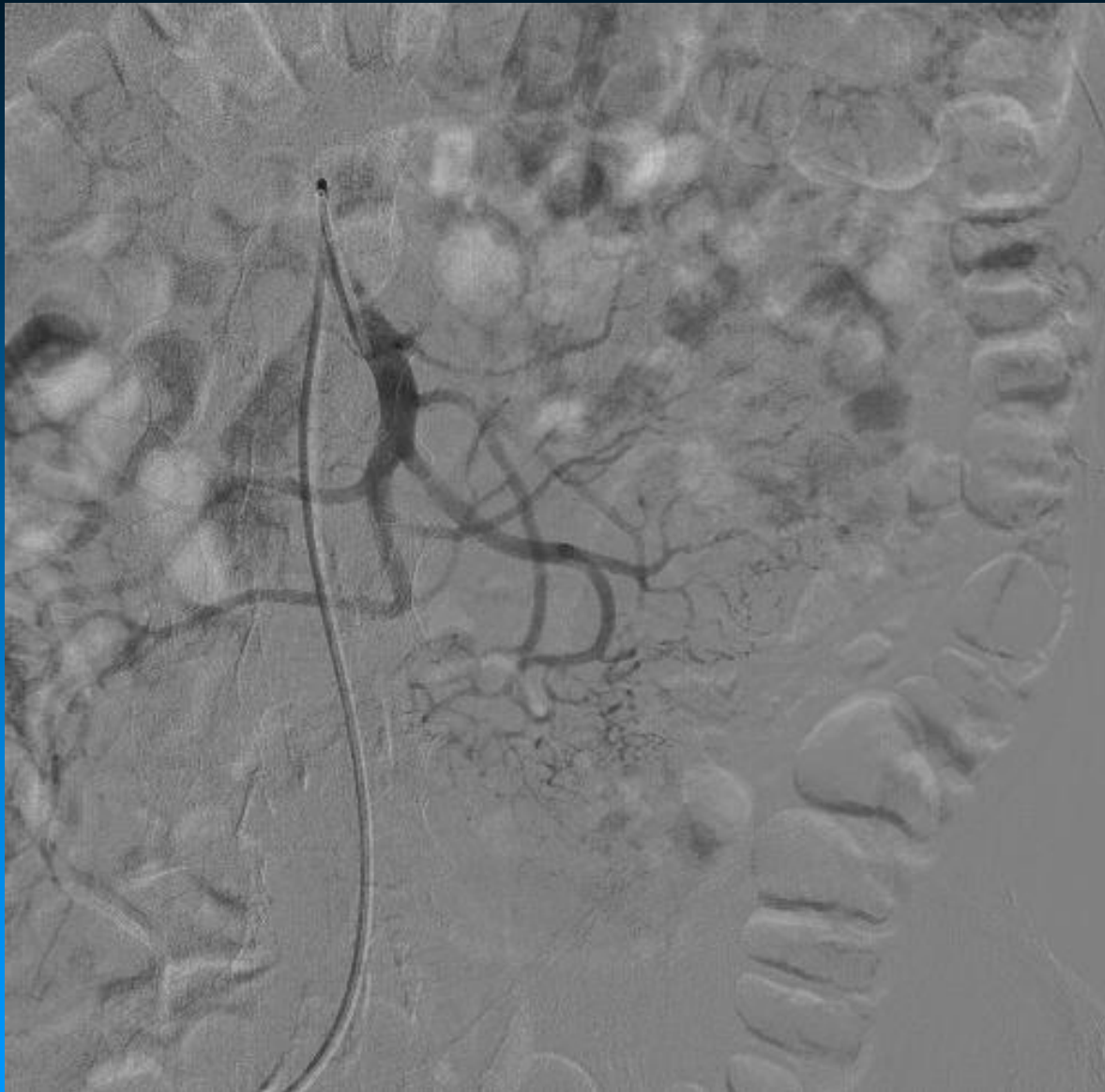- Paciente TJ, masculino, 75 años.
- Motivo de Consulta: Internado en UTI por Hemorragia Digestiva Alta (HDA) de 12 hs de evolución.
- Enf. Actual: Se realizo FEDDA que no evidencia sangrado, se solicito colonoscopia y ante la negativa del gastroenterologo por el sangrado activo, se decidio realizar angiografia mesenterica.

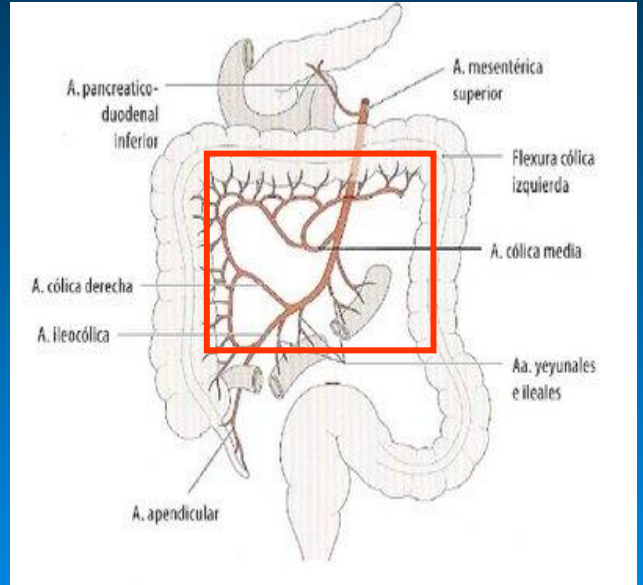
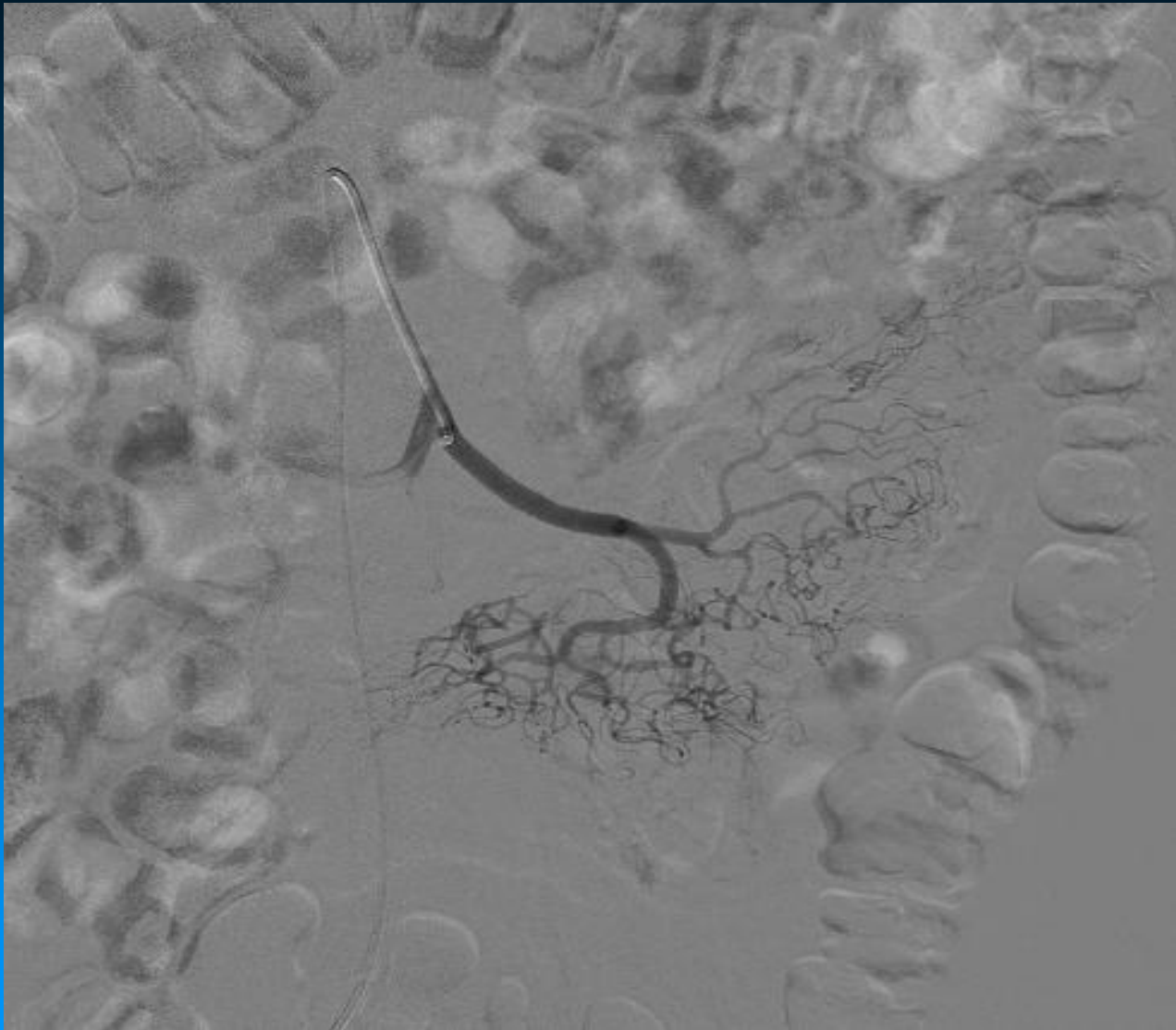
- EF: Lúcido. TA: 110/60 mmHg. FC: 80x'  
Diuresis conservada.

Hipoperfusión con palidez de piel y mucosas.

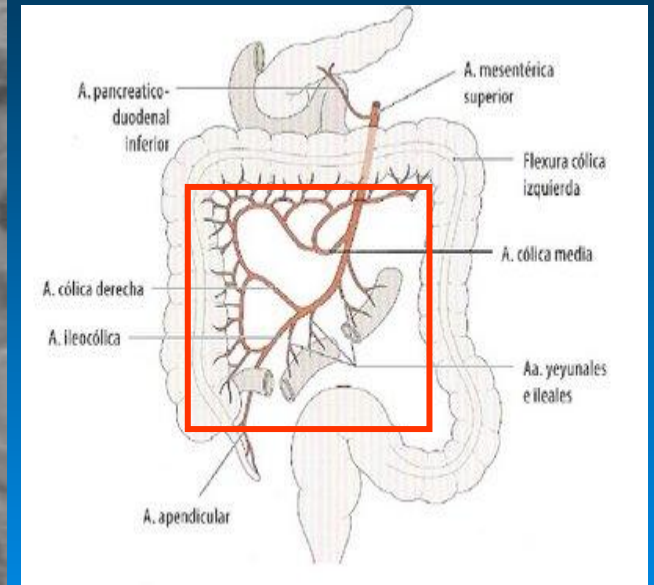
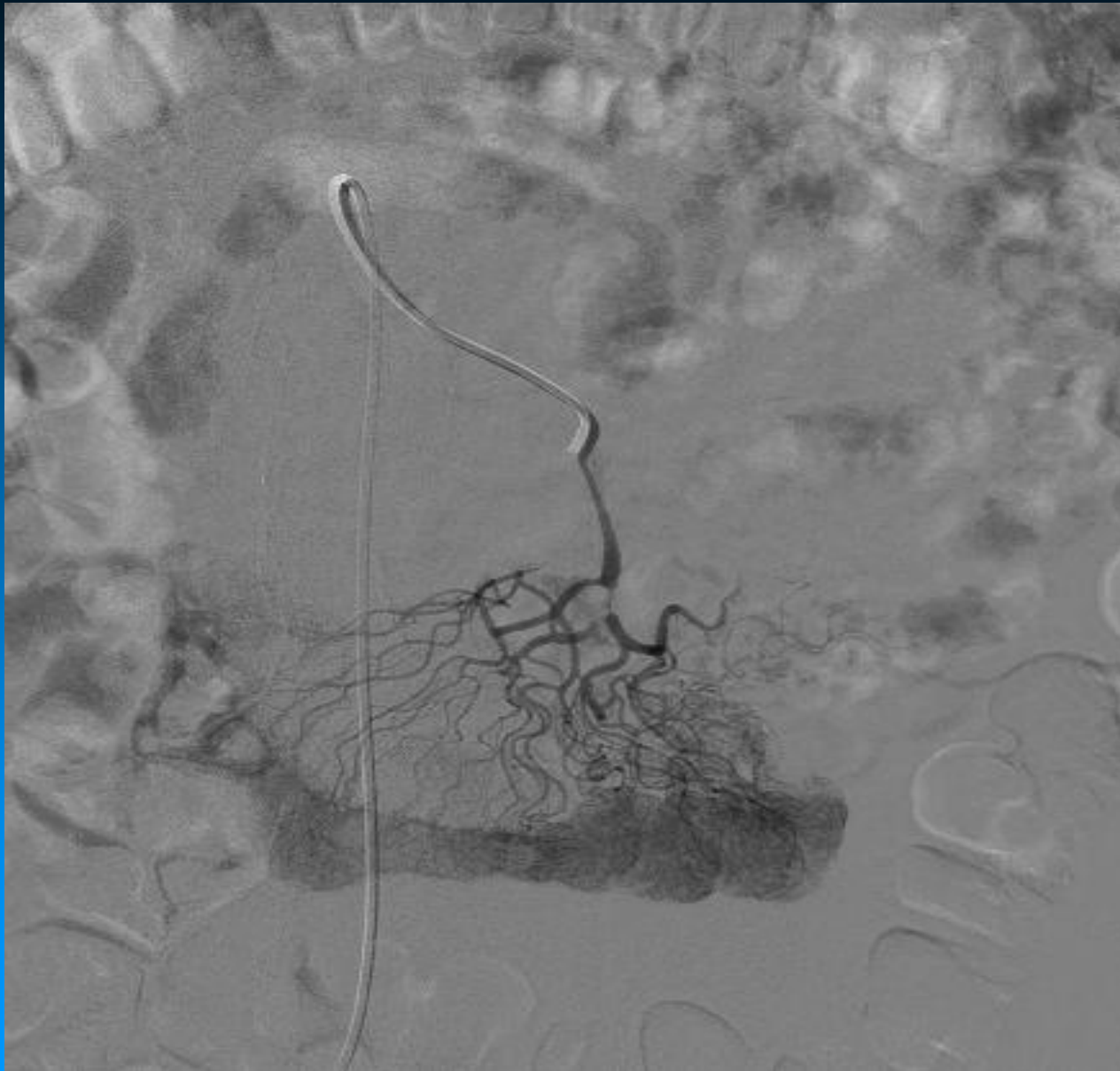Hto. 20 %, luego de recibir 1 UGR.

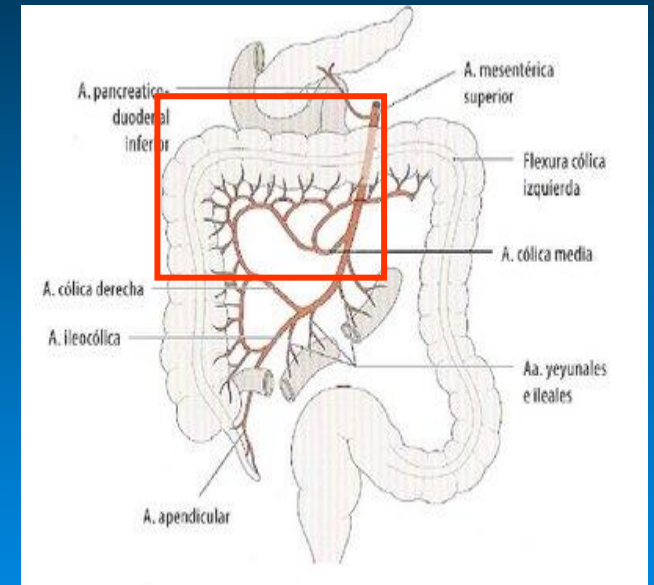
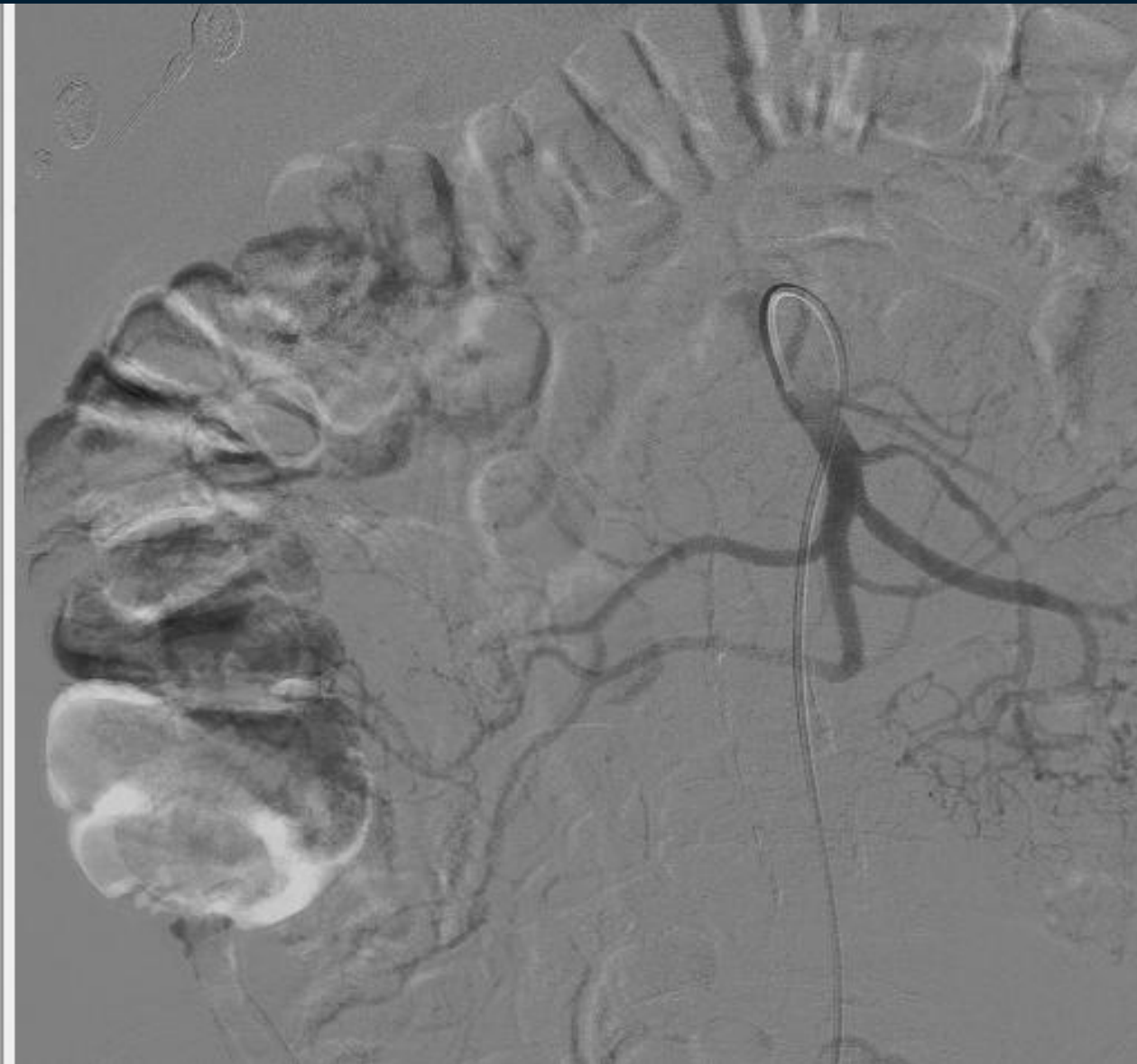



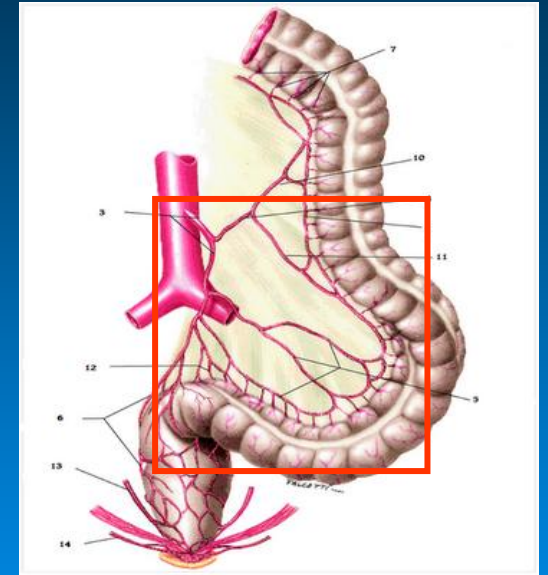

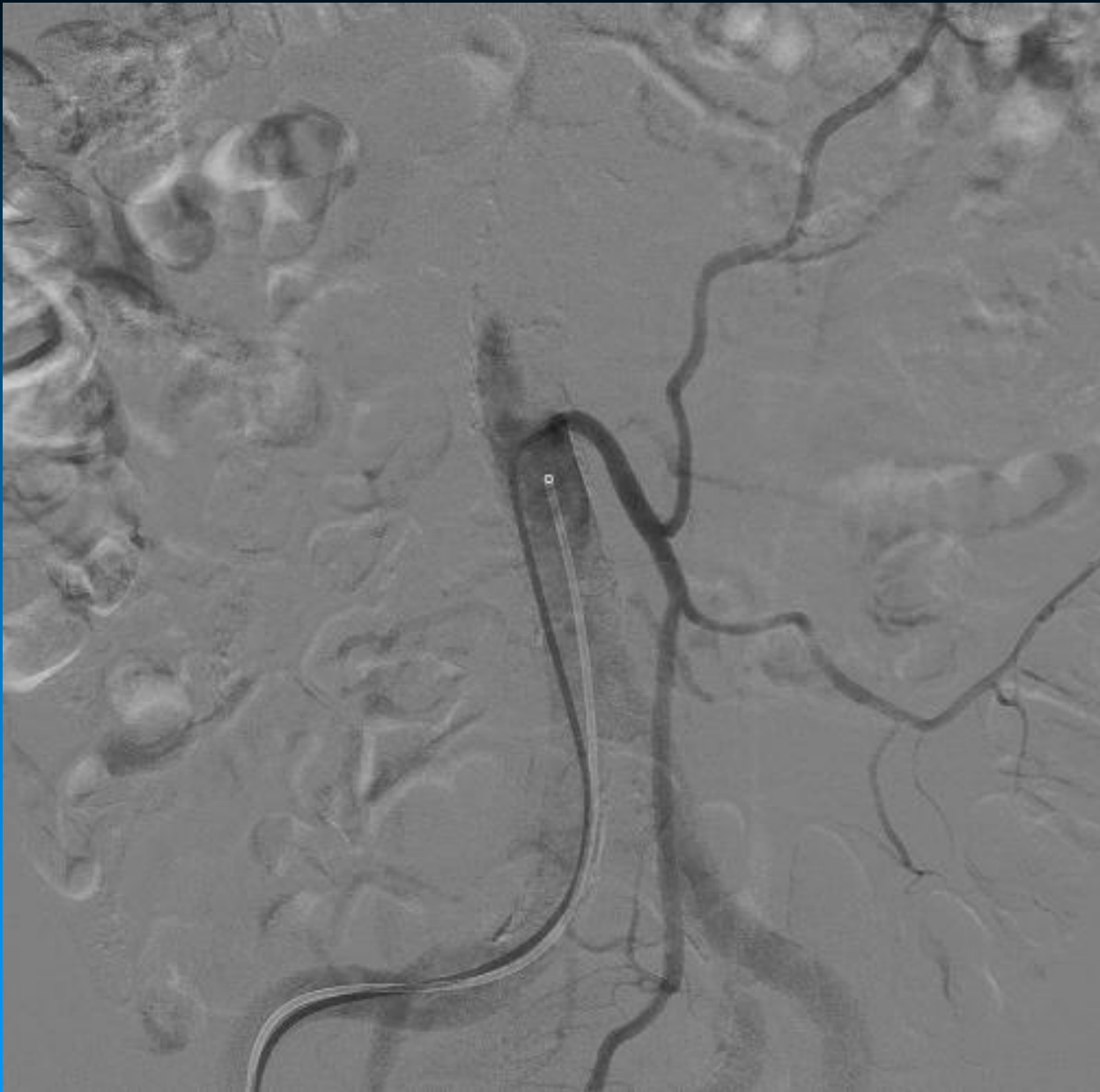
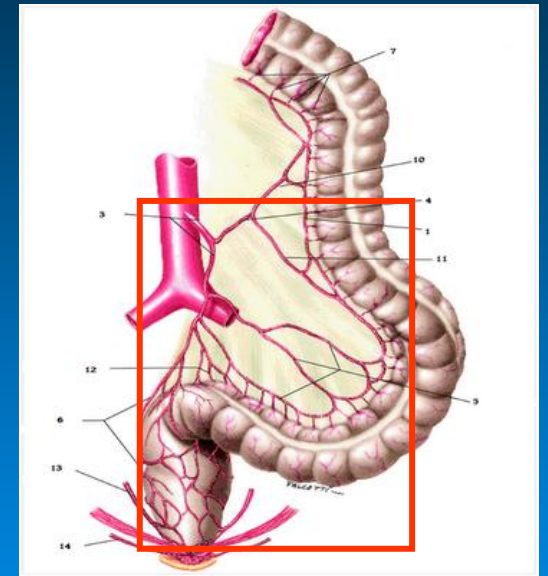
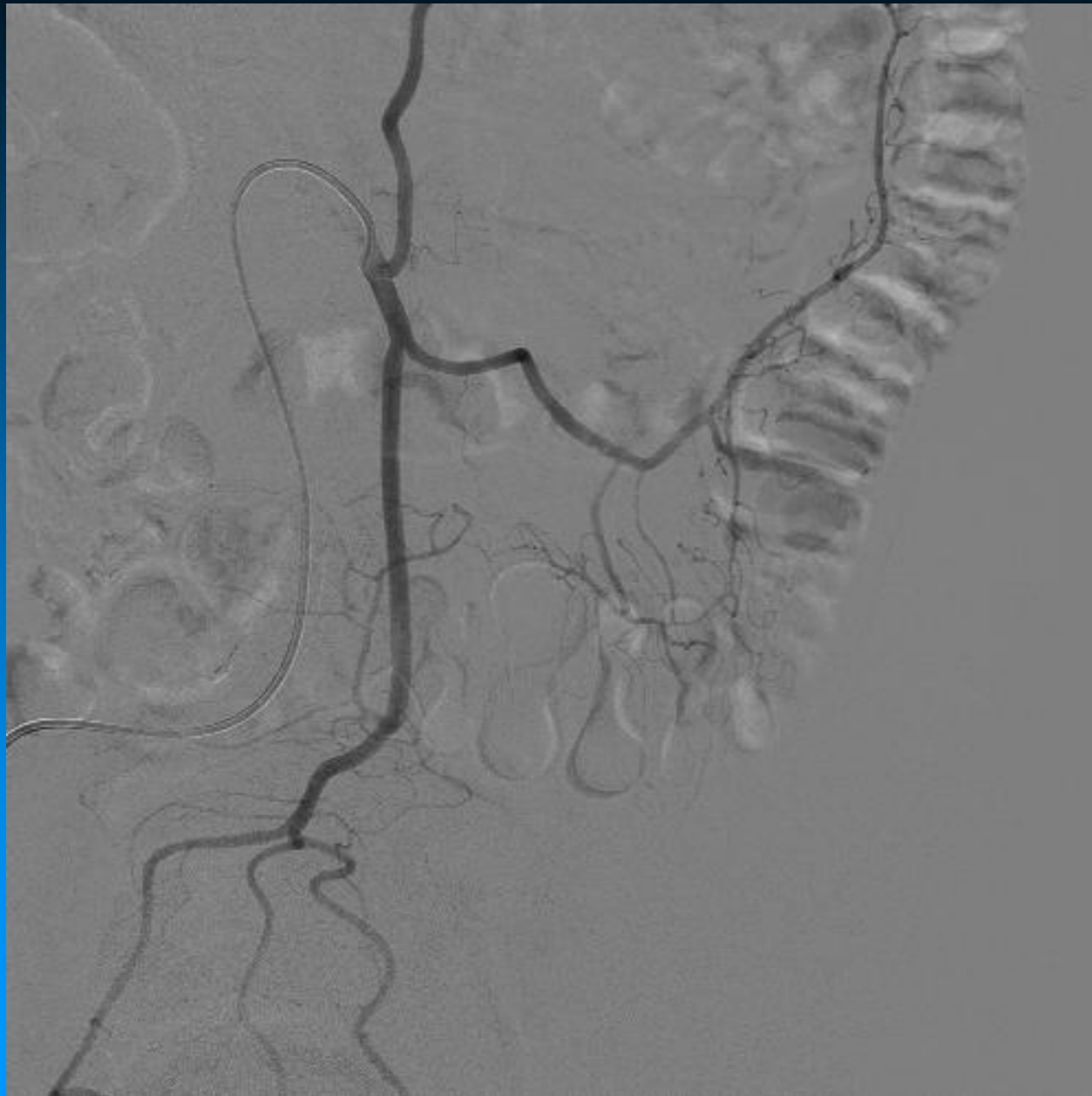




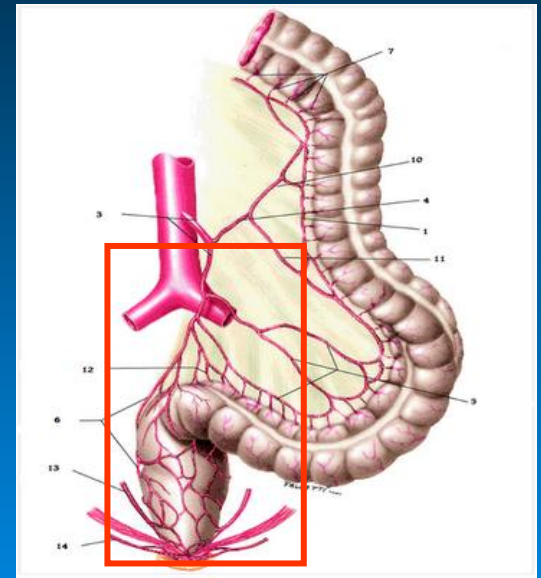


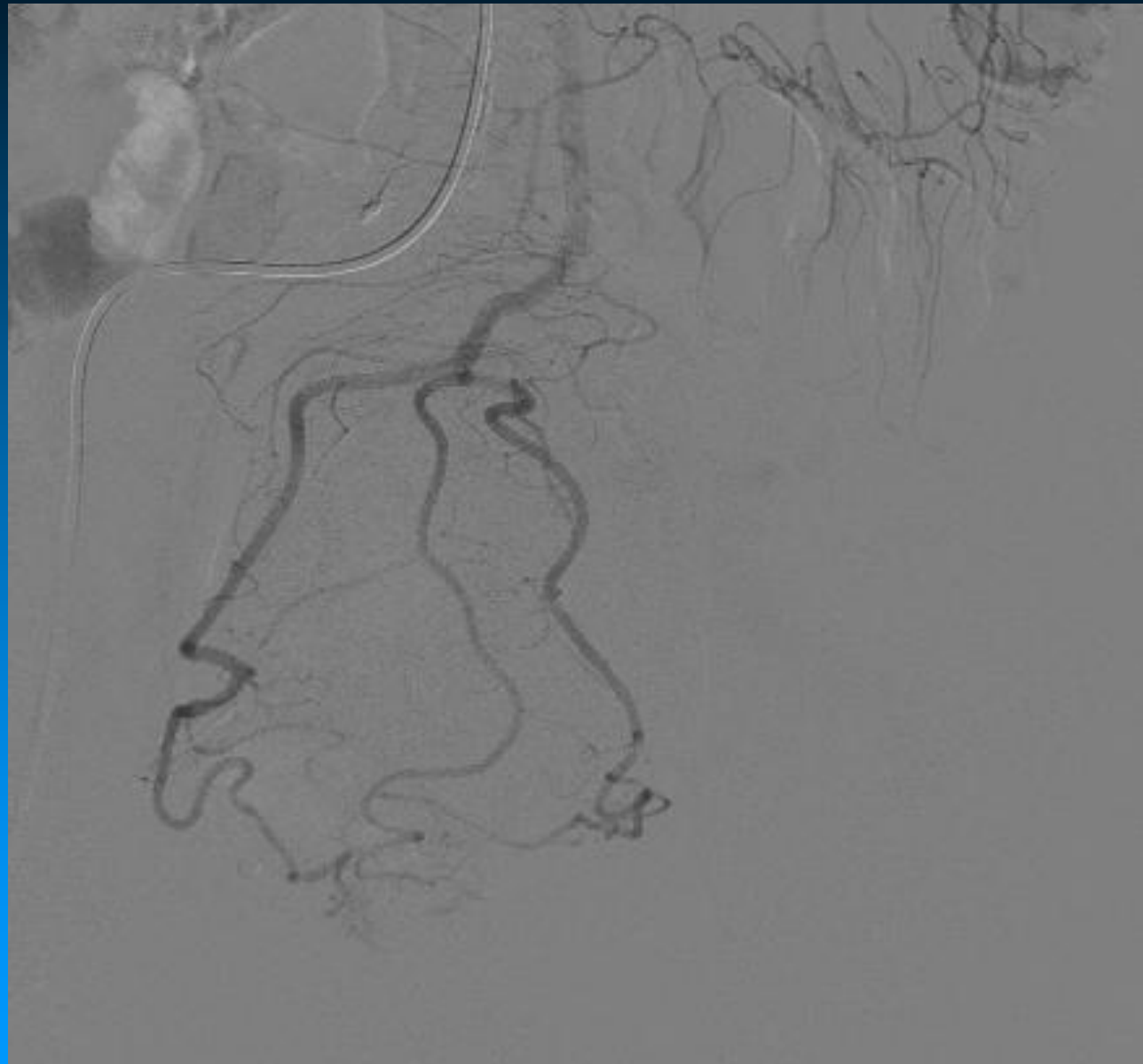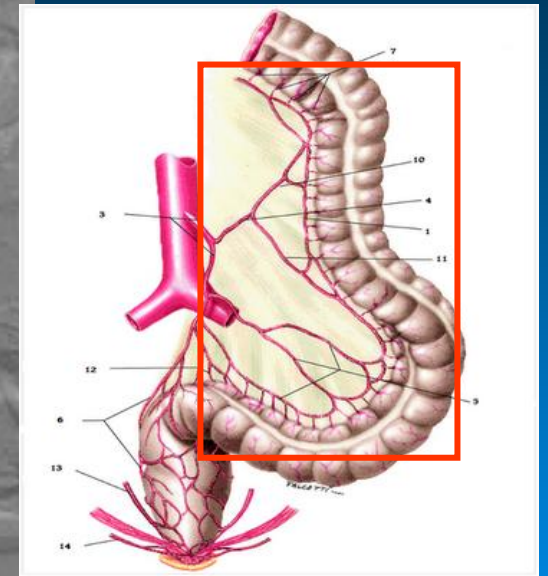
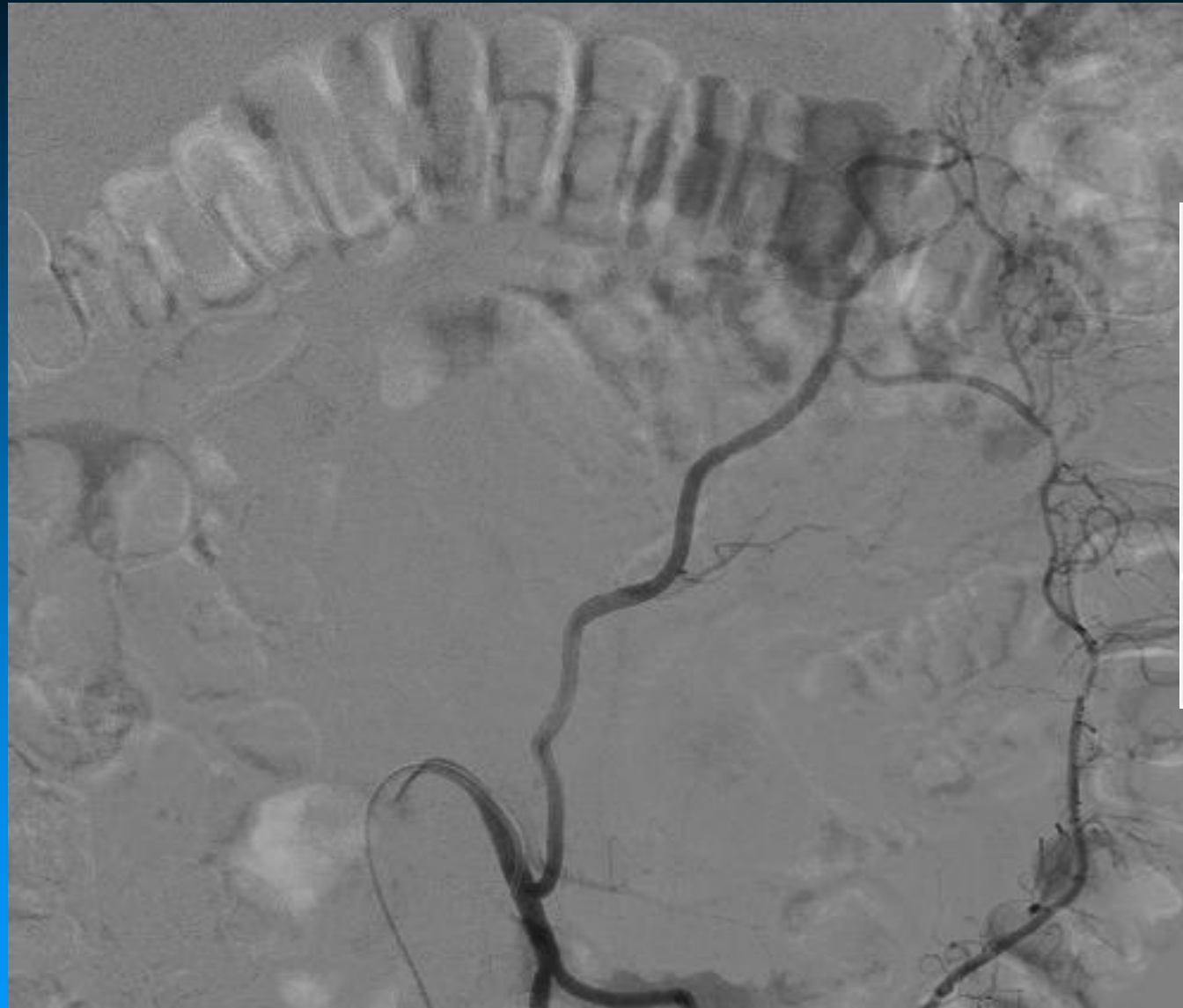






D#10 - /2012





- El paciente es referido a cirugía luego de la cual evoluciona favorablemente y no repite episodio de sangrado.



