

How Did I Treat This Case?

Alejandro Diego Fernández, MD



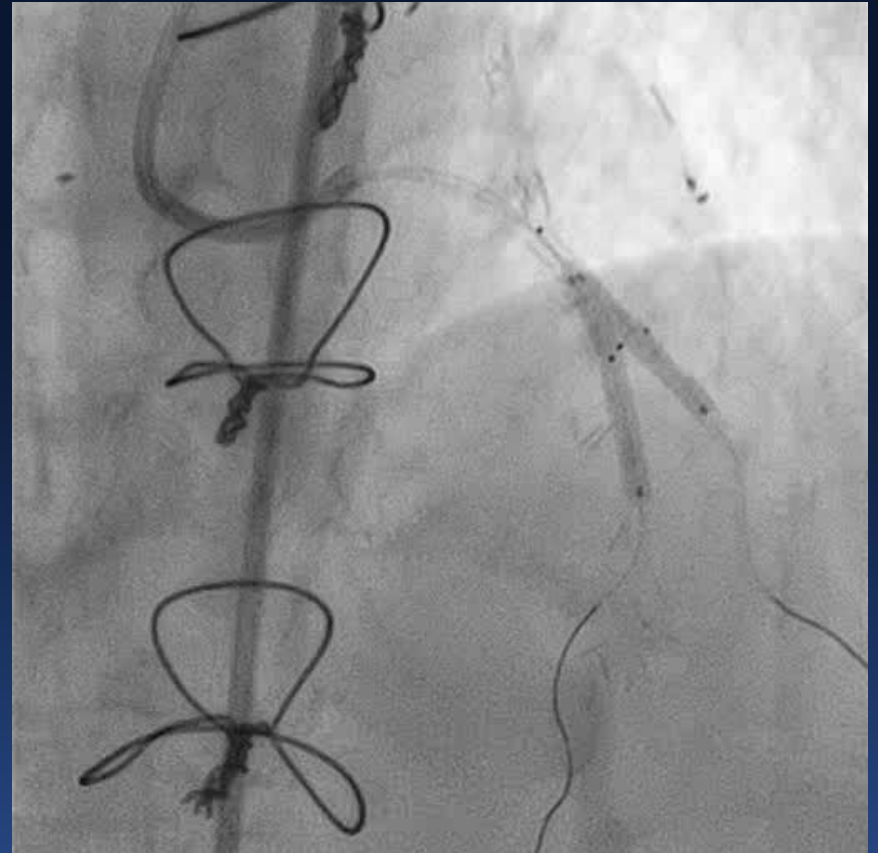
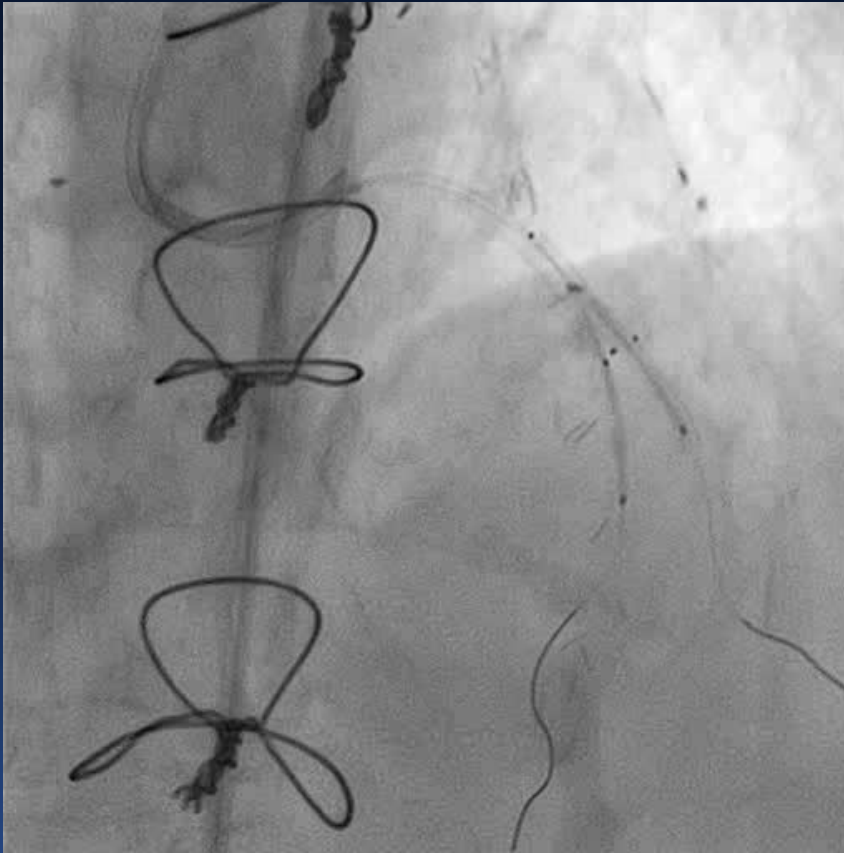HOSPITAL ITALIANO
de Buenos Aires

Disclosure Statement of Financial Interest

I, Alejandro Diego Fernández DO NOT have a financial interest/arrangement or affiliation with one or more organizations that could be perceived as a real or apparent conflict of interest in the context of the subject of this presentation.

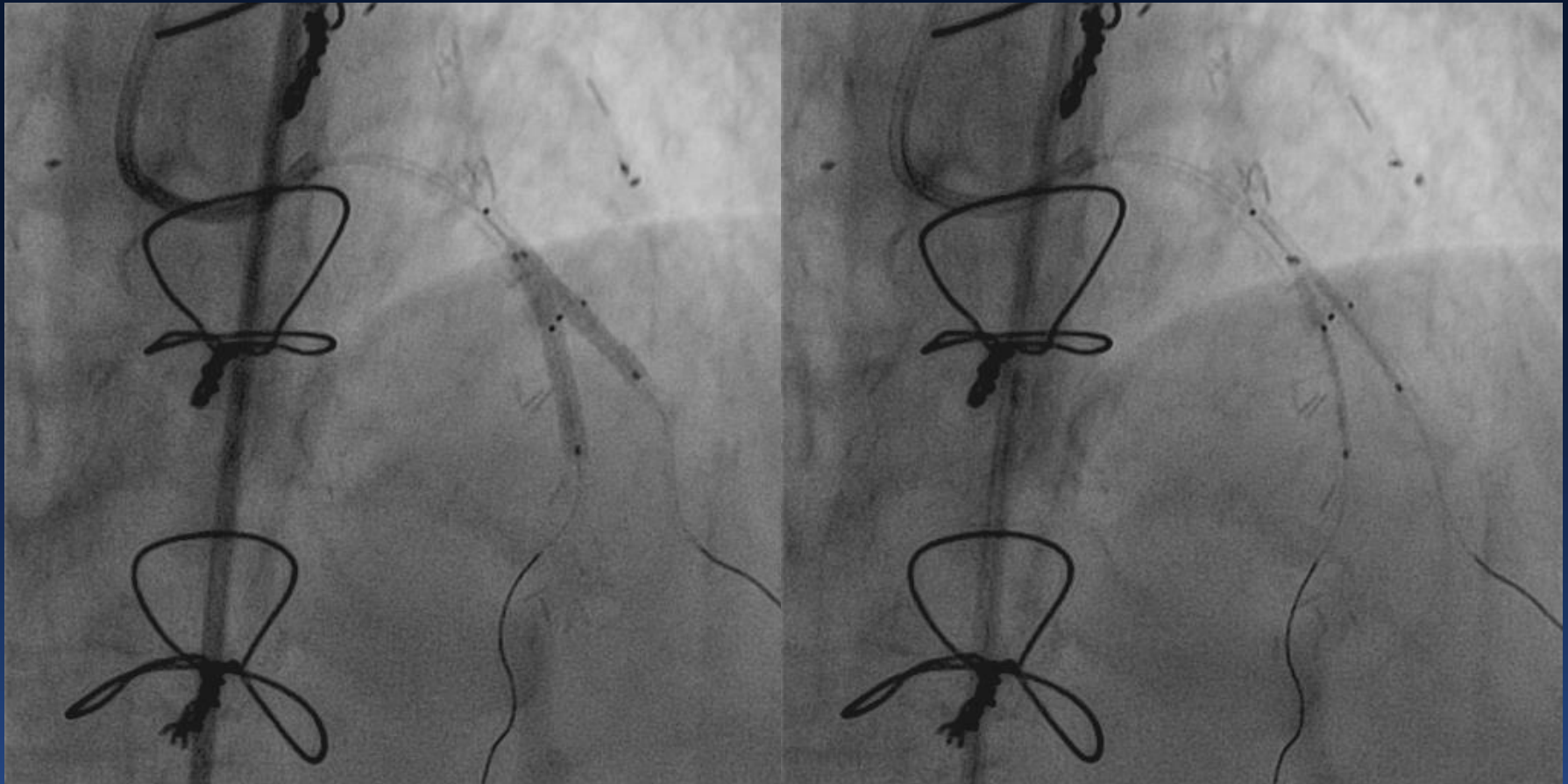
All faculty disclosures are available on the CRF Events App and online at www.crf.org/tct

Case 2



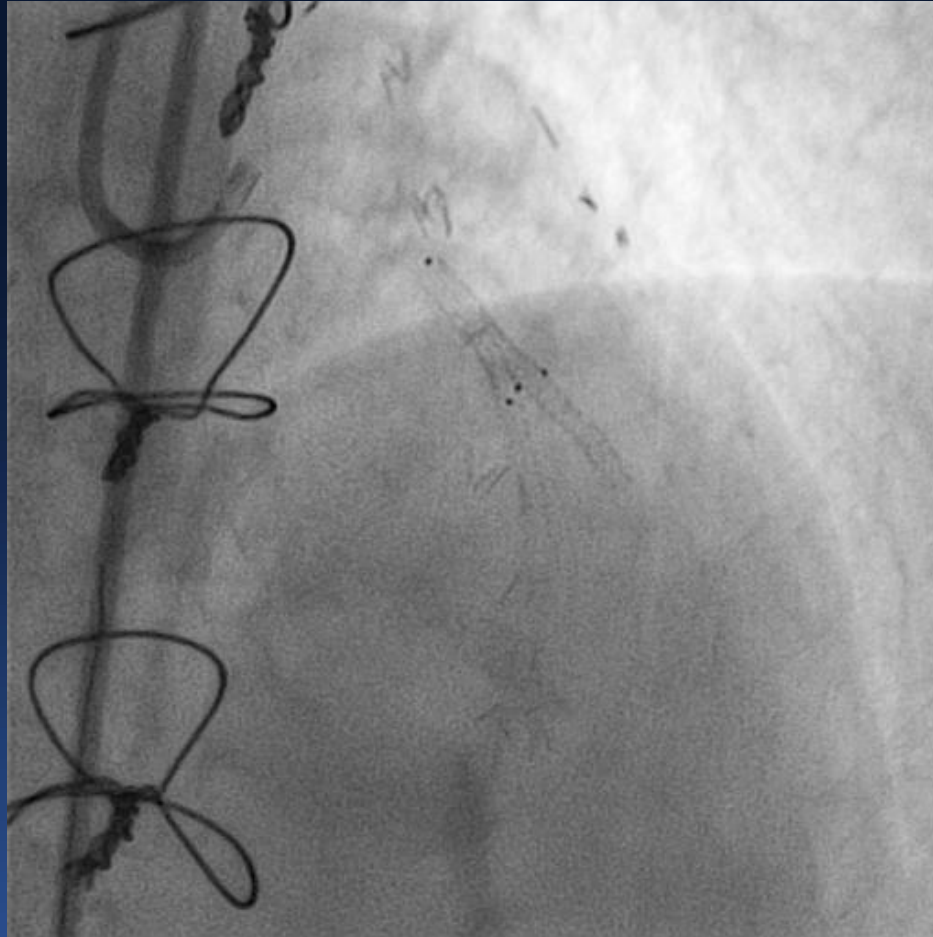
We decided to treat the lesion with a V stent technique by implanting one 2.5X13mm Xience V stent to the diagonal, and one 2.5X18mm stent to the LAD

Case 2



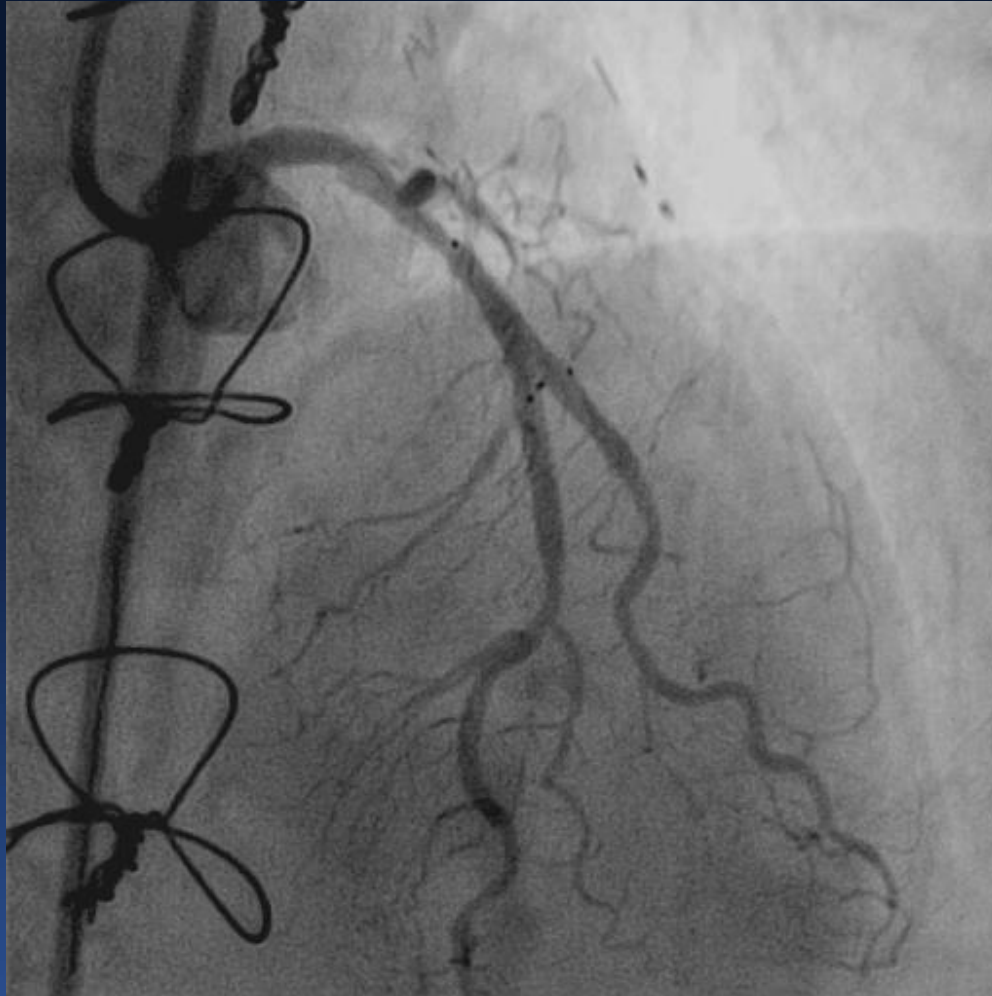
We decided to treat the lesion with a V stent technique by implanting one 2.5X13mm Xience V stent to the diagonal, and one 2.5X18mm stent to the LAD

Case 2



Final Result

Case 2



Final Result